

## Original Research Article

# Role of 256 slice CT scan in pre and postoperative evaluation of congenital cardio-vascular anomalies: our experience at a tertiary care teaching hospital

Sunita Dashottar<sup>1</sup>, Ajay K. Singh<sup>2\*</sup>, K. P. S. Senger<sup>2</sup>, Col J. Debnath<sup>3</sup>

<sup>1</sup>Department of Radio-diagnosis, Command Hospital, Lucknow, Uttar Pradesh, India

<sup>2</sup>Department of Radio-diagnosis, Army Hospital R and R, Delhi, India

<sup>3</sup>Professor Armed Forces Medical College, Pune, Maharashtra, India

**Received:** 15 January 2017

**Accepted:** 25 January 2017

### \*Correspondence:

Dr. Ajay K. Singh,

E-mail: [ltcolaksingh@gmail.com](mailto:ltcolaksingh@gmail.com)

**Copyright:** © the author(s), publisher and licensee Medip Academy. This is an open-access article distributed under the terms of the Creative Commons Attribution Non-Commercial License, which permits unrestricted non-commercial use, distribution, and reproduction in any medium, provided the original work is properly cited.

### ABSTRACT

**Background:** Ultrafast CT (UCT) scan plays an important role in the evaluation of congenital cardiovascular anomalies (CCVA). A major advantage of higher slice multi-detector CT (MDCT), is improved temporal as well as spatial resolution, that helps accurately to delineate complex cardiac and extra-cardiac anomalies with relative ease. Hence this study was aimed to highlight the utility of UCT in the evaluation of congenital cardiovascular anomalies in a large series of patients.

**Methods:** All consecutive patients with suspected CCVA were evaluated by cardiac CT angiography (CCTA) on 256 slice CT scan in a multispecialty tertiary care teaching institute from June 2013 to December 2015.

**Results:** A total of 160 cases of CCVA were evaluated by CCTA. 50 patients had multiple anomalies. A total of 216 anomalies were diagnosed. Tetralogy of fallot (TOF) dominated the list of CCVAs (60, 28%) than the other abnormalities. Of them, 25 patients underwent Blalock Taussig (BT) shunt surgeries, 20 patients underwent total repair operation like Rastelli's operation or augmentation of pulmonary arteries (PAs) while 15 patients were lost to follow up. Most of the patients diagnosed with CCVAs were managed successfully based on the imaging diagnosis of the cardiovascular anomaly.

**Conclusions:** Ultrafast CT scans have immense role in the evaluation of various types of congenital cardiovascular anomalies. It is particularly helpful in the evaluation of extra-cardiac systemic and pulmonary arterial and venous system, postoperative complications, to see the status of shunts, stents and conduits.

**Keywords:** Congenital cardiovascular anomalies, Cardiac CT angiography, Ultrafast CT scan

### INTRODUCTION

Incidence of congenital heart disease is 6-8 per 1000 of live births. Survival of the patients with CHD have improved over a period of time due to early diagnosis by the various imaging modalities like echo, CCTA (coronary computed tomography angiography), cardiac magnetic resonance imaging (CMRI) and coronary angiogram (CA).<sup>1</sup>

Management of congenital cardio-vascular anomalies (CCVA) primarily depends upon the diagnosis at any stage of patient care; therefore, the assessment should involve the various imaging modalities and should be considered as complimentary to each other.<sup>2</sup>

Echo is the initial imaging modality of choice for the diagnosis of most of the CCVA as it is widely available, cheap, non-invasive and provides immediate high

resolution anatomic and physiological information.<sup>3</sup> However, due to its limited acoustic access, echo is not sufficient for the evaluation of extra-cardiac vascular structures.<sup>4</sup>

CA is primarily used to provide hemodynamic information and for the evaluation of the extra-cardiac vascular structures.<sup>5</sup> CA has limitations due to its 2D nature, overlapping of adjacent cardiovascular structures and simultaneous evaluation of the systemic and pulmonary vasculature. The disadvantages of CA over CCTA are higher catheter related complications, larger volume of contrast, longer duration of sedation and higher radiation dose.<sup>6-8</sup> Because of these limitations of echo and CA, CTCA and MRI are considered to be alternative, complementary as well as problem solving diagnostic tools for the evaluation of CCVA.<sup>9</sup>

CMRI can accurately give anatomical and physiological information which cannot be provided by the echo and CA alone.<sup>10</sup> CMRI can provide functional information and evaluation of the myocardial functions.<sup>11</sup> But the greatest challenge of CMRI is motion artifacts from cardiac and respiratory movements. In infants and pediatric patients. Various other disadvantages are its higher cost, limited availability, general anesthesia for longer duration and image degrading artifacts due to implanted stents and coils.<sup>12,13</sup>

The utmost challenge in imaging the beating heart has been the main motivating force for the innovation of ultrafast CT scanners. The latest ultrafast CT scanners have significantly improved the diagnostic capabilities of CCTA due to its high gantry speed, improved spatial and temporal resolution and has been found to correlate well with conventional CA. Ultrafast CTCA can acquire volume acquisition of the entire heart and the coronary arterial tree within 3-4 seconds with higher temporal and spatial resolution than MRI.<sup>14</sup> 256 and 320 Slices CT scanner have brought a revolution in cardiac imaging where the heart can be scanned in one tube rotation or one heart beat and total scanning time is 3-4 seconds. The reconstructed images like MIP and 3D-VR images are of great help for the pre-operative planning and post-operative evaluation of the complications, status of stent, shunts and conduits. Tachycardia and arrhythmias are the main limiting factors with these CT scanners. However, these limiting factors have partially been overcome by the dual source CT (DSCT) scanners. Somatom definition flash (Siemens) is a latest ultrafast CT scanner where the entire heart can be scanned in a fraction of heart beat and total scanning time is 0.25 to 0.27sec.

CCTA can be considered as first imaging modality for certain conditions like – evaluation of the MAPCAS, vascular rings and in patients with pacemaker or metallic implants.<sup>12</sup> The present study was conducted to accentuate the utility of UCT in the evaluation of congenital cardiovascular anomalies in a large series of patients.

## METHODS

This prospective cross sectional observational study was carried out at a tertiary care cardiovascular centre of Armed Forces Medical Services from June 2013 to December 2015. A total of 160 patients of various types of CCVA referred to the radiology department for CCTA during the study period were included in the study.

All the neonates and pediatric patients with suspected CCVA were initially evaluated by echocardiography (echo) in the cardiology department. Patients who were detected to have CCVA on echo were further evaluated by CCTA. Catheter angiography was done for further evaluation in a select group of cases where CCTA evaluation was deemed equivocal.

### Cardiac CT angiography

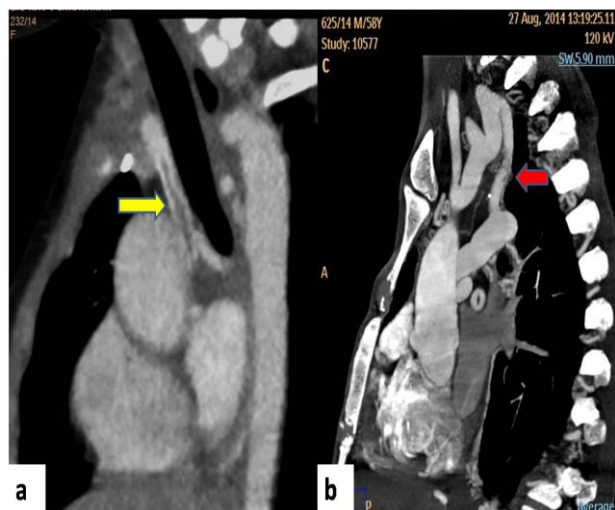
CCTA were done on 256 slice CT scanner (Philips Healthcare, Brilliance). Young pediatric patients were given mild sedation while older children were responded to verbal assurance. In the pediatric patients 1 to 1.5 ml/kg of low (300 mg I/ml) or iso-osmolar contrast (320 mg I/ml) was injected through the antecubital vein at a rate of 1.5 to 2.5 ml/sec followed by 20-30 ml saline bolus chase. The tube voltage varied from 80 to 100kVp and tube current varied according to the weight of the patient. Mean scanning time was 02-03 sec. After completion of the scan, images were reconstructed in various orthogonal as well as non-orthogonal planes including three-dimensional volume-rendered (3D-VR) images, two dimensional (2D) maximum intensity projection (MIP). All images were analyzed at the workstation by two radiologists trained in MDCT and cardiac imaging. CCTA findings of all patients were tabulated and analyzed later.

## RESULTS

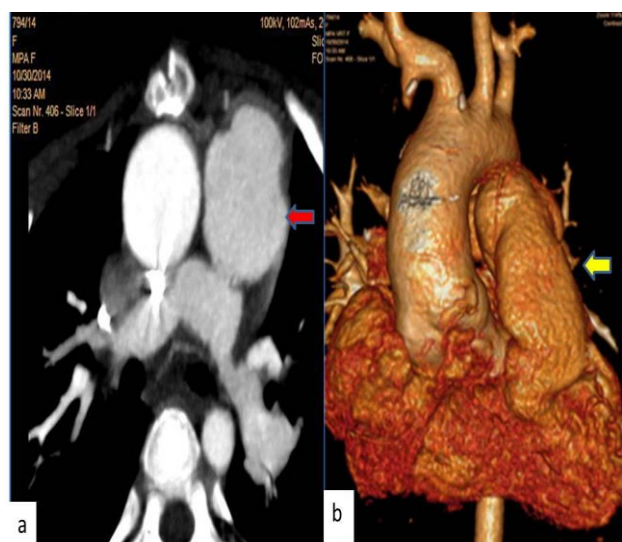
A total of 160 patients of various types of CCVA underwent CCTA during the study period. Total number of CCVA detected on CCTA was 216 as 50 patients had multiple anomalies. A total of 21 different types of CCVA were found in our study as presented in Table 1 and depicted in figures from Figure 1 to Figure 15 along with their managements. Tetralogy of fallot (TOF) dominated the list of CCVA (60, 28%), followed by anomalies of pulmonary arteries (40, 18.5%), anomalous pulmonary venous drainage (30, 14%), coarctation of aorta (25, 11.5%), coronary anomalies (10, 5%) and venacaval anomalies (5%). All other anomalies were individually less than 5% of the total CCVA. Majority of the patients were managed in our institution except those who were lost to follow up.

Out of sixty cases of TOF, twenty-five patients underwent Blalock Taussig (BT) shunt surgeries, twenty patients underwent total repair operation like Rastelli's operation or augmentation of pulmonary arteries (PAs)

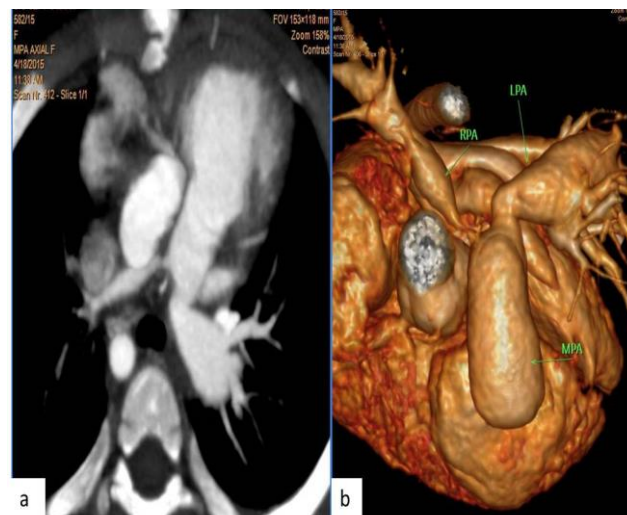
while fifteen patients were lost to follow up as given in Table 2. Out of twenty-five patients who underwent minor surgeries, one patient died in early postoperative period, nine patients were lost to follow up, four patients developed blockage of BT shunt after one year, while eleven patients had patent shunt.



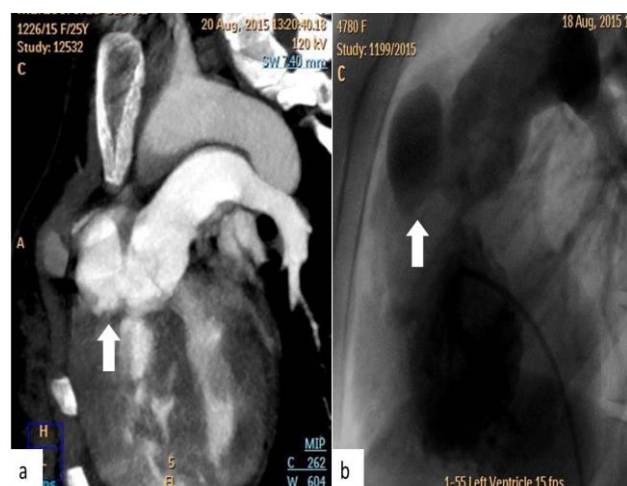
**Figure 1:** Case of tetralogy of Fallot (TOF) with Ballock Taussing (BT) Shunt. a) sagittal reformatted image shows non-opacification of BT shunt except the upper portion suggestive of non-patent BT shunt; b) coronal oblique reformatted image of a 58 yrs male case of TOF with BT shunt shows patent BT shunt between left subclavian artery (LSCA) and left pulmonary artery (LPA).



**Figure 2:** Operated case of TOF with right ventricle-pulmonary artery (RV-PA) Conduit (Rastelli operation). a) axial 2D maximum intensity projection (MIP) image shows stenosis of the mid portion of RV-PA conduit (red arrow) with mild stenosis at the LPA origin b) 3D Volume rendered (VR) image showing the RV-PA conduit (yellow arrow).



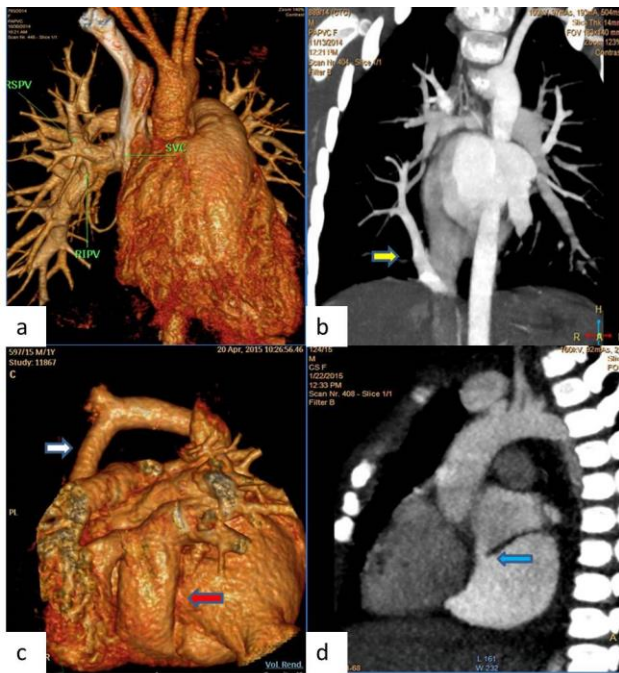
**Figure 3:** Operated case of TOF with augmentation of pulmonary arteries (Pas). a) axial 2D MIP image shows severe stenosis at the right PA (RPA) origin with small calibre RPA and mild stenosis at the LPA origin b) Volume rendered (VR) 3D image shows the same.



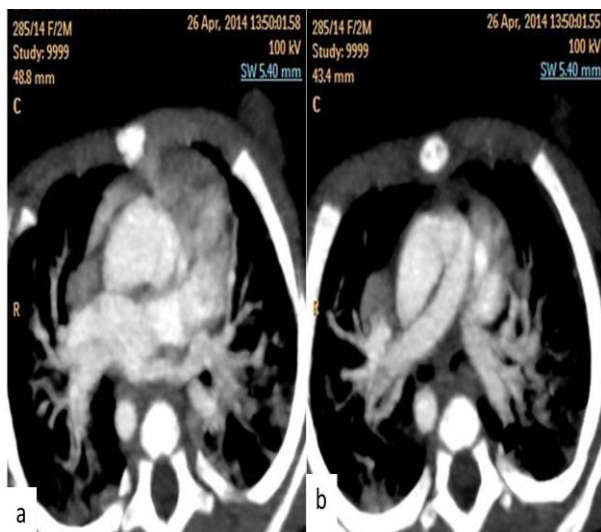
**Figure 4:** Case of right ventricular outflow tract stenosis, associated saccular aneurysm of the infundibular region. a) 2-D MIP coronal oblique image shows stenosis of RVOT with saccular aneurysm (white arrow) arising from the origin of MPA b) Catheter angiography showing the same.

Out of twenty patients who underwent total repair, six patients died during the operation or in early postoperative period due to various complications, three patients developed stenosis of the right ventricle-pulmonary artery (RV-PA) conduits, one had stenosis of augmented PAs as seen in Figure 3a and 3b while five patients were lost to follow-up. Out of four patients who developed stenosis in the conduits/augmented PA, three patients improved with balloon angioplasty while one patient underwent redo surgery.

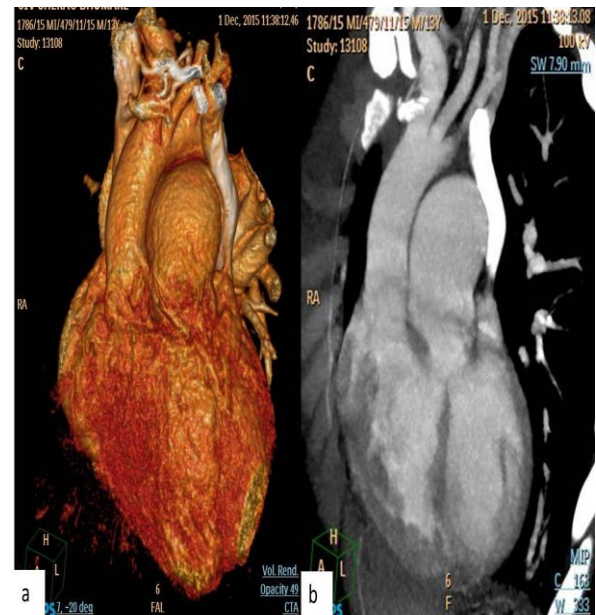




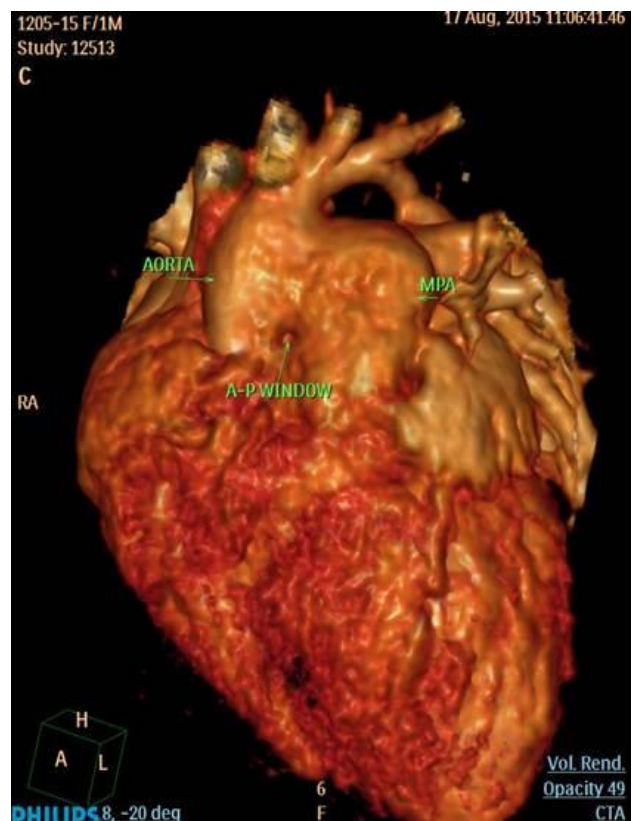
**Figure 5: Cases of partial/total anomalous pulmonary venous return (PAPVC/TAPVC).** a) 3D VR image of supra-cardiac PAPVR showing right pulmonary veins draining into SVC b) 2D coronal MIP image of infra-cardiac PAPVR showing RIPV draining into IVC (inverted sword sign), c) 3D VR image of a supra-cardiac & cardiac type of TAPVR showing LSPV draining into LSCV (white arrow) and all other PVs forming common trunk and draining through coronary sinus into RA (red arrow) d) operated case of cardiac type of TAPVR developed stenosis at the site of opening of common trunk into LA.



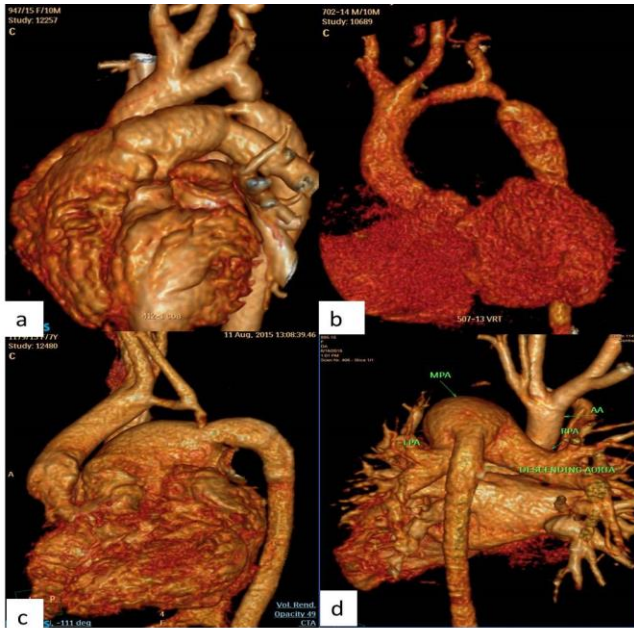
**Figure 6: Axial reformatted images of truncus arteriosus.** a) single trunk arising from LV b) MPA arising from the single trunk and then branching into two pulmonary arteries.



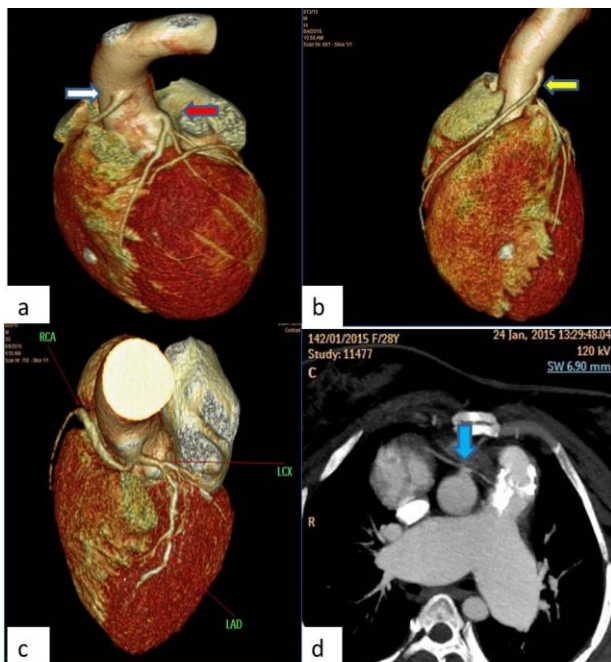
**Figure 7: Case of VSD with transposition of great arteries (TGA).** a) VR image is showing aorta arising from the RV and MPA from the LV with over-riding of MPA seen b) MIP coronal image showing the same. Left superior vena cava (LSVC) is also seen.



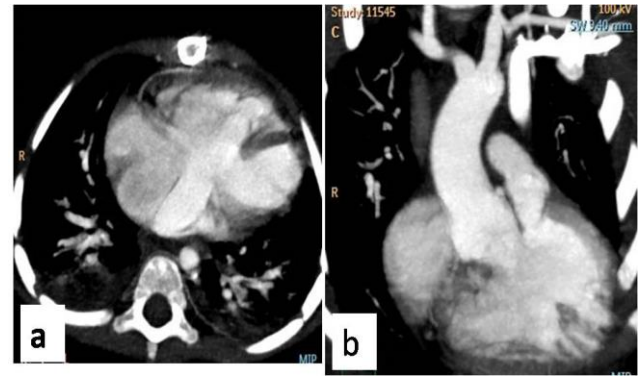
**Figure 8: Case of Aorto-pulmonary (A-P) window - 3D VR image is showing wide communication between the ascending aorta and MPA distal to the origin.**



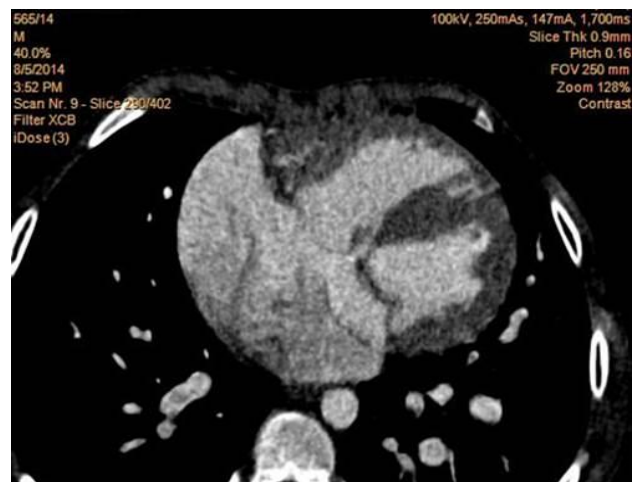**Figure 9: 3D VR image of coarctation of aorta. a) showing preductal type of coarctation b) coarctation with hypoplastic arch c) interrupted hypoplastic arch d) absent arch of aorta with dilated PDA supplying the descending thoracic aorta (DTA). Major arch vessels are arising from the ascending aorta (AA).**



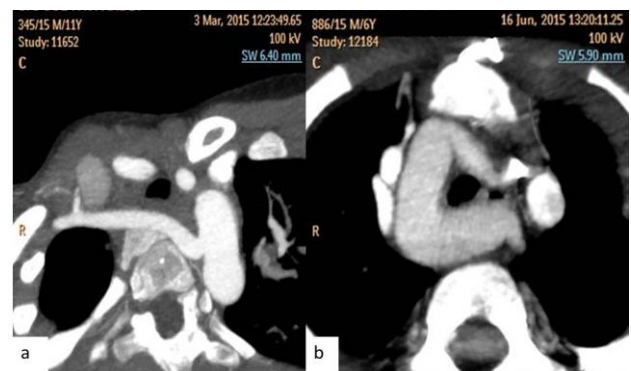**Figure 10: Anomalous origin of coronary arteries. a) & b) volume rendered images showing anomalous origin of RCA (right coronary artery) from the proximal ascending aorta above the left coronary cusp c) common origin of RCA & left coronary artery (LCA) from left coronary sinus d) anomalous origin of left anterior descending (LAD) artery from proximal portion of RCA.**



**Figure 11: Case of atrio-ventricular canal defect (AVCD) with double outlet right ventricle (DORV). a) 2-D axial MIP image showing large ASD & VSD with common opening of both atria with both the ventricles b) 2-D coronal MIP image showing Aorta & MPA arising from right ventricle.**

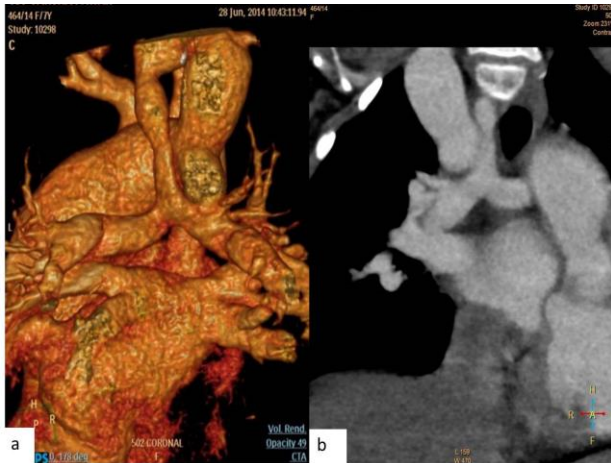


**Figure 12: Axial image of cortriatrium shows single atrium with multiple floating membranes in the left atrial chamber.**

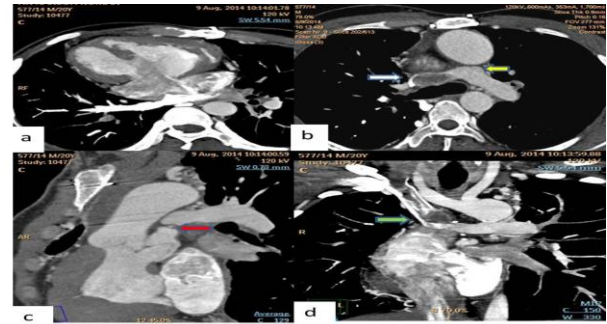


**Figure 13: Vascular rings. a) 2-D axial MIP image showing aberrant right subclavian artery compressing esophagus b) 2-D axial MIP image showing aberrant left subclavian artery with Kommeral's diverticula and right sided aortic arch are forming vascular ring around trachea.**





**Figure 14: Case of anomalous origin of pulmonary trunk from right subclavian artery (RSCA) in a case of TOF. a) Volume rendered image showing the origin of pulmonary trunk from the dilated right subclavian artery. MPA is coursing downwards and branching into two Pas supplying both the lungs b) MIP coronal oblique image showing the same.**



**Figure 15: An operated case of dextrocardia with single atrium & large ventricular septal defect (VSD) with double outlet left ventricle (DOLV) and Glenn shunt. a) axial image is showing single atrium and large VSD b) axial image showing resected MPA near its origin (yellow arrow) with normally opacified MPA & LPA and non opacified RPA (white arrow) c) coronal oblique 2D MIP showing aorta & MPA arising from LV with MPA resected near its origin (red arrow) d) Coronal 2D MIP image showing peripherally opacified SVC anastomosed to RPA (Green arrow - Glenn shunt).**

**Table 1: Types of congenital cardiovascular anomalies in the study participants.**

Types of congenital cardiovascular anomalies	Total no of CCVA detected by CCTA: 216
Tetralogy of Fallot	60 (28%)
Anomalies of pulmonary arteries	40 (18.5%)
Anomalous pulmonary venous drainage	30 (14%)
Anomalies of pulmonary veins	5 (2%)
Truncus arteriosus	4 (2%)
Transposition of great arteries	4 (2%)
A-P Window	4 (2%)
Coarctation of aorta	25 (11.5%)
Congenital aneurysm of aorta	4 (2%)
Coronary anomalies	10 (5%)
Single ventricle	2 (1%)
Single atrium	4 (2%)
AVCD	2 (1%)
Double outlet right ventricle	4 (2%)
Double outlet left ventricle	2 (1%)
Cortriatriatum	1 (<1%)
Pulmonary agenesis	1 (<1%)
Hypogenetic lung	2 (1%)
Sequestered Lung	1 (<1%)
Vascular ring	3 (1%)
Vena Cava anomaly	10 (5%)

**Table 2: Type of surgery in TOF cases and their complications.**

Type of surgery in TOF	Total no of cases	No complications	Mortality	Complications	Lost to follow
BT Shunt surgery	25	11	01	04 (Blockage of shunt after 01year)	09
Major surgery	20	05	06	04 (stenosis of conduit)	05
Lost to follow up	15			-	

## DISCUSSION

Ultrafast CT (UCT) scan plays an important role in the evaluation of congenital cardiovascular anomalies (CCVA), particularly the extra-cardiac vascular anomalies. UCT enables accurate delineation of complex anatomy of cardiovascular system both before and after surgery especially in pediatric patients.<sup>9,15</sup> Cardiac CT angiography (CCTA) is the modality of choice for evaluation of postoperative complications and also to evaluate the status of conduits, shunts and stents.

In the present study, tetralogy of Fallot, is the commonest congenital cardiac anomaly which was evaluated by CCTA in our department. In TOF due to pulmonary atresia or pulmonary stenosis, the blood supply to the lungs comes from the various collaterals arising from the aorta and/or other systemic arteries known as major aortopulmonary collateral arteries (MAPCAS).<sup>15</sup> This is easily diagnosed by CCTA as it can demonstrate the caliber and number of the mapcas. Hence, it is the modality of choice for the evaluation of mapcas before embolization or reimplantation.<sup>12,15-17</sup> CT is also very useful for pre and post-operative evaluation of PAPVR/TAPVR.<sup>4,13,18</sup>

In this study, we had a case of Down syndrome (DS) with TOF in which augmentation of MPA was done; two years later developed severe stenosis of right pulmonary artery (RPA) and mild stenosis of left pulmonary artery (LPA) as shown in Figure 3. This condition was improved with balloon angioplasty.

CTA can accurately delineate the presence, patency and caliber of pulmonary arteries which is required for correct surgical planning and it also helps in the pre and postoperative evaluation of pulmonary artery stenosis or dilatation.<sup>16,19</sup> In this study, we observed an interesting case of 2 cm size saccular aneurysm of the infundibular region associated with right ventricular out flow tract obstruction (RVOTO) and large ASD which was initially missed on CT angiography. However, catheter angiography clearly demonstrated the saccular aneurysm and retrospectively was demonstrated on CT angiography as shown in Figure 4 and then the patient was operated thereafter.

In the study, a case report of 1 year old baby with large ASD associated with aneurysmal dilatation of main pulmonary trunk (MPA) compressing the left main bronchus against the descending thoracic aorta (DTA) leading to complete collapse of the left lung was observed and this was corrected by operation with complete regression of the extrinsic compression over the left main bronchus.<sup>20</sup>

CCTA can accurately diagnose the arch hypoplasia, interrupted or absent arch and coarctation of aorta. It can accurately give the measurements of the aorta as well as demonstrate the PDA and arterial collaterals in COA.<sup>21</sup> It can accurately depict the site and degree of stenosis<sup>6</sup>,

classify the types and can help in surgical planning of interrupted arch or COA.<sup>17,22</sup> It can also demonstrate the various complications like residual/re-coarctation or pseudo-coarctation formation and is also very useful in the evaluation of stent patency and various complications like stent migration or occlusion/stenosis.<sup>15,23</sup>

In this study, we had two known cases of Marfan's syndrome associated with huge aneurysm of the aortic root and AA. Bentall surgery was done replacing the aortic root along with the valves with artificial conduit and the coronary arteries (CAs) were re-anastomosed to the conduit.

In this study, we had an interesting case of two-year-old male baby, known case of DS with situs inversus and dextrocardia had single atrium with physiological single ventricle due to large VSD as depicted in Figure 15a. Aorta and MPA both were arising from the LV suggestive of DOLV as seen in Figure 15c. Due to this high pressure blood was flowing into the pulmonary circulation leading to pulmonary congestion. To reduce the pulmonary congestion, the MPA was resected near its origin and was permanently closed (Fig 15bandc). Then the superior vena cava (SVC) was anastomosed to the RPA so as to divert one third of the systemic blood into the pulmonary circulation to maintain the oxygenation as in Figure 15d. This is known as Glenn shunt which is usually done in single ventricle.

ECG-gated CTA can accurately delineate the origin and course as well as the various anomalies of the CAs.<sup>24</sup> It was found that noninvasive CTA was more accurate in the demonstration of the CAs than catheter angiography.<sup>25</sup>

## CONCLUSION

Ultrafast CT scan has become the imaging modality of choice for evaluation of CCVA in pediatric and adult patients. It is primarily meant to evaluate the extra-cardiac systemic and pulmonary arterial as well as venous system. It is the modality of choice for the evaluation of shunts, stents, conduits and post-operative complications.

## ACKNOWLEDGEMENTS

The authors would like to acknowledge statistician Mrs. Sucharita Suresh for her invaluable contribution.

*Funding: No funding sources*

*Conflict of interest: None declared*

*Ethical approval: The study was approved by the institutional ethics committee*

## REFERENCES

1. Marelli AJ, Mackie AS, Ionescu-Ittu R, Rahme E, Pilote L. Congenital Heart Disease in the General

- Population: Changing Prevalence and Age Distribution. *Circulation*. 2007;115:163-72.
2. Ntsinjana HN, Hughes ML, Taylor AM. The Role of Cardiovascular Magnetic Resonance in Pediatric Congenital Heart Disease. *J Cardiovascular Mag Resonance*. 2011;13:51.
3. Lai WW, Geva T, Shirali GS, Frommelt PC, Humes RA, Brook MM, et al. Guidelines and Standards for Performance of a Pediatric Echocardiogram: A Report from the Task Force of the Pediatric Council of the American Society of Echocardiography. *J Am Soc Echocardiogr*. 2006;19:1413-30.
4. Leschka S, Oechslin E, Husmann L, Desbiolles L, Marincek B, Genoni M, et al. Pre- and postoperative evaluation of congenital heart disease in children and adults with 64-section CT. *RadioGraph*. 2007;27:829-46.
5. Lock JLKJ, Perry SB. Diagnostic and Interventional Catheterisation in Congenital Heart Disease. 2nd edition. Springer; 1999.
6. Hollingsworth CL, Yoshizumi TT, Frush DP, Chan FP, Toncheva G, Nguyen G, et al. Pediatric cardiac-gated CT angiography: assessment of radiation dose. *Am J Roentgenol*. 2007;189:12-8.
7. Mehta R, Lee KJ, Chaturvedi R, Benson L. Complications of pediatric cardiac catheterization: a review in the current era. *Catheter Cardiovasc Interv*. 2008;72:278-85.
8. Gaca AM, Jagers JJ, Dudley LT, Bisset GS 3rd. Repair of congenital heart disease: a primer. Part 1. *Radiol*. 2008;247:617-31.
9. Dillman JR, Hernandez RJ. Role of CT in the Evaluation of Congenital Cardiovascular Disease in Children. *Am J Roentgenol*. 2009;192(5):1219-31.
10. Kilner PJ, Geva T, Kaemmerer H, Trindade PT, Schwitter J, Webb GD. Recommendations for cardiovascular magnetic resonance in adults with congenital heart disease from the respective working groups of the European Society of Cardiology. *Eur Heart J*. 2010;31:794-805.
11. Cheitlin MD, Armstrong WF, Aurigemma GP, Beller GA, Bierman FZ, Davis JL, et al. ACC/AHA/ASE 2003 guideline update for the clinical application of echocardiography: summary article: a report of the American college of cardiology/American heart association task force on practice guidelines (ACC/AHA/ASE committee to update the 1997 guidelines for the clinical application of echocardiography). *J Am Coll Cardiol*. 2003;42:954-70.
12. Taylor AM. Cardiac imaging: MR or CT? Which to use when. *Pediatr Radiol*. 2008;38(3):433-8.
13. Gilkeson RC, Ciancibello L, Zahka K. Multidetector CT evaluation of congenital heart disease in pediatric and adult patients. *Am J Roentgenol*. 2003;180:973-80.
14. Chen ML, Lo HS, Su HY, Chao IM. Coronary artery fistula: assessment with multidetector computed tomography and stress myocardial single photon emission computed tomography. *Clin Nucl Med*. 2009;34(2):96-8.
15. Gaca AM, Jagers JJ, Dudley LT, Bisset GS 3rd. Repair of congenital heart disease: a primer. Part 2. *Radiology*. 2008;248:44-60.
16. Greil GF, Schoebinger M, Kuettner A, Schaefer JF, Dammann F, Claussen CD, et al. Imaging of aortopulmonary collateral arteries with high-resolution multidetector CT. *Pediatr Radiol*. 2006;36:502-9.
17. Goo HW, Park IS, Ko JK, Park IS, Yoon CH, Hopkins KL, et al. CT of congenital heart disease: normal anatomy and typical pathologic conditions. *RadioGraph*. 2003;23:147-65.
18. Lee T, Tsai IC, Fu YC, Jan SL, Wang CC, Chang Y, et al. Using multidetector-row CT in neonates with complex congenital heart disease to replace diagnostic cardiac catheterization for anatomical investigation: initial experiences in technical and clinical feasibility. *Pediatr Radiol*. 2006;36:1273-82.
19. Ley S, Zaporozhan J, Arnold R, Eichhorn J, Schenk JP, Ulmer H, et al. Preoperative assessment and follow-up of congenital abnormalities of the pulmonary arteries using CT and MRI. *Eur Radiol*. 2007;17:151-62.
20. Dashottar S, Singh AK, Suhag V, Sunita BS, Singh RK. Unusual Case of Congenital Aneurysm of Proximal Pulmonary Artery Causing Lung Collapse. *J Cardiovas Dis Res*. 2015;6(1):31-6.
21. Ryerson L, Harder J. Totally anomalous pulmonary venous return. *Cardiol Young*. 2005;15:304-5.
22. Yang DH, Goo HW, Seo DM, Yun TJ, Park JJ, Park IS, et al. Multislice CT angiography of interrupted aortic arch. *Pediatr Radiol*. 2008;38:89-100.
23. Shih MC, Tholpady A, Kramer CM, Sydnor MK, Hagspiel KD. Surgical and endovascular repair of aortic coarctation: normal findings and appearance of complications on CT angiography and MR angiography. *Am J Roentgenol*. 2006;187:788.
24. Sparrow P, Merchant N, Provost Y, Doyle D, Nguyen E, Paul N. Cardiac MRI and CT features of inheritable and congenital conditions associated with sudden cardiac death. *Eur Radiol*. 2009;19:259-70.
25. Schmitt R, Froehner S, Brunn J, Wagner M, Brunner H, Cherevatyy O, et al. Congenital anomalies of the coronary arteries: imaging with contrast-enhanced, multidetector computed tomography. *Eur Radiol*. 2005;15:1110-21.

**Cite this article as:** Dashottar S, Singh AK, Senger KPS, Col Debnath J. Role of 256 slice CT scan in pre and postoperative evaluation of congenital cardiovascular anomalies: our experience at a tertiary care teaching hospital. *Int J Adv Med* 2017;4:425-32.