

Original Research Article

Bone marrow profile in hematological disorders: an experience from a tertiary care centre

Nusrat Bashir*, Bilal Musharaf, Ruby Reshi, Tazeen Jeelani, Danish Rafiq, Dekyong Angmo

Department of Pathology, GMC, Srinagar, Jammu and Kashmir, India

Received: 25 March 2018

Accepted: 21 April 2018

*Correspondence:

Dr. Nusrat Bashir,

E-mail: bashirnusrat@ymail.com

Copyright: © the author(s), publisher and licensee Medip Academy. This is an open-access article distributed under the terms of the Creative Commons Attribution Non-Commercial License, which permits unrestricted non-commercial use, distribution, and reproduction in any medium, provided the original work is properly cited.

ABSTRACT

Background: Bone marrow aspiration and trephine biopsy are two most important techniques which are complementary for diagnosing both neoplastic and non-neoplastic haematological diseases. The present study was conducted in the department of pathology to compare the role of bone marrow aspirate and trephine biopsy for diagnosing the haematological diseases.

Methods: The study was conducted in the department of pathology government medical college Srinagar over a period of 2 years from Feb 2016 to Jan 2018. The study was one-year retrospective and one year prospective. Bone marrow aspiration was done in 626 cases out of which biopsy was done in 300 cases.

Results: Out of the selected 300 cases where both aspiration and trephine biopsy were available, diagnostic material on bone marrow aspirate was adequate in 288 cases. 12 cases were aparticulate. Biopsy was inadequate in 8 cases. Overall megaloblastic anaemia (26.6%) was most common followed by dual deficiency anaemia. Multiple myeloma was the most common neoplastic pathology (13%) followed by acute leukaemia's (6%) and Chronic lymphoproliferative disorders (CLPDS) (5%). 1 case each of visceral leishmaniasis and malarial parasite were also noted. 4 cases (1.3%) of granulomatous pathology and 2 cases (0.6%) of Hodgkins lymphoma were diagnosed exclusively on bone marrow biopsy.

Conclusions: Bone marrow aspiration and biopsy are complimentary to each other in diagnosing hematological disorders with biopsy being gold standard in the assessment of cellularity, pattern, extent of tumor infiltration and focal infiltration. It is more helpful in diagnosing granulomatous pathology and metastatic deposits of tumors eliciting fibrotic response.

Keywords: Bone marrow, Examination, Hematological disorders

INTRODUCTION

Bone marrow aspiration and bone marrow biopsy are useful techniques in the diagnosis of both hematological and non-hematological disorders.

For bone marrow examination clinical findings, complete blood count, peripheral blood picture and other laboratory investigations are required.¹ Bone marrow aspiration

(BMA) is usually sufficient individually to diagnose nutritional anemia's, Acute leukemias, myelodysplasia, myeloma and Parasitic infestations.

Trephine biopsy does provide important diagnostic information in patients with granulomatous disease, myelofibrosis, bone marrow secondaries, lymphoma infiltration, storage disorders, marrow aplasia and Myeloproliferative neoplasms.

Bone marrow aspiration is useful in appreciating individual cell morphology. Whereas biopsy is useful in bone marrow architectural pattern and distribution.^{2,3}

The bone marrow evaluation may either confirm clinically suspected disease or may provide the previously unsuspected diagnosis.^{4,5} The aspirate yields semi-liquid bone marrow, which can be examined under a light microscope as well as analyzed by flowcytometry, chromosome analysis, polymerase chain reaction (PCR), Culture.

Frequently, a trephine biopsy is also obtained, which yields a narrow, cylindrically shaped solid piece of bone marrow which is examined microscopically (sometimes with the aid of immunohistochemistry) for cellularity and infiltrative processes. Bone marrow biopsy (BMB) is more sensitive in picking up focal lesions. Marrow reserve is better appreciated on BMB. BMB is also useful in immunohistochemical demonstration of antigens.

METHODS

The study was conducted in the department of pathology government medical college Srinagar. The study was conducted over a period of 2 years from Feb 2016- Jan 2018. Retrospective data was collected from record section of department of pathology. For prospective cases patients were enrolled for the procedure after screening from clinical departments. Written informed consent was taken before the procedure.

The procedure was done under local anesthesia (Inj. 2% xylocaine). PSIS was the most common site used for the procedure followed by ASIS. For aspiration we used Salah 16 G needle and for biopsy we used jamshedi needle. Aspirate slides were checked macroscopically for presence of particles and 2 cm biopsy was considered adequate on gross examination.

Aspirate slides were stained with leishman stain. Perls stain for iron stores was done in all cases. In all leukemia cases we performed myeloperoxidase staining. Trephine biopsy was processed as per standard protocol and stained with Hematoxylin and Eosin stain. Reticulin stain was done in case of myelofibrosis and reactive fibrosis for grading and WHO grading system was used. Complete blood count (CBC), Peripheral smear examination (PBF) was done in all cases.

Inclusion criteria

All cases where both aspiration and biopsy were available were selected.

Exclusion criteria

Cases where only aspiration was available.

Chi square test was used for statistical analysis.

RESULTS

In present study 626 bone marrow aspirations were done over a period of two years.

Authors included 300 cases in present study were both aspiration and biopsy were available. The age ranged from 6 months to 90 years with median age of 34.5 years. Males outnumbered females with M:F of 1.6:1.

Commonest presentation was pancytopenia (38.3% of cases) followed by bicytopenia (22% of cases).

Table 1: Hematological disorders among study subjects on aspiration.

Diagnosis	No of cases (n)	% of cases
Megaloblastic anemia	80	26.6
Normal study	36	12.2
Plasmacytosis	37	12.0
Dual deficiency anemia	21	07
Acute myeloid leukemia	18	06
Reactive marrow	14	4.6
Aplastic anemia	14	4.6
CLPD	11	3.6
Aparticulate	10	04
Iron deficiency anemia	08	2.6
Essential thrombocythemia	07	2.3
Anemia of chronic disease	07	2.3
Metastasis	06	2.0
ITP	04	1.3
PV	04	1.3
Acute lymphoblastic leukemia	03	1.3
MDS	04	1.3
CML	02	0.6
MF	02	0.6
Hemophagocytosis	02	0.6
Dry tap	02	0.6
Eosinophilia	02	0.6
MPN –U	01	0.3
Hypersplenism	01	0.3
Hemolytic anemia	01	0.3
Leishmaniasis	01	0.3
Malarial parasite	01	0.3
Total	300	100%

Most of the cases had hypercellular bone marrow (61.3%) followed by normocellular marrow (33.7%) and hypocellular marrow (5%).

Bone marrow aspiration and biopsy diagnosis are given in Table 1 and Table 2.

Anemia was the most common finding in present study (114 cases) followed by plasmacytosis (Figure 1). Among anemias megaloblastic anemia (Figure 2) was most common (80 cases) followed by dual deficiency anemia (21 cases) and aplastic anemia (Figure 3).

Table 2: Histopathological diagnosis of hematological disorders.

Diagnosis	No of cases (n)	% of cases
Erythroid hyperplasia	114	38
Plasmacytosis	39	13
Normal study	37	12
Acute myeloid leukemia	18	06
CLPD*	15	05
Aplastic anemia	15	05
Metastasis	11	3.6
ET**	08	2.6
Indequate biopsy	08	2.6
PV***	05	1.6
MDS****	05	1.6
ITP#	04	1.3
Granulomatous pathology	04	1.3
MF1	04	1.3
Acute lymphoblastic leukemia	04	01
CML2	03	01
Hodgkins Lymphoma	02	0.6
Leishmaniasis	01	0.3
Malarial parasite	01	0.3
Hypersplenism	01	0.3
Eosinophilia	01	0.3
MPN-U3	01	0.3
Hemopagocytosis	01	0.3
Total	300	100

*Chronic lymphoproliferative disorder, **Essential thrombocythemia, **Polycythemia vera, ****Myelodysplastic syndrome, # Immune mediated thrombocytopenia, ¹Myelofibrosis ²Chronic myeloid leukemia, ³Myeloproliferative neoplasm-Unclassified

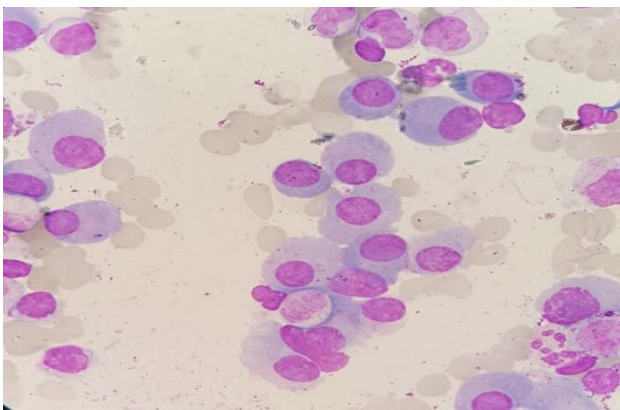


Figure 1: Histopathological diagnosis of hematological disorders.

Acute leukemia was seen in 22 cases with 18 cases of acute myeloid leukemia and 4 cases of acute lymphoblastic leukemia. Among myeloid leukemias commonest was AML-M1 (Figure 4) (6 cases) followed APML (4 cases) (Figure 5) and AML-M2 (3 cases). Authors received 30 bone marrow cases for staging of

nonhodgkins lymphomas with infiltration in 15 cases (Figure 5).

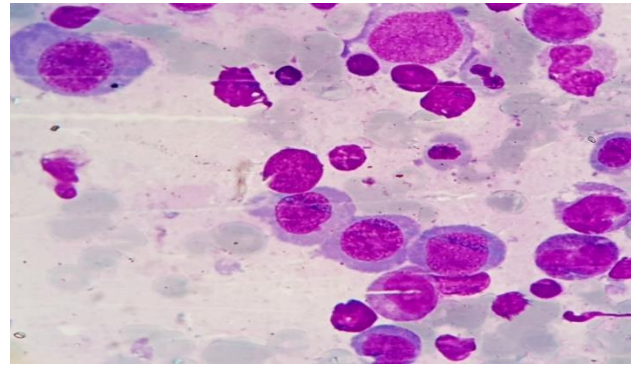


Figure 2: Bone marrow aspirate smears showing megaloblastic erythroid hyperplasia.

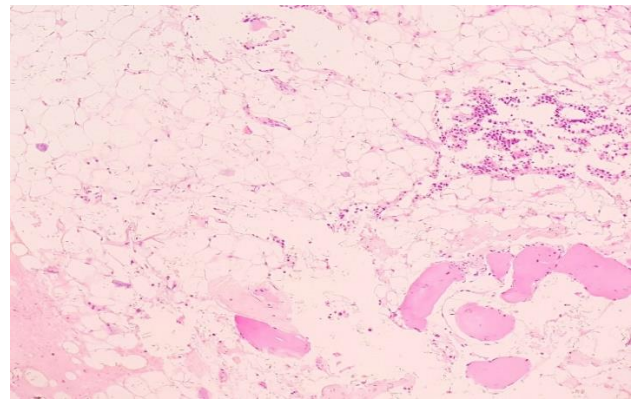


Figure 3: Bone marrow biopsy sections showing hypocellular marrow with diminished hematopoiesis.

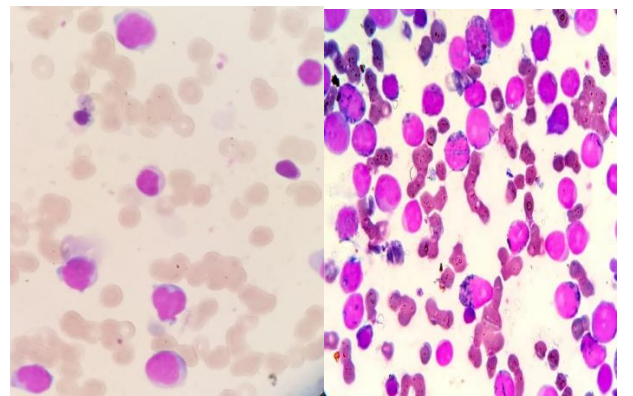


Figure 4a,4b: Bone marrow aspiration smears showing increased in case of AML-M1, Myeloperoxidase stain in AML-M2 showing blasts and auer rods positive for Myeloperoxidase.

Among staging in Hodgkins lymphoma 2 cases were positive for infiltration. Other neoplastic pathologies seen in present study included secondaries 11 cases (Figure 6) with unknown primary in 2 cases and few cases of myeloproliferative neoplasms including Essential

thrombocytopenia (Figure 8), Polycythemia vera, Chronic myeloid leukemia and myelofibrosis (Figure 7).

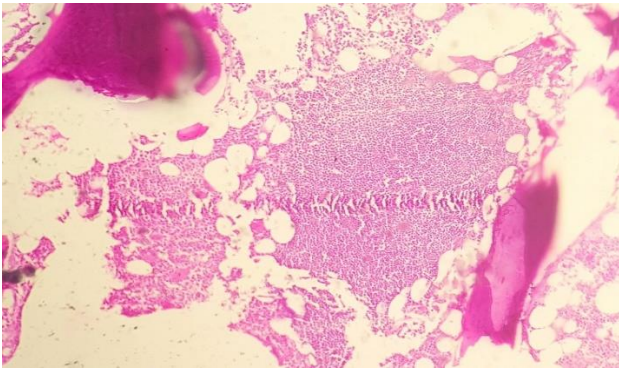


Figure 5: Bone marrow biopsy sections showing nodular pattern of infiltration in a case of nonhodgkins lymphoma.

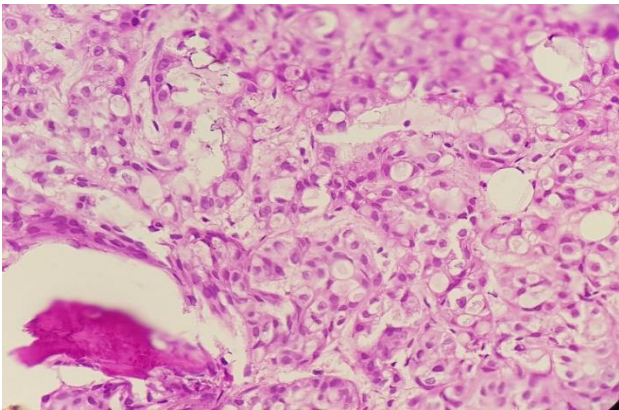


Figure 6: Bone marrow biopsy sections showing metastatic deposits of adenocarcinoma.

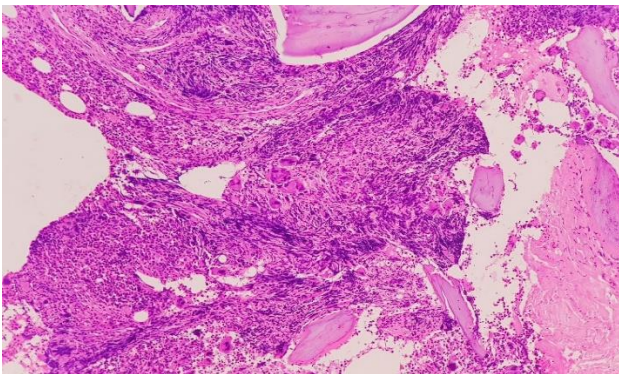


Figure 7: Bone marrow biopsy showing megakaryocytic hyperplasia and areas of fibrosis in a case of primary myelofibrosis.

2 cases each of visceral leishmaniasis (Figure 8) and malarial parasite were also seen in present study. Myelodysplastic syndrome (MDS) was diagnosed in cases after clinical correlation in cases previously treated for megaloblastic anemia and not responding to treatment.

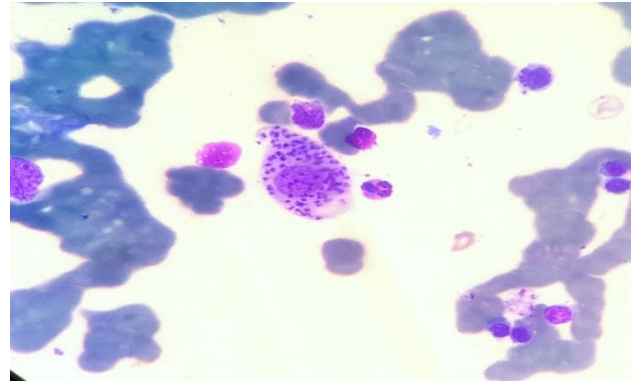


Figure 8: Bone marrow aspirate smear showing intracellular LD bodies in a case of visceral leishmaniasis.

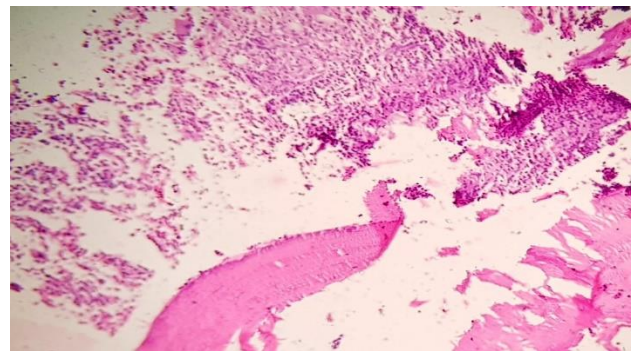


Figure 9: Bone marrow biopsy sections showing granuloma in a case of disseminated tuberculosis.

All the 4 cases of granulomatous pathology (Figure 9) were exclusively diagnosed on bone marrow biopsy with aspiration showing reactive marrow. Among these 3 cases were of tuberculosis and 1 case turned out to be brucellosis.

Diagnostic accuracy of bone marrow biopsy in present study was 95% with P-value was 0.001 which was statistically significant (P-value <0.05) by chi square test.

DISCUSSION

Bone marrow aspiration and trephine biopsy are the two procedures done for the diagnosis of hematological and non-hematological disorders and are complimentary to each other. Frequently it is a combination of clues gathered from examination of several different preparations that leads to a correct diagnosis.⁶

We selected 300 cases in present study where both aspiration and biopsy were available. Aspiration was adequate for diagnosis in 288 cases (96%) and biopsy was adequate in 292 cases (97.3%) of cases. Males outnumbered females with M:F of 1.6:1. Commonest presentation in present study was pancytopenia (38.3% of cases) followed by bicytopenia (22% of cases). Similar to present study pancytopenia was the commonest

presentation in a study done by Ahmed et al.⁷ A study by Bhatnagar et al. from India reported incidence of pancytopenia seen in 54.5% cases and bicytopenia seen in 45.5% cases which is also similar to present study.⁸ Most of the cases in present study had hypercellular bone marrow (61.3%) followed by normocellular marrow (33.7%) and hypocellular marrow (5%). Anemia was most common finding in present study (114 cases) followed by plasmacytosis (Figure 1). Among anemias megaloblastic anemia (Figure 2) was most common (80 cases) followed by dual deficiency anemia (21 cases) and aplastic anemia. The commonest cause of pancytopenia reported in various studies throughout the world is aplastic anemia.⁹⁻¹¹

However, authors observed megaloblastic anemia as the commonest cause of pancytopenia followed by leukemia and hypoplastic marrow in the study. Some studies conducted in India have also reported megaloblastic anemia to be the major cause of pancytopenia. Among neoplastic diseases multiple myeloma was most common in present study (39 cases) out of which only 2 cases were diagnosed biopsy alone with focal marrow involvement. Acute leukemia was seen in 22 cases with 18 cases of acute myeloid leukemia and 4 cases of acute lymphoblastic leukemia. Among myeloid leukemias commonest was AML-M1 (6 cases) followed APML (4 cases) and AML-M2 (3 cases). In present study, 1 out of 22 cases of acute leukemia presenting with dry tap on aspirate showed increase in fibrosis on trephine sections. Similarly, all 11 cases of metastatic lesions were diagnosed on biopsy sections with their respective aspirate smears showing metastatic deposits in 6 cases only. So, a dry tap or inadequate aspiration should always be accompanied by trephine biopsy to arrive at a final diagnosis. Primary was unknown in 2 cases of metastatic deposits were IHC was used on biopsy for identifying the primary site. According to Bird and Jacobs, marked increase in reticulin in both acute lymphoblastic and acute myeloblastic leukemia may lead to dry tap We received 30 cases of bone marrow for staging of nonhodgkins lymphoma with 15 cases showing evidence of marrow involvement in biopsy. In corresponding aspiration smears 11 cases showed infiltration and in 4 cases we missed infiltration.¹² This could be explained by focal pattern of infiltration and fibrosis seen on biopsy. Kumar A showed involvement by lymphoma on biopsy in 27 cases (55.10%).¹³ Unilateral positivity was found in four cases (14.81% cases). The overall incidence of marrow involvement by NHL was 55.1%. The diagnosis of aplastic anemia diagnosis was confirmed only after trephine biopsy, as the trephine biopsy is the accurate tool to assess marrow cellularity hence is of utmost importance in diagnosing Aplastic anemia.¹¹ In chronic myeloproliferative neoplasms (MPNS), trephine biopsy added information about fibrosis, cellularity and morphology of megakaryocytes. All cases 4 of granulomatous pathology and 2 cases of Hodgkins lymphoma infiltration were diagnosed on biopsy alone with their corresponding aspirate smears showing

reactive marrow only. Myelodysplastic syndrome (MDS) was diagnosed in cases who were previously treated for megaloblastic anemia not responding to the treatment. One case of Hypoplastic myelodysplastic syndrome was missed on aspirate because of diluted nature of marrow smears. 2 cases each of visceral leishmaniasis and malarial parasite were also seen in present study diagnosed on both aspirate and biopsy. Gupta et al in their study have reported that bone marrow aspiration and trephine biopsy are complementary to each other to arrive at a definitive diagnosis. This was also observed in present study that as cases of metastatic lesions with marrow fibrosis and aparticle aspirate were picked on biopsy alone similarly few cases of focal NHL infiltration with normal aspirate had infiltration on biopsy sections. In present study all cases of Granulomatous pathology and Hodgkins lymphoma infiltration were diagnosed by biopsy alone.

CONCLUSION

Bone marrow aspiration (BMA) and bone marrow biopsy (BMB) are complimentary to each other. For diagnostic purpose both the procedures can be done simultaneously as BMA gives better morphology of the cells and biopsy is gold standard in the assessment of cellularity, pattern, extent of tumor infiltration and focal infiltration. BMB is especially useful in cases of Granulomatous diseases, myelodysplastic syndromes, and myeloproliferative disorders, non-Hodgkin's Lymphomas, aplastic anemia and metastatic tumors eliciting fibrotic response.

Funding: No funding sources

Conflict of interest: None declared

Ethical approval: The study was approved by the Institutional Ethics Committee

REFERENCES

1. Brown DC, Gatter KC. The bone marrow trephine biopsy: a review of normal histology. *Histopath.* 1993;22:411-22.
2. Sola CM, Rimsza LM, Christensen RD. A bone marrow biopsy technique suitable for use in neonates. *Br J Hematol.* 1999;107:458-60.
3. Brynes RK, McKenna RW, Sundberg RD. Bone marrow aspiration and trephine biopsy: an approach to a thorough study. *Am J Clin Pathol.* 1978;70:753-9.
4. Chandra S, Chandra H, Saini S. Bone marrow metastasis by solid tumors-probable hematological indicators and comparison of bone marrow aspirate, touch imprint and trephine biopsy. *Hematology.* 2010;15:368-72.
5. Nanda A, Basu S, Marwaha N. Bone marrow trephine biopsy as an adjunct to bone marrow aspiration. *J Assoc Physicians India.* 2002;50:893-5
6. Sola CM, Rimsza LM, Christensen RD. A bone marrow biopsy technique suitable for use in neonates. *Br J Hematol.* 1999;107:458-60.

7. Ahmad SQ, Khan OU, Zafar N. Utility of bone marrow examination in a secondary care hospital. *JRMC.* 2011;15:40-1.
8. Bhatnagar SK, Chandra K, Narayan S, Sharma S, Singh V, Dutta AK. Pancytopenia in children: Etiological Profile. *J Trop Pediatr.* 2005;51(4):236-39.
9. Khan TA, Khan IA, Mahmood K. Clinicohematological spectrum of pancytopenia in a tertiary care hospital. *JPMI.* 2013; 27(2):143-7.
10. Jalbani A, Ansari IA, Chutto M, Gurbakhshani KM, Shah AH. Proportion of megaloblastic anemia in 40 cases with pancytopenia at CMC hospital Larkana. *Medical Channel.* 2009;15:34-7.
11. Hossain MA, Akond AK, Chowdhary MK. Pancytopenia: a study of 50 cases. *Bangladesh J Pathol.* 1992;1:9-12.
12. Bird AR, Jacobs P. Trepine biopsy of bone marrow. *S Afr Med J.* 1983;64:271-6.
13. Kumar S, Rau AR, Naik R, Kini H, Mathai AM, Pai MR et al. Bone marrow biopsy in non-Hodgkin lymphoma: a morphological study *Indian J Pathol Microbiol.* 2009 Jul 1;52(3):332.

Cite this article as: Bashir N, Musharaf B, Reshi R, Jeelani T, Rafiq D, Angmo D. Bone marrow profile in hematological disorders: an experience from a tertiary care centre. *Int J Adv Med* 2018;5:608-13.