

## Case Report

# Occurrence of high altitude cerebral edema (hace) and high altitude pulmonary edema (HAPO) simultaneously at 12000 ft: a rare phenomenon

Dharmendra Kumar\*, T. K. Rath, L. C. Verma

Department of Medicine, AMC Indian Army, Theng, Sikkim, India

**Received:** 25 April 2018

**Accepted:** 28 May 2018

### \*Correspondence:

Dr. Dharmendra Kumar,

E-mail: [dk.dharmendra2009@gmail.com](mailto:dk.dharmendra2009@gmail.com)

**Copyright:** © the author(s), publisher and licensee Medip Academy. This is an open-access article distributed under the terms of the Creative Commons Attribution Non-Commercial License, which permits unrestricted non-commercial use, distribution, and reproduction in any medium, provided the original work is properly cited.

## ABSTRACT

High altitude cerebral edema (HACE) and High altitude pulmonary edema (HAPO) are the most dreaded complications related to high altitude. Authors managed a case of HACE and HAPO simultaneously set at unusually low height (1200 ft) in a patient. The altitude was not too much to develop these comorbidities as studied earlier. Relationship with altitude was immaterial in our case. However, rapid ascent without proper acclimatisation, young and tender age, male sex and smoking were associated contributing factors. He was managed with standard protocol and descent to lower altitude.

**Keywords:** Acute mountain sickness (AMS), Altitude, Descent, High altitude cerebral edema (HACE), High Altitude pulmonary edema (HAPO), Oxygenation

## INTRODUCTION

High altitude is inherently prone to cause life threatening illnesses especially among vulnerable group of people without adequate knowledge and training. High Altitude poses serious health hazards to mankind due to Inhospitable terrain, extreme climatic conditions and low partial pressure of Oxygen. The two most dreaded complications being high altitude cerebral edema (HACE) and high altitude pulmonary edema (HAPO). acute mountain sickness (AMS) is a less severe form of HA related illness.

AMS presents with nonspecific symptoms like headache, nausea and vomiting, fatigue and dizziness that develops within 6 to 12 hours of ascent. AMS and HACE are considered to be continuum of spectrum in which HACE presents with ataxia and altered consciousness generally without neurological deficit.<sup>1</sup> HAPO presents with dyspnoea, cough, central cyanosis, tachypnoea, tachycardia and crackles on chest auscultation.<sup>2</sup> HACE

occurs in 13-20% of individuals with HAPO and about 50% of individuals who die from HAPO.<sup>3</sup> Major pathophysiologic mechanism contributing to HAPO is exaggerated hypoxic pulmonary vasoconstriction causing elevated pulmonary capillary pressure.<sup>4</sup> The pathophysiology of HACE involves hypoxia induced vasogenic edema or hypoxia induced cytogenic edema or combination of both.<sup>5</sup>

## CASE REPORT

27-year-old patient, tourist from Kolkata (WB) India, a known smoker with no other comorbidities. He was on a short trip on motorbike to Gurudongmar lake at 17000 ft in North Sikkim. After an overnight stay at Lachen (9000 ft), he started his onward journey next morning. However, while enroute to the lake, his bike broke down and had to take a halt at Thangu (12000 ft). By afternoon the patient complained of frontal headache which was throbbing in nature associated with vomiting and restlessness. After 2 to 3 hours he developed ataxia and

altered cognitive functions. His friends noticed him to be confused while talking. By 2000 hrs he progressed to breathlessness and was evacuated to Army Hospital at Chungthang (6000 ft).

### **On examination**

Vital parameters: Pulse rate 130 beats per minute and regular. Blood pressure 106/70 mm Hg on RAS. Respiratory rate 24/minute. SPO2 90% with 8 Liters of Oxygen. Central cyanosis was present.

### **CNS examination**

Patient was drowsy and not oriented to time place and person. No profound neurological deficit detected. Ataxia with flexor plantar response seen. No sensory or bladder bowel involvement found.

### **Respiratory system**

B/L coarse crepitations present Lt>Rt

### **Investigation**

Blood tests TLC 19x10<sup>3</sup> (polymorph 89). Blood sugar random 97mg/dl, bilirubin total 1.6 mg/dl, urea/creatinine 22/0.8 ECG- sinus tachycardia. CXR: B/L alveolar opacifications. CECT chest: B/L lower lobe ground glass opacifications, more on the left side than right suggestive of pulmonary edema. CT HEAD: Normal

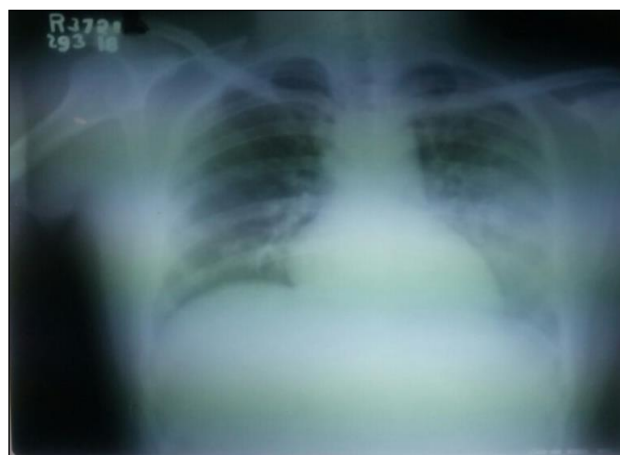### **Course in hospital**

Commenced with injection dexamethasone 8mg I.V. stat followed by 6mg orally 6 hourly, Tab Nifedipine SR 20mg bid, oxygen supplementation 7-8 liters per min. Patient started showing improvement by next day with positive progress in sensorium and reduced oxygen requirement.

On 2<sup>nd</sup> day of admission his sensorium further improved, he became oriented to time, place and person. On 3<sup>rd</sup> day he regained full sensorium and gait and he was maintaining a oxygen saturation of 95% on 2 liters of oxygen. On 4<sup>th</sup> day of admission, he was discharged to home with advice of PFTs within 15 days.

## **DISCUSSION**

AMS usually has benign course whereas HACE and HAPO have mortality rates upto 40%.<sup>9</sup> Hence, early recognition and descent to lower altitude are cornerstone in the management of HACE and HAPO. If descent is not possible because of extreme climatic conditions, hyperbaric chamber bag is lifesaving.<sup>6</sup> Preventive measures include adequate acclimatization, avoidance of risk factors and pharmacological prophylaxis.<sup>5</sup> Adequate hydration countering the fluid loss also prevents AMS.<sup>1</sup>



**Figure 1: Chest X ray B/L alveolar opacities.**



**Figure 2: CECT CHEST B/L lower lobe ground glass opacifications**

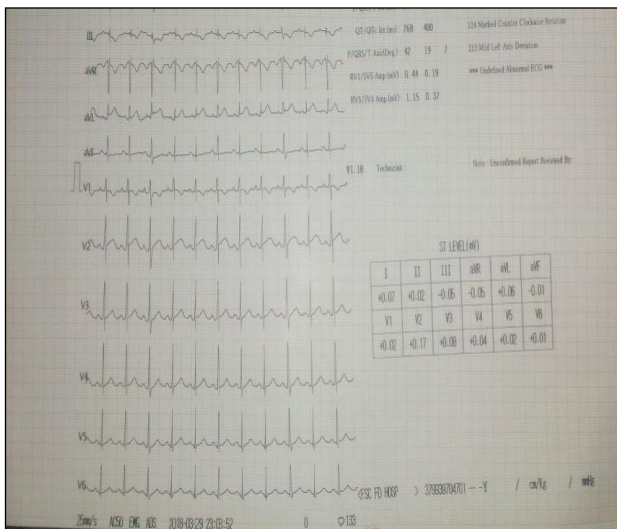
Predisposing factors for early development of HAPO and HACE are rapid rate of ascent, prior history of high altitude illness, severe exertion, young and tender age, male sex, respiratory tract infection, cold environment, abnormalities of cardiopulmonary circulation and smoking.<sup>1,8</sup> The risk factors present in studied patient were young age, male sex, rapid ascent without proper acclimatization and smoking. HACE is usually not encountered below 9840 ft and HAPO is also rare below this altitude.<sup>9</sup> In earlier studies, HAPO and HACE as comorbidity were seen at super high-altitude areas above 23000 ft.<sup>7</sup> However, in this particular case the altitude was only 12000 ft. Hence the interrelationship between simultaneous occurrence of HAPO and HACE to altitude cannot be established.

Based on presentation, D/D could have been of CNS involvement, posterior circulation stroke, CVT, SOL etc. With respiratory involvement it might have been Pneumonia, PTE and Heart failure. However, based on strong personal history, clinical examination and risk factors involved, a provisional diagnosis of HACE with HAPO was tagged. Role of neuro-imaging in diagnosis of HACE is limited, findings ranging from near normal to

mild oedema. MRI brain may show hyperintense posterior body and splenium of corpus callosum.<sup>1</sup> CT head was normal in studied patient. MRI facility was non-existing in present set up. For severe AMS, HAPO and HACE, descent with Oxygenation (4-6 L/min) is the main stay of management.<sup>1,8,9</sup> Oxygen increases arterial perfusion and reduces pulmonary artery pressure, heart rate and respiratory rate and alleviates other symptoms.<sup>3</sup> In ibid case authors initially supplemented 8 liters of oxygen which was tapered gradually.

Apart from descent, mild to moderate AMS can be managed with NSAIDS, oxygen inhalation and Acetazolamide (250mg bid), while severe AMS will require additionally Dexamethasone.<sup>1</sup>

Nifedipine SR 30mg 12hrly has got beneficial effect in the management of HAPO.<sup>1-3</sup> The hypothetical complication of Nifedipine is hypotension, however no study has proved it, in that case 10-20mg 12 hourly also gives good results. In present case authors administered Nifedipine 20mg 12 hourly.



**Figure 3: ECG sinus tachycardia.**

In management of HACE, high flow oxygen, Dexamethasone 8mg stat followed by 4-6mg 6hourly i.v./orally given.<sup>1,2</sup> In present case, authors used the same dose of Dexamethasone with favorable result. Other cerebral decongestants like parenteral mannitol, low dose furosemide and oral glycerol have been used in earlier cases without proven evidence of efficacy.<sup>10</sup>

## CONCLUSION

High altitude illnesses are potentially life-threatening conditions which requires high index of suspicion, prompt intervention in form of rapid descent and oxygen

therapy. No altitude is safe for developing high altitude illness as in present case both HAPO/HACE developed at 12000 feet height only.

Contraindications to traveling to high altitude are sickle cell anemia, COPD, bronchial asthma, uncompensated heart failure and pulmonary artery hypertension.<sup>2</sup>

So before planning a trip to mighty mountains individuals should be aware of high altitude related illness and therefore be trained well in acclimatization and take prophylactic measures like taking adequate oral fluids and undergo acclimatization in letter and spirit.

*Funding: No funding sources*

*Conflict of interest: None declared*

*Ethical approval: Not required*

## REFERENCES

- Basnyat B, Tabin G. Altitude Illness. *Harrisons Principles of Internal Medicine* 19<sup>th</sup> Edition. 3;476:1-4.
- Alex J. Altitude Illness. *Am Coll Sports Med*.2015;14(2):82-3.
- Paralikar SJ, Paralikar JH. High Altitude Medicine. *Indian J Occup Env Med*.2010;14(1):6-12.
- Maggiorini M, Brunner-La Rocca HP, Peth S, Fischler M, Böhm T, et al. Both tadalafil and dexamethasone may reduce the incidence of high-altitude pulmonary edema: a randomized trial. *Ann Internal Med*. 2006;145(7):497-506.
- Cymerman A, Rock PB. A handbook for medical officers. Medical problems in high mountain environments. US army research institute of environment medicine Thermal and mountain medicine division. Technical Report.1994 94-2.
- Kiyawat V, Sathian B, Chawla R, garg A. High Altitude Illness: Current Trends. *Webmed Central Medicine* 2012;3(6):WMC003521.
- Khan ID. Comorbid Cerebral Pulmonary Edema at 7010m/23000ft: an extreme altitude perspective. *Bangladesh J Med Sci*. 2013;14(1):87.
- MacInnis MJ, Carter EA, Freeman MG, Pandit BP, Siwakoti A, Subedi A, et al. A Prospective Epidemiological Study of Acute Mountain Sickness in Nepalese Pilgrims Ascending to High Altitude (4380 m). *PLOS one*.2013;8(10):e75644
- Netzer N, Strohl K, Faulhaber M, Gatterer H, Bartscher M. Hypoxia-related altitude illnesses. *J Travel Med*. 2013;20(4):247-55.

**Cite this article as:** Kumar D, Rath TK, Verma LC. Occurrence of high altitude cerebral edema(hace) and high altitude pulmonary edema (HAPO) simultaneously at 12000 ft: a rare phenomenon. *Int J Adv Med* 2018;5:1075-7.