

## Original Research Article

# A prospective study of electrocardiographic and echocardiographic changes in patients with cerebrovascular accidents

Chandrababu Devarapu<sup>1</sup>, Lokesh S.<sup>2\*</sup>

<sup>1</sup>Department of Gastroenterology, Cauvery heart and Multi-speciality hospital, Mysuru, Karnataka, India

<sup>2</sup>Department of General Medicine, Vydehi Institute of Medical Sciences and Research Center, Whitefield, Bengaluru, Karnataka, India

**Received:** 21 June 2018

**Accepted:** 23 June 2018

### \*Correspondence:

Dr. Lokesh S.,

E-mail: lokeshsdoc@gmail.com

**Copyright:** © the author(s), publisher and licensee Medip Academy. This is an open-access article distributed under the terms of the Creative Commons Attribution Non-Commercial License, which permits unrestricted non-commercial use, distribution, and reproduction in any medium, provided the original work is properly cited.

## ABSTRACT

**Background:** Cerebrovascular accident also called as stroke is defined as the sudden onset of neurological deficit that can be attributable to a focal vascular cause. Many studies in the past have demonstrated the fact that neurological abnormalities produce Electrocardiographic changes without any underlying cardiac lesions. Present study is done to analyze different changes in Electrocardiogram and echocardiographic patterns in the cases of cerebrovascular accidents and to assess whether these different changes have got any prognostic significance in these patients.

**Methods:** In this study 100 patients of acute stroke admitted between May 2011 to August 2012 in Vydehi institute of medical sciences and research centre were considered and subjected to CT scan of brain, Electrocardiogram and 2D echocardiography within 24 hours of admission. Follow-up was done within the hospital to know the prognosis of all the patients.

**Results:** Out of 100 patients majority of them had ischemic stroke accounting for 80% and remaining 20% of patients had haemorrhagic stroke. Abnormal Electrocardiographic changes were seen in 64% patients and 58% patients showed abnormal Echocardiography. ECG changes seen are Tachycardia, QTc prolongation, T wave inversion, ST depression, U waves and Bradycardia. Commonly seen echocardiographic changes were LV dysfunction, mitral valve abnormality, aortic valve abnormality. Overall mortality in patients with abnormal ECG was 28.12% compared to 11.11% in patients with normal ECG and it was statistically not significant. Overall mortality in patients with abnormal 2D echocardiography was 31.03% compared to patients with normal 2D Echocardiography which was 4.76% and it was statistically significant.

**Conclusions:** From this study we conclude that ECG abnormalities in stroke patients do not have any prognostic significance. But LV dysfunction has prognostic significance in predicting mortality in cerebrovascular accident.

**Keywords:** 2D echocardiography, Cerebrovascular accidents, ECG, Haemorrhagic stroke, Ischemic stroke

## INTRODUCTION

Stroke is conventionally described as a neurological deficit attributed to an acute focal injury of the central nervous system (CNS) by a vascular cause, including cerebral infarction, intracerebral hemorrhage (ICH), and

subarachnoid hemorrhage (SAH) which accounts for major cause of disability and death worldwide.

According to Stroke Council of the American Heart Association/American Stroke Association, CNS infarction is defined as brain, spinal cord, or retinal cell death attributable to ischemia, based on either

pathological, imaging, or other objective evidence of cerebral, spinal cord, or retinal focal ischemic injury in a defined vascular distribution; or based on clinical evidence of cerebral, spinal cord, or retinal focal ischemic injury persisting  $\geq 24$  hours or until death, and other etiologies excluded.

Stroke caused by intracerebral hemorrhage is defined as the Rapidly developing clinical signs of neurological dysfunction attributable to a focal collection of blood within the brain parenchyma or ventricular system that is not caused by trauma.<sup>1</sup>

Cerebrovascular accidents are the second leading cause for the deaths worldwide accounting for about 6.2 million deaths in the year 2011. With the present trends it has been projected that mortality due to stroke in united states will be doubled by 2030.<sup>2</sup>

Many studies done earlier has shown that ECG changes can occur in stroke patients even without any underlying cardiac abnormalities. These changes include ST-T changes, QTc prolongation, abnormal U waves etc.<sup>3-5</sup>

Few studies have also demonstrated 2D echocardiographic changes in stroke patients in the form of LV dysfunction, aortic valvular disease, mitral valve prolapse etc.<sup>6</sup>

Hence the present study is done with the objective to analyze different electrocardiographic patterns and echocardiographic changes in patients with cerebrovascular accident and also to check whether these changes has got any prognostic significance.

## METHODS

This is Descriptive Observational Clinical study. 100 patients admitted in the Department of General medicine of Vydehi institute of medical sciences and research centre, Bengaluru during the period of May 2011 to August 2012, who are fitting into the inclusion criteria were included in the study. All the patients above 18 years of age presenting with stroke within 72 hours of onset were included in the study.

Stroke that occur secondary to trauma, neuro-infections, malignancy, patients with underlying cardiac disorders, Electrolyte disturbances and those patients presenting after 72 hours of onset of stroke were excluded.

After admission a detailed history and clinical examination including fundoscopy and cardiovascular examination were carried out in all the cases.

The diagnosis of CVA was made on the basis of Temporal profile of clinical syndrome, Clinical examination and CT scan of brain of the patients.

A 12 lead ECG and 2D echocardiography was done within 24 hours of admission. All patients were subjected to investigations like: complete blood count, erythrocyte sedimentation rate, blood urea and serum creatinine, serum electrolytes and lipid profile

In hospital follow-up was done to know their prognosis under two categories: live/dead. Results were analyzed with reference to age, sex and risk factors and mortality. Study was approved by the institutional ethics committee.

## Statistical analysis

All the data was analyzed using IBM SPSS ver. 20 and expressed in the form of numbers and percentage. Chi-square test was used to establish the significance level between groups. P value of  $<0.05$  was considered as significant.

## RESULTS

In present study out of 100 patients 69 were male and 31 were female patients with male to female ratio of 2.22:1. Most common age group for stroke was between 61-70 years. Present study shows that hypertension as the most common risk factor and was present in 50% of the patients, followed by smoking in 30%, diabetes mellitus in 30% of patients, past history of stroke in 20% and hyperlipidemia in 10% of patients. Many patients especially male had combination of risk factors. Out of 100 patients' majority of them had ischemic stroke accounting for 80% and remaining 20% of patients had haemorrhagic stroke. Abnormal electrocardiographic changes were seen in 64% patients and 58% patients showed abnormal echocardiography.

Compared to ischemic stroke (62.5%) electrocardiographic changes were more commonly seen with haemorrhagic stroke (70%). Similarly 2D Echo abnormalities were also more common in haemorrhagic stroke accounting for 80% compared to ischemic stroke which is 72.5%.

**Table 1: Mortality in stroke patients and its correlation with ECG changes.**

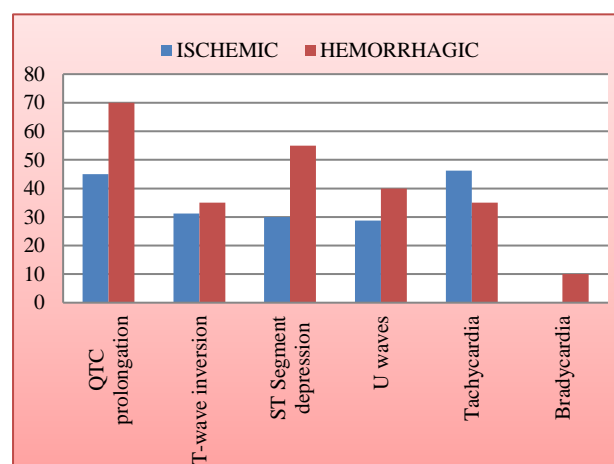
Type of ECG changes	Stroke patients				P value
	Alive		Dead		
	No	%	No	%	
QTc prolongation	37	45.12	13	72.22	p>0.05
T Wave inversion	26	31.70	6	33.33	p>0.05
ST segment depression	28	34.14	8	44.44	p>0.05
U Waves	26	31.7	5	27.77	p>0.05

**Table 2: Mortality in stroke patients and its co-relation with Echo changes.**

2D Echo changes	Stroke patients				P Value	Chi- square
	Alive		Dead			
	No	%	No	%		
LV dysfunction	19	23.75	16	80.00	P<0.001	18.85
Mitral valve abnormality	13	16.25	3	15.00	P<0.05	0.56
Aortic valve abnormality	5	6.25	1	5	--	--
Normal	42	52.5	2	10.00	p>0.01	15.47

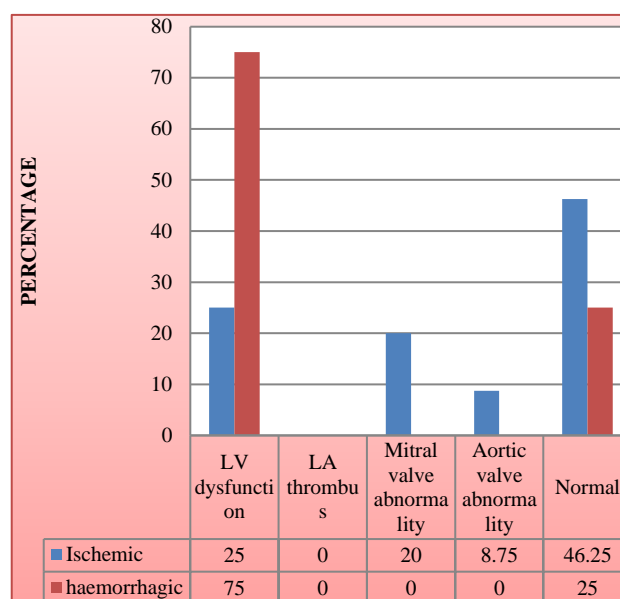
In present study commonly, seen ECG changes are Tachycardia, QTc prolongation, T wave inversion, ST depression, U waves and Bradycardia (Figure 1).

It was evident that most common 2D Echocardiographic abnormality among haemorrhagic stroke patients was LV dysfunction seen in 75% of patients. However, among ischemic stroke patients LV dysfunction was seen in only 25% of patients followed by mitral valve abnormality in 20% and aortic valve abnormality seen in 8.75% of patients (Figure 2). Normal echo was seen in 46.25% of infarct and 25% in hemorrhagic stroke.

**Figure 1: Percentage wise ECG changes in stroke patients.**

As we can see from Table 1 mortality was higher in patients of stroke with QTc prolonged (72.22%) and ST segment depression (44.44%) followed by T-wave inversion (33.33%), and U waves (27.77) but none of them were statistically significant. Overall mortality in patients with abnormal ECG was 28.12% compared to 11.11% in patients with normal ECG and it is statistically not significant.

Table 2 depict that mortality was higher in patients with LV dysfunction (80.00%) (p<0.001) and was statistically significant followed by mitral valve abnormality (15.00) (p<0.05). Overall mortality in patients with abnormal 2D echocardiography was 31.03% compared to patients with normal 2D Echocardiography which was just 4.76% and it was statistically significant.

**Figure 2: Percentage wise 2D Echo changes in stroke patients.**

## DISCUSSION

Abnormal ECG changes in patients presenting with cerebrovascular accidents poses diagnostic challenge because many studies done earlier have shown that primary neurological disorders also can produce ECG changes.<sup>7-9</sup> In such situations any decisions to go ahead with interventions will get delayed.

In the present study group 100 patients 69 male patients and 31 female patients were included which is comparable to the study done in Bangalore by Nagaraja et al.<sup>10</sup> which also showed the male preponderance of 67%.

80% of the cases are ischemic type and 20% are of haemorrhagic type. In the study done in Kolkata by Banerjee et al it shows ischemic strokes in 68% and haemorrhagic stroke in 32%.<sup>11</sup> In one more study done in Mumbai by Dalal et al, it showed 80.2% cases of ischemic strokes and 17.7% cases of hemorrhagic strokes which is comparable with the present study.<sup>12</sup>

Analyzing the risk factors for the stroke in the present study it was found that, hypertension is the most common risk factors seen in 50 % of patients, followed by the diabetes mellitus (30%), smoking (30%), previous history of stroke (20%) and dyslipidemia was least seen in 10% of patients. In the study done by Santalucia et al hypertension was the major risk factor for stroke seen in 71.6% followed by Diabetes mellitus (21.5%), smoking (20.6%) and Dyslipidemia (27.4%).<sup>13</sup>

Present study showed ECG changes more commonly in haemorrhagic stroke (70%) compared to ischemic stroke (62.5%) and Common ECG abnormalities seen are QTc prolongation (50%), Tachycardia (44%), ST depression (35%), T-wave inversions (32%) followed by U-wave (31%). Study done by Goldstien shows QT prolongation (45%), tachycardia (28%), ST depression (27%), T wave inversion (29%), U waves (28%), and arrhythmias (27%) which was comparable to our study.<sup>5</sup>

Present study showed 2D Echo abnormality in the form of LV dysfunction in 75% of haemorrhagic stroke patients and 25% of ischemic stroke patients. However ischemic stroke patients also showed mitral valve abnormality and aortic valve abnormality in 20% and 8.75% of patients respectively. Study done by Gagliardi et al and Uma et al showed comparable LV dysfunction of 22.22% and 26% in ischemic stroke patients respectively.<sup>6,14</sup>

## CONCLUSION

From the current study we conclude that Electrocardiographic changes can occur in patients presenting with cerebrovascular accidents even in the absence of any underlying cardiac disorders. Common ECG changes seen in stroke patients are QTc prolongation, ST segment changes, T wave inversion, U waves, sinus tachycardia but the value of these changes in predicting the mortality was poor. However, in contrast 2D echocardiographic abnormalities especially LV dysfunction can predict the mortality chances in patients with stroke. Hence all the patients presenting with stroke should undergo ECG and 2D Echocardiography as a part of the initial evaluation.

*Funding: No funding sources*

*Conflict of interest: None declared*

*Ethical approval: The study was approved by the Institutional Ethics Committee*

## REFERENCES

1. Sacco RL. An updated definition of stroke for the 21st century: A statement for healthcare professionals from

- the American Heart Association/American Stroke Association. *Stroke* 2013;44(7):2064-89.
2. Wade S. Smith, S. Claiborne Johnston, J. Claude Hemphill In *Cerebrovascular diseases* In: Kasper, Fauci, Hauser, Longo, Jameson, Loscalzo eds. *Harrison's principles of Internal medicine*. 19<sup>th</sup> ed. McGraw-Hill;2012:Chap. 446(2): 2559-2585.
3. Dogan A, Tunc E, Ozturk M, Kerman M, Electrocardiographic changes in patients with ischemic stroke and their prognostic importance, *Int J Clin Practice*.2004;58(5):436-40.
4. Purushothaman S, Salmani D, Prarthana KG, Bandelkar SM, Varghese S. Study of ECG changes and its relation to mortality in cases of cerebrovascular accidents. *J Natural Sci Biol Med*. 2014;5(2):434-6.
5. Goldstein DS. The electrocardiogram in stroke: relationship to pathophysiological type and comparison with prior tracings. *Stroke*. 1979;10(3):253-9.
6. Gagliardi R, Benvenuti L, Frosini F, Ammannati F, Barletta GA, Fantini F. Frequency of echocardiographic abnormalities in patients with ischemia of the carotid territory-a preliminary report. *Stroke*. 1985;16(1):118-20.
7. Byer E, Ashman R, Toth LA. Electrocardiograms with large, upright T waves and long QT intervals. *Am Heart J*. 1947;33(6):796-806.
8. Burch GE, Meyers R, Abildskov JA. A new electrocardiographic pattern observed in cerebrovascular accidents. *Circulation*. 1954;9(5):719-23.
9. Dimant JA, Grob D. Electrocardiographic changes and myocardial damage in patients with acute cerebrovascular accidents. *Stroke*. 1977;8(4):448-55.
10. Nagaraja D, Gururaj G, Girish N, Panda S, Roy AK, Sarma GR, et al. Feasibility study of stroke surveillance: Data from Bangalore, India. *Indian J Med Res*. 2009;130:396-403.
11. Banerjee TK, Mukherjee CS, Sarkhel A. Stroke in the urban population of Calcutta- an epidemiological study. *Neuroepidemiology*. 2001;20:201-7.
12. Dalal PM, Malik S, Bhattacharjee M, Trivedi ND, Vairale J, Bhat P, et al. Population-based stroke survey in Mumbai, India: Incidence and 28-day case fatality. *Neuroepidemiology* 2008;31(4):254-61.
13. Santalucia P, Pezzella FR, Sessa M, Monaco S, Torgano G, Anticoli S, et al. Sex differences in clinical presentation, severity and outcome of stroke: results from a hospital-based registry. *Eur J Internal Med*. 2013;24(2):167-71.
14. Uma N, Chugh SK, Goel A, Gopal D. Echocardiography in patients with cerebral infarction. *J Ass Physicians India*. 1999;47(3):291-3.

**Cite this article as:** Devarapu C, Lokesh S. A prospective study of electrocardiographic and echocardiographic changes in patients with cerebrovascular accidents. *Int J Adv Med* 2018;5:891-4.