

Original Research Article

Ultrasound guided interscalene brachial plexus block via lower approach for upper limb surgeries

Roopal R. Garaniya*, Sheetal Shah, Noopur Prajapati

Department of Anesthesia, SCL Hospital, NHL Municipal Medical College, Ahmedabad, Gujarat, India

Received: 02 July 2018

Accepted: 27 July 2018

*Correspondence:

Dr. Roopal R. Garaniya,

E-mail: roopalrgaraniya@gmail.com

Copyright: © the author(s), publisher and licensee Medip Academy. This is an open-access article distributed under the terms of the Creative Commons Attribution Non-Commercial License, which permits unrestricted non-commercial use, distribution, and reproduction in any medium, provided the original work is properly cited.

ABSTRACT

Background: Brachial plexus block via interscalene approach is an excellent option for upper limb surgeries, but due to sparing of ulnar nerve (lower trunk, C8-T1) and its' complications, it is not so popular. To overcome this problem, interscalene block via lower approach has been tried which has more advantage in view of ulnar nerve blockage and also less complications. In addition, ultrasound provides reliability, ease, rapidity and also patient comfort during block procedure. This prospective study was performed to evaluate the anaesthetic effect of lower approach interscalene block with the help of ultrasound and peripheral nerve stimulator.

Methods: Ultrasound guided interscalene brachial plexus block via lower approach was given in randomly selected 30 patients, undergoing upper limb orthopaedic surgeries. After localisation of brachial plexus with ultrasound, the nerve roots were confirmed with the help of peripheral nerve stimulator, before injecting drug. At 5 and 15 min after block, all patients were assessed for the effect. Postoperatively they were assessed for any complication and also for their satisfaction level by Likert's scale.

Results: In territories of ulnar, radial and musculocutaneous nerve there was 100% effect while in median nerve territory 92.8% motor block was there. There was no need of analgesics during intra operative period in any patient and there were no major complications with this approach.

Conclusions: Ultrasound guided interscalene block via lower approach is an excellent alternative for upper limb surgeries over classical approach in view of ulnar nerve blockage without any major complication.

Keywords: Brachial plexus, Interscalene block, Ultrasound

INTRODUCTION

Peripheral nerve blocks are cost effective anaesthetic technique, used to provide good quality of anaesthesia and perioperative analgesia. Patient's satisfaction and a favourable postoperative recovery profile have resulted in increased popularity for regional technique. Brachial Plexus block is an easy and relatively safe procedure for upper limb surgeries. The anterior rami of C5-T1 spinal nerves form brachial plexus. Brachial plexus is located in interscalene region as nerve roots and trunks, in supraclavicular region as divisions, in the infra-clavicular (IC) region as cords and in the axillary region as

individual nerve branches. Interscalene, supraclavicular, infraclavicular and axillary approaches are used to block brachial plexus. Selection of the preferred approach is determined by the innervations of surgical site, risk of regional anaesthesia related complications as well as the preference and experience of the anaesthesiologist. In the classic interscalene approach, plexus is blocked in IS groove between the anterior and medial scalene muscles at C6 level located at the cricoid cartilage. But there is a higher chances of phrenic nerve palsy induced hemi diaphragmatic paralysis and more over this approach is not appropriate for some upper limb surgeries as lower trunk of plexus (C8-T1) and so ulnar nerve is spared.^{1,2}

There are some studies suggesting lower approach interscalene block in certain upper limb surgeries, to overcome the problems of classical approach, however there is limited studies regarding use of ultra sound to block brachial plexus at this level.^{2,3} Ultrasound provides an opportunity to visualize individual typical and atypical anatomy. Ultrasound has played a significant role in preventing complications due to real time imaging of needle advancement and local anaesthetic spread.³ In the present study authors have performed ultrasound-guided interscalene brachial plexus block (LISB) in the interscalene groove that is located at 2 cm above the clavicle (a lower approach), the level at which the root of the brachial plexus divides into trunks. In this method deposition of local anaesthetic is done in proximity to lower trunk of brachial plexus.

METHODS

Present study was conducted on 30 patients, aged 18 to 70 yrs of American Society of Anaesthesiologists (ASA) I and II posted for upper limb orthopaedic surgeries. The patients with coagulation disorders, any kind of neurological deficit or with surgical site infections were excluded. After getting informed and written consent, all patients were explained about the procedure risk, complications and objectives of the study. Non-invasive blood pressure manometer, pulse oximeter and electrocardiogram were applied to the patients after arrival in the operation room to monitor their vitals. Intravenous cannulation was done, and normal saline infusion was started at flow rate of 100 ml/h and oxygen was administered at the rate of 2-3 L/min via nasal prongs. After taking all sterile precautions, the site of block is prepared with betadine. Linear probe is placed on supraclavicular region where the subclavian artery and the brachial plexus can be easily identified. The transducer is then moved cephalad to locate the brachial plexus at the level where the individual trunks become better appreciated; with regard to surface landmarks. This is typically approximately 2 cm above the clavicle at the base of the neck. After identifying the brachial plexus and confirming the absence of blood vessels in the trajectory of the needle by colour doppler imaging, the operator advances the insulated needle 22G, 20 cm needle (stimuplex) slowly by in plane approach taking care to avoid any vascular structures and keeping the needle in view at all times. With the help of a nerve stimulator (Inmed) at 0.5mA, the contraction of each muscle (deltoid, arm, forearm or hand) is confirmed. Then an assistant aspirate and injects 1 ml of a local anaesthetic. The optimal needle location visualized as the spreads of the local anaesthetic as a hypoechoic area around the nerve roots. Once the ideal local anaesthetic spread is visualized, the assistant injects 10ml of 1.5% of xylorenaline and 10ml of 0.25% bupivacaine with continuous monitoring for early symptoms or signs of intravenous injection. At five and fifteen minutes after the injection of the local anaesthetic, authors confirmed the sensory block to loss of sensation to pin prick on the

territory of musculocutaneous nerve, median nerve, radial nerve, and ulnar nerve with a scale ranging from 0 (no sensation) to 10 (normal sensation). Authors also checked motor effect by assessing flexion of the elbow (musculocutaneous nerve), extension of the elbow and wrist (radial nerve), pronation of the arm and flexion of the wrist (median nerve), and flexion and opposition of the fourth and fifth fingers toward the thumb (ulnar nerve).

Patient's satisfaction level about block procedure was assessed by Likert's scale (Figure 1). Patients were asked to mark their satisfaction level about block procedure on 10 cm long slide ruler with bad, average, good and excellent written on it. The patient slides the cursor along the ruler until it reaches the level that represents their satisfaction level about block procedure.

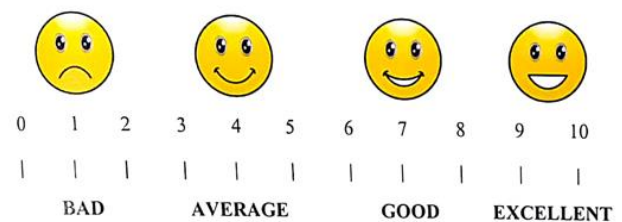


Figure 1: Likert's scale for patient's satisfaction level about block procedure.

RESULTS

Among the 30 patients, 12 were male and 18 were female. The patients' demographic data including age, body weight, gender and hemodynamic parameters are illustrated in Tables 1 and 2. Types of surgeries is illustrated in Table 3.

Table 1: Demographic data.

| Parametrs | Values |
|---------------------|-------------------|
| Age (Mean±SD) | 46.35±15.14 years |
| Sex ratio (Mean±SD) | 12:18 |
| Weight (Mean±SD) | 54.12 ± 5.80 kg |

Table 2: Hemodynamic parameters.

| | Before block | 15 min after block | P value |
|--------------------------|--------------|--------------------|---------|
| HR/min (Mean±SD) | 106.83±4.91 | 89.9±3.04 | 0.001 |
| MBP (mm of Hg) (Mean±SD) | 86.23±2.69 | 86.3±2.63 | 0.001 |

ANOVA (Analysis of Variance) test and Kruskal Wallis H test (equivalent to chi square test) was performed for the data evaluation. A value of $P < 0.05$ was considered as a statistically significant difference. There was

statistically significant difference in hemodynamic parameter in before and 15 min after block.

Table 3: Types of surgeries.

| Type of surgery | Number of patients |
|----------------------|--------------------|
| Shoulder arthroscopy | 6 |
| Proximal humerus | 8 |
| Ganglion excision | 3 |
| Elbow deformity | 2 |
| Radius ulna ORIF | 10 |
| Radius ulna ROI | 1 |

It suggests all type of surgeries related to upper limb from shoulder to radius ulna could be possible via this lower approach. As by this approach it is possible to block lower trunk of the brachial plexus (C8-T1, ulnar nerve).

Table 4: Quality of sensory block.

| | 5 min after block (Mean±SD) | 15 min after block (Mean±SD) |
|------------------------|--------------------------------|---------------------------------|
| Musculocutaneous nerve | 0.93±0.85 | 0.12±0.34 |
| Median nerve | 1.72±1.06 | 0.70±0.69 |
| Ulnar nerve | 2.74±1.03 | 1.1±0.65 |
| Radial nerve | 1.6±0.62 | 0.90±0.40 |

At 5 min, degree of sensory block was 0.93±0.85, 1.72±1.06, 2.74±1.03 and 1.6±0.62 in musculocutaneous, median, ulnar and radial nerve respectively on a scale of 10. And at 15 min, it was 0.12±0.34, 0.70±0.69, 1.1±0.65, and 0.90±0.40 in musculocutaneous, median, ulnar and radial nerve respectively on a scale of 10. Thus, on the basis of scale (0= no sensation, 10 = normal sensation) patients has adequate and satisfactory sensory block for surgeries.

Table 5: Quality of motor block (No. of patients).

| | 5 min after block | 15 min after block |
|------------------------|-------------------|--------------------|
| Musculocutaneous nerve | 28 | 30 |
| Median nerve | 22 | 28 |
| Ulnar nerve | 25 | 30 |
| Radial nerve | 27 | 30 |

After 15 min of block all patients could not flex or extend their elbow and could not do flexion and opposition of fourth and fifth fingers toward the thumb. It suggests complete motor block was there in all patients in territory of musculocutaneous, radial and ulnar nerves. 28 patients could not do pronation of the arm and flexion of the wrist, suggests motor block in median nerve territory while 2 patients had some pronation of arm but there was no any pain and difficulty during surgeries. Horner's syndrome was developed in 4 patients and hoarseness of voice occurred in 2 patients out of 30. There were no

major complications seen in any patient, 1 patient had vascular injury but was managed by external pressure only.

Table 6: Incidence of side effects and complications.

| Side effects | No. of patients |
|-------------------------------------|-----------------|
| Horner's syndrome | 4 |
| Ipsilateral diaphragmatic paralysis | 0 |
| Hoarseness of voice | 2 |
| Complications | |
| Pneumothorax | 0 |
| Vascular injuries | 1 |
| Nerve injuries | 0 |

Patient's satisfaction level about block procedure was excellent in 20 patients, good in 9 patients and average in 1 patient.

Table 7: Patient's satisfaction level about block procedure.

| Patient's satisfaction level | Number of patients |
|------------------------------|--------------------|
| Excellent | 20 |
| Good | 9 |
| Average | 1 |
| Bad | 0 |

DISCUSSION

Even though modern general anaesthesia is more certain, safer, faster and acceptable, regional anaesthesia has advantages like less interference with normal metabolic process and vital functions of body as compared to general anaesthesia. Brachial plexus block is an excellent option to anaesthetise the upper limb. Long lasting pain relief, a low incidence of nausea and vomiting and early hospital discharge are some of the clinical advantages. But brachial plexus block for all upper limb surgeries is not preferred because inconsistent block success remains one of the major limitations. It can lead to unplanned general anaesthesia which increases the risk and material cost and prolongs anaesthesia time. Another limitation is the potential for procedure related complications such as nerve injury and unintentional vascular or pleural puncture. The success of a peripheral nerve block is based on the ability to correctly identify the nerves involved in the surgery and to place an adequate dose of local anaesthetic drug around them, to achieve a complete impregnation of all nerves involved in the surgery. Ultrasound introduced into clinical practice to identify peripheral nerves offers the potential advantage of optimizing the spread of local anaesthetic solution around the nerves under real time images.³⁻⁶ Liu et al, studied ultrasound guided interscalene or supraclavicular block in ambulatory shoulder surgery and concluded that the use of ultrasound to guide the needle for interscalene or supraclavicular block was very effective and minimized the incidence of complications.⁷ Chan et al, also concluded in their study that real time ultrasound imaging

during supraclavicular brachial plexus blocks can facilitate nerve localization and needle placement and examine the pattern of local anesthetic spread.⁸

Jadon A et al, studied interscalene brachial plexus block for shoulder arthroscopic surgery, he observed 11/50 patients had Horner's syndrome and 10/50 patients had ipsilateral diaphragmatic paralysis as a side effect of interscalene block due to its anatomical position.¹ Ip V et al, studied lower scalene approach for elbow surgery, he introduced catheter between anterior and middle scalene muscle and local anesthetic drug was infused for 48 hrs, they concluded that lower interscalene approach is successful in providing analgesia for elbow and distal humerus surgery.² In present study also none of the patients has any side effects of lower approach interscalene block. Interscalene block is known to induce a temporary paralysis in the ipsilateral hemi diaphragm due to phrenic nerve palsy. The phrenic nerve is located within 2 mm of the brachial plexus of the cricoid cartilage and divides 3 mm per 1 cm as it descends caudally.^{1,3} Thus, it can be predicted that the incidence of phrenic nerve palsy induced hemi diaphragmatic paralysis can be reduced if interscalene block is performed more caudal to the C6 level than on the superior trunk.^{9,10} In present study, there were no signs of dyspnoea. In addition, LISB is known to reduce the damage to the dorsal scapular and long thoracic nerves, both of which split from the C5 nerve root.¹¹ Although authors did not assess whether any such damages occurred in the present study, none of the patients experienced any such problems.

Difference of hemodynamic parameters before and 15 min after block was statistically significant in this study, authors consider this difference as relief of pain and anxiety after block. In present study, after 15 mins, quality of sensory block is 0.12 ± 0.34 , 0.70 ± 0.69 , 1.1 ± 0.65 , 0.90 ± 0.40 in musculocutaneous, and median, ulnar and radial nerve respectively on a scale of 10. After 15 min, complete motor block was there in territory of musculocutaneous, ulnar and radial nerves, while 28 patients have motor block in median nerve territory. Side effects like Horner's syndrome in 4 patients and hoarseness of voice in 2 patients are noted but was not more distressing and patients were reassured for the same. There are no major complications like pneumothorax and nerve injuries seen in any of the patients. There are a few limitations to this study. Authors did not have a large number of patients to stamp it better and authors did not compare the procedure with other approaches.

CONCLUSION

The present study confirmed the achievement of an appropriate motor and sensory block in the upper

extremities, including the ulnar nerve, 15 minutes after lower approach interscalene block without any major complication.

Funding: No funding sources

Conflict of interest: None declared

Ethical approval: The study was approved by the Institutional Ethics Committee

REFERENCES

1. Jadon A, Dixit S, Kedia SK, Chakraborty S, Agrawal A, Sinha N. Interscalene brachial plexus block for shoulder arthroscopic surgery: Prospective randomised controlled study of effects of 0.5% ropivacaine and 0.5% ropivacaine with dexamethasone. *Indian J Anaes.* 2015;59(3):171-6.
2. Ip VH, Tsui BC. Lower interscalene approach for elbow surgery. *Canadian J Anesthesia.* 2013;60(6):600-1.
3. Park SK, Sung MH, Suh HJ, Choi YS. Ultrasound guided low approach interscalene brachial plexus block for upper limb surgery. *Korean J Pain.* 2016;29(1):18-22.
4. Soeding PF, Sha S, Royse CF, Marks P. A randomized trial of ultrasound-guided brachial plexus anaesthesia in upper limb surgery. *Anaesthesia and intensive care.* 2005;33(6):719.
5. Koscielniak-Nielsen ZJ. Ultrasound-guided peripheral nerve blocks: what are the benefits?. *Acta Anaesthesiolog Scand.* 2008;52(6):727-37.
6. Williams SR, Chouinard P, Arcand G, Harris P, Ruel M, Boudreault D, et al. Ultrasound guidance speeds execution and improves the quality of supraclavicular block. *Anesthesia Analgesia.* 2003;97(5):1518-23.
7. Liu SS, Gordon MA, Shaw PM, Wilfred S, Shetty T, YaDeau JT. A prospective clinical registry of ultrasound-guided regional anesthesia for ambulatory shoulder surgery. *Anesthesia Analgesia.* 2010;111(3):617-23.
8. Chan VW, Perlas A, Rawson R, Odukoya O. Ultrasound-guided supraclavicular brachial plexus block. *Anesthesia Analgesia.* 2003;97(5):1514-7.
9. Nadeau MJ, Lévesque S, Dion N. Ultrasound-guided regional anesthesia for upper limb surgery. *Canad J Anesthesia.* 2013;60(3):304-20.
10. Kessler J, Schafhalter-Zoppoth I, Gray AT. An ultrasound study of the phrenic nerve in the posterior cervical triangle: implications for the interscalene brachial plexus block. *Regional Anesthesia Pain Med.* 2008;33(6):545-50.
11. Laurent DB, Chan V, Chin KJ. Refining the ultrasound-guided interscalene brachial plexus block: the superior trunk approach. *Canadian J Anes.* 2014;61(12):1098-102.

Cite this article as: Garaniya RR, Shah S, Prajapati N. Ultrasound guided interscalene brachial plexus block via lower approach for upper limb surgeries. *Int J Adv Med* 2018;5:1304-7.