

## Original Research Article

# Branching pattern of sinoatrial and atrioventricular nodal arteries in patients undergoing cardiac catheterization in a tertiary care hospital

Divyaprakash M.<sup>1\*</sup>, Suma M. P.<sup>2</sup>, Jagadish H. R.<sup>1</sup>, Girish P. G.<sup>1</sup>

<sup>1</sup>Department of Cardiology, PMSSY-SSH, BMCRI, Bangalore, Karnataka, India

<sup>2</sup>Department of Anatomy, Oxford Medical College and Research Institute, Bangalore, Karnataka, India

**Received:** 01 August 2016

**Accepted:** 04 August 2016

### \*Correspondence:

Dr. Divyaprakash M,

E-mail: [drdivyaprakashm@gmail.com](mailto:drdivyaprakashm@gmail.com)

**Copyright:** © the author(s), publisher and licensee Medip Academy. This is an open-access article distributed under the terms of the Creative Commons Attribution Non-Commercial License, which permits unrestricted non-commercial use, distribution, and reproduction in any medium, provided the original work is properly cited.

### ABSTRACT

**Background:** The (SA) sinoatrial node and (AV) atrioventricular nodal blood supply is highly variable and recording of the anatomic variants of the arterial blood supply to the SA node and AN node will help to overcome potential complications following ablation procedures or in valvular surgeries. The objectives were to study the blood supply of the conducting system and its relation with the coronary artery dominance and to find the origins of the major atrial arteries in patients undergoing coronary angiography.

**Methods:** The study included 300 consecutive patients (104 females, 196 males) admitted for diagnostic coronary angiography at PMSSY, superspeciality hospital, BMC and RI, Bangalore, India. The coronary angiography was done in a conventional manner without any specific views for atrial arteries. The origins of sinoatrial and atrioventricular nodal arteries and its relation with the arterial dominance were recorded.

**Results:** The RCA is dominant in 77.20%, LCX is dominant in 18.43% of patients and codominant in 4.37% of the patients. The SA nodal artery arises from the RCA in 57.20% of the patients, by the circumflex branch of the LCA in 40.14% and by both coronary arteries in 2.66% of patients. The AV nodal artery was also commonly arises from the RCA (78.22%) than by the Cx branch of the LCA (18.66%).

**Conclusions:** The data from our study may help the cardiac surgeons, cardiologists and electrophysiologists in their day today practice.

**Keywords:** Atrioventricular nodal artery, Circumflex artery, LCA, RCA, Sinoatrial nodal artery

### INTRODUCTION

The arterial blood supply of the sinoatrial (SA) node and Atrioventricular (AV) node is very much variable and was the topic of anatomic, histologic, and radiologic research for many years. The recording of the anatomic variants of the arterial blood supply to the SA node and AN node will help to overcome potential complications following ablation procedures or in valvular surgeries.<sup>1</sup>

Anterior atrial branches of the RCA are arranged in anterior, lateral and posterior groups to supply the corresponding surfaces of the right atrium one important atrial branch of the RCA is the SA nodal artery which is usually the second branch of the RCA and supplies the SA node in 55% of the cases, in the remaining 45% ,the SA node is supplied by a branch of the Cx artery, in some cases it may originate from the trunk of left coronary or aorta or left bronchial artery or kugels artery.<sup>2-5</sup>

The arterial supply of the AV node arose in 90% of the hearts from the RCA in the posterior atrioventricular sulcus at a point just beyond the origin of the posterior interventricular artery. In 10% AV node arose from the terminal part of the Cx at the crux of the heart.<sup>2</sup> The AV nodal artery is associated with coronary dominance, where the vessel that gives rise to PDA also gives rise to the AV node.

The main aim of the present study was to identify the origins of sinoatrial and atrioventricular nodal arteries and its relation with the arterial dominance were recorded

## METHODS

This case control study was conducted at Super Speciality hospital PMSSY, BMC and RI, Bangalore, India during 2013 to 2015. The consecutive patients who underwent Diagnostic coronary angiogram were studied from the CAG database. The opinion of the two senior Cardiologist regarding the characteristics of the coronary anatomy were taken.

Popma JJ classification regarding the dominant circulation was used in this study a) right dominant circulation, the posterior descending artery (PDA) and at least one posterolateral branch (PLB) originate from RCA.<sup>6</sup> b) In a left dominant circulation, the PDA and all of the PLBs originate from the LCA and c) In a codominant circulation, the PDA originate from the RCA and all of the PLBs originate from the LCA.

No special views were taken during the Coronary angiogram in our study. The preferred views were LAO of the RCA and the RAO of the LCA. The SA node when arising from the RCA can be recognized as its second branch after the conus artery that runs dorsally and extends over the upper portion of the atrial septum to terminate in the region of the ostium of the SVC after arching laterally in front of the latter, when the SAna arise from Cx branch of the LCA it passes to the right over the left auricle and reaches the SA node after encircling the SVC.

The AVna is usually seen as a branch of the dominant artery. The artery arises from the crux, and is said to be a branch of the first posterior interventricular artery. It is consistent with the inverted U turn that is seen at the crux in the case of the RCA and a smooth curve seen at the crux in the case of the Cx branch of the LCA.

The following parameters were chosen for the study

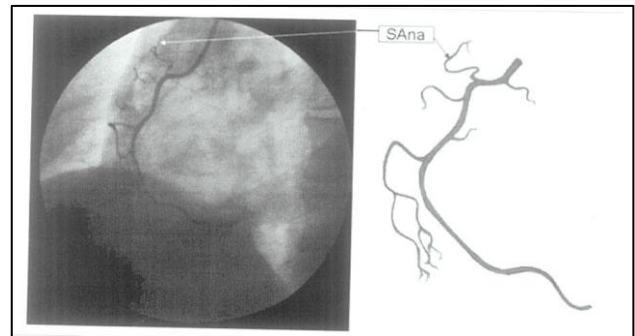
- Coronary dominance
- Origins of the Major atrial arteries
- Correlating coronary dominance with the origin of the atrial arteries.

These findings were then analyzed.

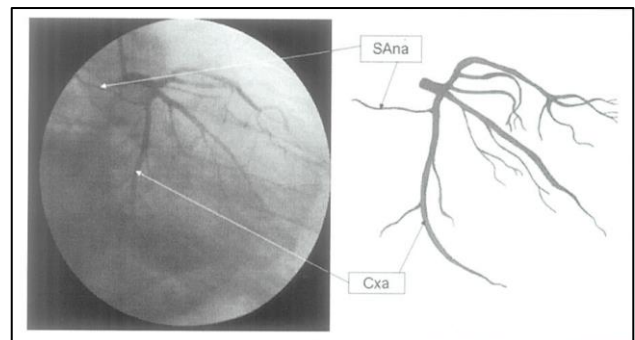
Out of the 300 patients, 200 patients (120 males, 80 females) were included in the present study. Patients with significant ostioproximal coronary lesion in RCA and LCX with TIMI 0-1 antegrade flow were excluded.

## RESULTS

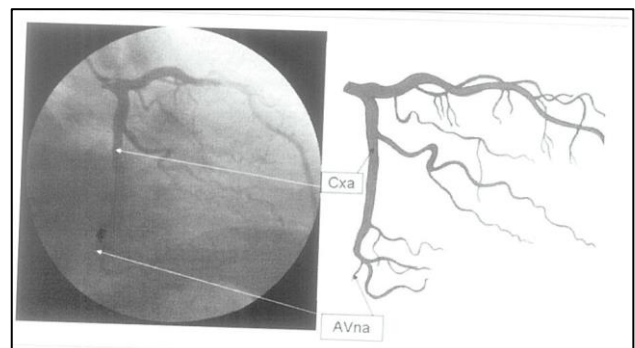
In our study 154 patients had a right dominance, 36 had a left dominance and 10 had co-dominance. As expected the SA node was supplied by the RCA more frequently than by the Cx branch of LCA, and in nearly 3% of the cases this node is supplied by both atrial arteries.



**Figure 1: RCA in the LAO view showing the sinoatrial nodal branch.**



**Figure 2: LCA in the RAO view showing the sinoatrial nodal branch from the circumflex artery.**



**Figure 3: LCA in RAO view showing the atrioventricular artery from the circumflex artery.**

The AV node was supplied by the RCA more frequently than the Cx branch of the LCA. The AVna was a branch

of the dominant artery in 72.22% of the cases in comparison to the SA nodal artery which was a branch of dominant artery in only 33.42% of the cases.

## DISCUSSION

The anatomy of the major atrial arteries is very important in cardiac surgeries like atriectomies, surgical repair of valvular disorders and congenital malformations which expose the SA node. The anatomy of SA node if arises from RCA is highly variable, whereas SA node from the left Cx is usually uniform. Kyriakidis et al studied the coronary anatomy in 309 patients undergoing CAG, the sinus nodal arteries, majority arose proximally 1 to 3 cm from the aortic ostium passed across the anteromedial wall of the right atrium and penetrated the atrial septum below the interatrial bundle, of the SA node arose from the left Cx, it arose from the proximal portion of the left Cx and coursed through the anterior branch of the interatrial muscle bundle and then through the bundle itself.<sup>7</sup> Berdajs et al studied the SA node by CAG showed that the SA node crosses the superior posterior border of the interatrial septum in 54% of the cases, which carries the risk of damage during the superior transseptal approach to the mitral valve.<sup>8</sup> Berdajs et al studied the AV node by CAG, reported that SA node originated from the RCA in 73% of the cases and from the LCA in 27% of the cases. The left AV node was closely related to the mitral valve attachment, especially at the area of the left proximal part of the posterior leaflet. With this data and with the available literature, they reported that there is a high risk of intraoperative damage to the left AV node during manipulation of the mitral valve annulus fibrosus.<sup>9</sup>

In our study RCA is dominant in 77.20%, LCA in 18.43% of the patients and co-dominancy found in 4.37% of the patients. The SA node arises from RCA in 57.20%, LCx in 40.14% and from both in 2.66% of the patients, which is comparable to the study conducted in angiography patients by Ramanathan L et al.<sup>10</sup> The AV node arises from RCA in 78.22%, LCx in 18.66% of the patients which is comparable to the data from the study conducted by Futami C et al.<sup>11</sup> Further studies are required in larger population and across different geographical regions for better understanding of the major atrial branches of the coronary arteries.

## CONCLUSION

The present study showed that, the SA node was originated commonly from the RCA and LCA, only in 2.66% of patients from both coronary arteries. The AV node arises more commonly from the RCA (78.22) than from the LCA (18.66). The study data may help cardiac surgeons

mainly during valvular surgeries and cardiologists in radiofrequency ablation procedure.

## ACKNOWLEDGEMENTS

Authors would like to thank Director cum Dean, and special officer PMSSY, BMCRI for the support in conducting this study. Authors thank all his staff and colleagues for their necessary inputs.

*Funding: No funding sources*

*Conflict of interest: None declared*

*Ethical approval: The study was approved by the institutional ethics committee*

## REFERENCES

1. Abulin G, Nieponice A. New findings of the origin of the blood supply to the atrioventricular node. Clinical and surgical significance. Tex Heart Inst J. 1998;25:113-7.
2. James TN, Burch GE. The atrial coronary arteries in man. Circulation. 1958;17:90-8.
3. April WE. Clinical anatomy. 3<sup>rd</sup> edition. Baltimore:Williams and Wilkins;1997:275-7.
4. Krupa U. The sinoatrial nodal artery in the human heart. Folia Morphol. 1993;52:29-37.
5. Sow MI, Ndoeye JM. The artery of the sinoatrial node: anatomic considerations based on 45 injection dissections of the heart. Surg Radiol Anat. 1996;18:103-9.
6. Pompa JJ. Coronary arteriography, In:Bonow RO, Mann DL, Zipes DP, Libby P, Braunwald E, eds. Braunwald's heart disease. A Textbook of Cardiovascular Medicine. 9<sup>th</sup> edition. Philadelphia:Saunders. 2011:406-440.
7. Kyriakidis M, Vyssoulis G, Barbetsas J, Toutouzias P. A clinical angiographic study of the arterial blood supply to the sinus node. Chest. 1988;94:1054-7.
8. Berdajs D, Patonay L, Turina MI. The clinical anatomy of the sinus node artery. Ann Thorac Surg. 2003;76:732-5.
9. Berdajs D, Kunzli A, Shurr U, Zund G, Turina MI, Genonni M. Clinical anatomy of the atrioventricular node artery. J Heart Valve Dis. 2006;15:225-9.
10. Ramanathan L. Origin of the SA and AV nodal arteries in South Indians:an angiographic study. Arg Bras Cardiol.2009;92(5):314-9.
11. Futami C, Tanuma K, Tanuma Y, Saito T. The arterial blood supply of the conducting system in normal human hearts. Surg Radiol Anat. 2003;25:42-9.

**Cite this article as:** Divyaprakash M, Suma MP, Jagadish HR, Girish PG. Branching pattern of sinoatrial and atrioventricular nodal arteries in patients undergoing cardiac catheterization in a tertiary care hospital. Int J Adv Med 2016;3:835-7.