

Original Research Article

Mucormycosis: the clinical spectrum

Archana Bhat*

Department of Medicine, Muller Medical College, Kankanady, Mangalore, Karnataka, India

Received: 20 October 2018

Revised: 24 October 2018

Accepted: 29 October 2018

*Correspondence:

Dr. Archana Bhat,

E-mail: archanaacharya24@gmail.com

Copyright: © the author(s), publisher and licensee Medip Academy. This is an open-access article distributed under the terms of the Creative Commons Attribution Non-Commercial License, which permits unrestricted non-commercial use, distribution, and reproduction in any medium, provided the original work is properly cited.

ABSTRACT

Background: Mucormycosis is a rare opportunistic fungal infection typically affecting diabetic or immunosuppressed patients. In most of the cases, infection is caused by inhalation of fungal spores. The aim of the study is to assess the different modes of presentation, risk factors management and prognosis of patients with mucormycosis.

Methods: It is a retrospective study conducted in Father Muller medical college hospital between January 2016 to October 2017 and included all patients hospitalized for mucormycosis confirmed by mycological and /or histological findings. This study was approved by the institutional research and ethics committee. All case records were identified from in patient MRD with the diagnosis of mucormycosis over the last one year. For each case taken, the clinical information was recorded from case sheet

Results: Out of the 7 cases studied 5 (71.4%) had rhinoorbital involvement 28.6% had pulmonary involvement with hemoptysis being the primary symptom. The mean age of the affected population was 55.7 years. Uncontrolled diabetes mellitus was the most common predisposing factor as seen in 71.4% cases with mean HbA1c levels 13. The mean ESR in present study was 79. There was increased WBC count in all the cases studied with neutrophilic predominance. Urine ketones was positive (++) in all the cases of diabetes with rhinoorbital involvement.

Conclusions: Uncontrolled diabetes mellitus is a predisposing factor for mucormycosis. Elevated ESR was noted in all the cases.

Keywords: Clinical profile, Diabetes, Mucormycosis

INTRODUCTION

Mucormycosis is an opportunistic fungal infection caused by saprophytic fungal elements commonly found in soil, decaying materials and food. Respiratory route is the most common mode of entry to the body. The fungi have filamentous nonseptate hyphae with right angled branching.¹ These fungal elements are widely distributed in nature and are commonly found in decaying matter. Though mucormycosis can affect any part of the body it has predilection for certain organ systems. It can present as follows: disseminated, cutaneous, rhino- cerebral,

pulmonary, and gastrointestinal or central nervous system involvement. The predisposing disease condition determines the predilection for one of these presentations. Diabetic patients most often develop rhino- cerebral mucormycosis. The host response to mucorales is predominantly by neutrophils.² Fungal growth and proliferation is promoted by certain metabolic states like hyperglycemia and acidosis.³ The increased release of iron from ferritin which occurs because of acidosis caused enhanced fungal and hyphae growth.⁴ Mucormycosis is usually not encountered commonly in day to day practice and hence a high index of suspicion is needed to avoid delay in diagnosis and treatment

Management of mucormycosis still represents a big challenge and is based on different strategies which envisage a rapid diagnosis, removal or reduction of risk factors, rapid aggressive antifungal therapy, with or without surgical treatment.⁵

Symptoms and signs of rhinocerebral mucormycosis include: fever, headache, proptosis, dark nasal eschar, redness of skin overlying sinuses, sinus pain or congestion. Symptoms of lung pulmonary mucormycosis include: cough, hemoptysis, dyspnoea, fever. Symptoms of gastrointestinal mucormycosis include: Abdominal pain, hemoptysis, and diarrhea. Symptoms of renal mucormycosis include: flank pain and fever.

The aim of the study is to assess the different modes of presentation, risk factors management and prognosis of patients with mucormycosis.

METHODS

It is a retrospective study conducted in Fr Muller medical college hospital between January 2016 to October 2017 and included all patients hospitalized for mucormycosis confirmed by mycological and /or histological findings. The study was approved by the institutional research and ethics committee. All case records were identified from in patient MRD with the diagnosis of mucormycosis over the last one year. For each case taken, the clinical information was recorded from case sheet.

Inclusion criteria

All cases admitted to author's hospital between January 2016 to October 2017 with histological /mycological diagnosis of mucormycosis affecting any organ.

Exclusion criteria

- All cases diagnosed with mucormycosis with any hematological malignancy
- Post chemotherapy status
- Post radiotherapy status or any solid organ carcinoma
- Post organ transplant recipients.

For each patient identified from case records clinical information was recorded as per preformed table which includes name, age, sex, clinical features, premorbid illness if any, involved sites, mode of diagnosis, radiology, predisposing risk factors, predisposing local conditions, treatment given, surgical debridement if any and outcome. Mucormycosis was diagnosed by mycological / histopathological findings and fungal isolation. Laboratory - based diagnostics included conventional procedures like fungal culture, direct fungal stain and histopathology. Computerized tomography of the involved site was done in all patients to know the extent of the lesion.

Statistical analysis

Qualitative data like gender, morbidities, and outcome will be analysed as frequency and percentages. Quantitative data like age, laboratory values and duration of stay will be presented as mean and standard deviation with 95% confidence intervals

RESULTS

During the eighteen months period total of 7 cases were identified with mucormycosis. The patient characteristics are shown in Table 1. The mean age of presentation was 55.7 years.

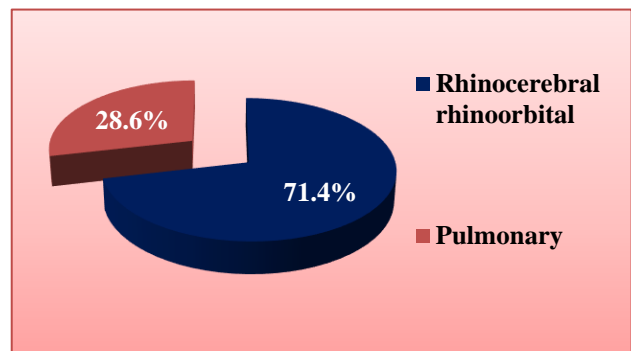


Figure 1: Site of involvement.

The study group consisted of 4 male patients and 3 female patients aged between 45- 65 years. The most common clinical presentation was facial pain, headache, nasal obstruction and swelling. Hemoptysis was the main clinical presentation in patients with pulmonary mucormycosis (100%). The majority of the patients were immunocomprised having diabetes mellitus (71.4%) while the remaining one patient had local chronic sinusitis (14.2%) while one more patient was immunocompetent (14.2%).

Mucormycosis occurs sporadically in patients with uncontrolled diabetes or previous trauma and may involve any areas of the body. The main site of involvement in this case series was rhinocerebral/rhinoorbital region (71.4%) as depicted in Figure 1. Pulmonary involvement was seen in 28.6% cases.

Hemoptysis was the initial presentation in pulmonary mucormycosis while hemifacial pain with nasal obstruction seen in the rest of the cases.

All the patients had neutrophilic leukocytosis in the complete blood picture with elevated ESR. The mean ESR in this study was 79.

The main risk factor in all these cases was uncontrolled diabetes mellitus (71.4%). The mean HbA1c levels was 13. The comorbid illness seen in the patients are shown in

Table 2. The other comorbid illness included chronic kidney disease, hypertension, rheumatoid arthritis, HbsAg positive status with high viral load, old

pulmonary tuberculosis and chronic local sinusitis. One patient was immunocompetent with no co morbid illness.

Table 1: Patient characteristics.

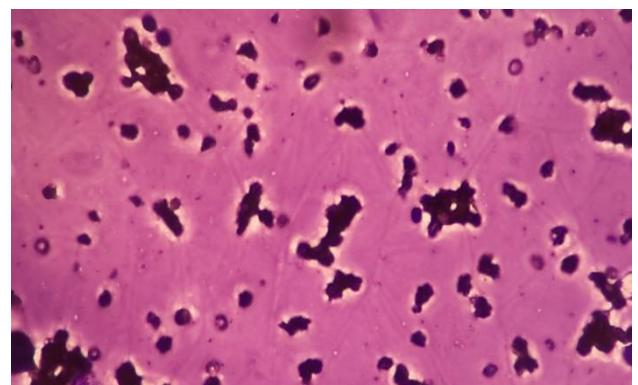
Age / sex	Clinical symptoms	Radiology	Underlying past disease	Predisposition local conditions	Treatment given
53y/ female	Ulcer over right maxillary area	Sphenoidal sinuses are both opacified by an hyperdense lesion	DM on insulin	Chronic osteomyelitis of right maxilla	Surgery + itraconazole
55y/ Male	Hemoptysis chest pain	Spiculated hyperdense peripherally enhancing lesion at apico- posterior segment of left upper lobe.	DM HbsAg+ve with high viral load old pulmonary TB IHD	-	Inj. amphotericin B
63y / male	Hemoptysis	Mass in upper lobe on bronchoscopy	DM on insulin	Nil	Died before initiation of treatment
65y/ male	Pain difficulty in opening mouth, left cheek pain swelling	Soft tissue in left maxillary sinus left sphenoidal sinus with lesion on hard palate.	DM on insulin HTN CKD Rheumatoid arthritis	Nil	Surgery + intraconazole
47y /F	Headache nasal obstruction	Mucosal thickening in right maxillary sinus with hyperdensity within.	Nil	Chronic maxillary sinusitis	Surgery + Inj. amphotericin B
60y/F	Painful lesion moves the lower eyelid of right eye	Hyperdense lesion on the inferomedial aspect of right extra conal space	-	Right endonasal surgery done yeambach	Surgery + Inj. amphoterecin B
45y / m	Headache right facial pain (+)	Mucosal thickening in right maxillary sinus with hyperdensity noted within	DM HTN	-	Inj. amphotericin B

Table 2: Risk factor analysis.

Co-morbidities	Patient characteristic count
DM	1
DM, HTN	1
DM, HTN, CKD	1
DM, HTN, CKD, RA	1
DM, HBSAG positive with high viral load, old pulmonary TB, IHD	1
Chronic local sinusitis / osteomyelitis	1
NIL	1

Urine ketones was positive in all diabetic patients at the time of initial presentation of rhinoorbital mucormycosis. In diabetic ketoacidotic patient, there is high incidence of mucormycosis caused by *Rhizopus oryzae*, also known as

Rhizopus arrhizus, because they produce the enzyme ketoreductase, which allows them to utilize the patients' ketone bodies.



Presence of broad aseptate fungal hyphae, with a right-angle branching varying from 45 to 90

Figure 2: Histological analysis.

All the cases underwent radiological imaging for the diagnosis with surgical debridement done in 5 cases. Fungal mycology was positive in all the cases. Two cases received conventional injection amphoterecin B at dose of 1mg/kg alone for two weeks without surgical intervention while rest 4 cases received surgical debridement followed by itraconazole. One case of pulmonary mucormycosis died just before the initiation of treatment.

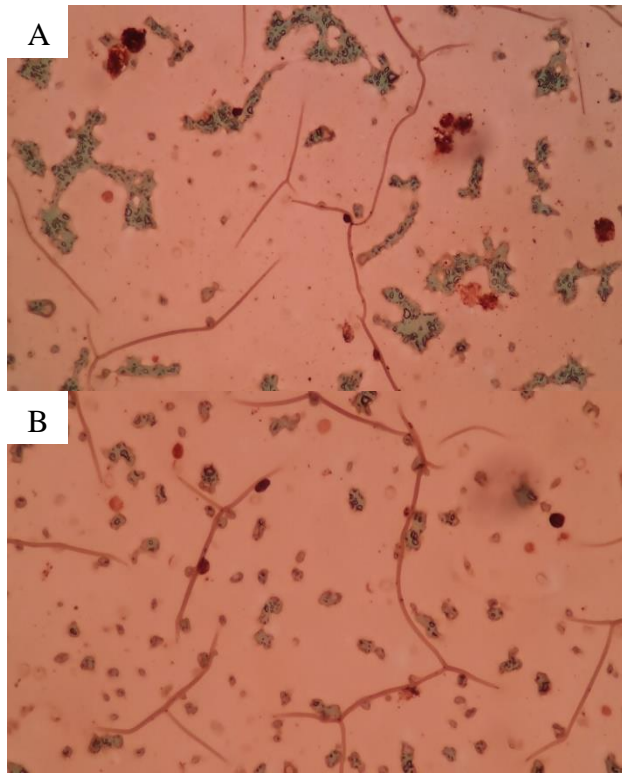


Figure 3: (A and B): Grocott methenamine-silver staining confirmed the presence of a fungal infection of the order Mucorales. Specimen isolated from patient 2.

All patients underwent biopsies. Broad, non-septate, branching hyphae were seen in all cases in KOH smears and in all 7 cases histologic specimens showing tissue invasion. Biopsy showed angioinvasive fungal infection suggestive of mucormycosis as shown in Figure 2, Figure 3 (A) and (B). Cultures were positive for Mucorales in 02 cases, all of them showing rhizoids and collapsed columellae compatible with *Rhizopus* species. Mixed fungal infection was seen in one patient (Mucormycosis + candidal infection).

DISCUSSION

The mean age group in present study was 55.7. It was consistent with the study published by Gupta et al which had a mean age of 50 years.⁶ Mucormycosis has shown an equal sex distribution. But in this there is slightly male predominance with ratio of male: female is 1.3:1 The study done by Talmi YP et al, had also shown male predominance.⁷

The most common clinical presentation was rhinoorbital mucormycosis. Inhalation appears to be the most common route of infection with subsequent involvement of respiratory tract, resulting in both rhino-orbito-cerebral and pulmonary forms, the literature review has shown that the most common clinical presentation of mucormycosis turned out to be rhinoorbital mucormycosis.⁸ So author have hypothesized that a chronic local insult, such as a chronic sinusitis, might have acted as a predisposing factor for a possible development of mucor infection in immunocompetent/ otherwise healthy individuals.

This speculation seems to be supported by the evidence that a chronic sinusitis might be caused by an alteration of first-line barrier defense of upper airway (sinus mucosa) caused by an impairment of mucociliary clearance. An impairment or loss of immune defense at the sinus mucosa would render individuals more vulnerable to fungal colonization.

The most common predisposing factor was uncontrolled diabetes mellitus as also shown by Chakrabarti A et al, in his study.⁹ The mean ESR in present study was 79. A study done by Ghafur et al, showed the mean ESR was elevated significantly in their study 118 and also had predominant neutrophilic leucocytosis in their case series.¹⁰ Urinary ketones positive also favour mucormycosis as shown in a study done by Baldin C et al, Thus, the unique interactions of GRP78 and CotH proteins and their enhanced expression under hyperglycemia and ketoacidosis explain the specific susceptibility of DKA patients to mucormycosis.¹¹ Hyperglycemia causes reduction in chemotaxis and phagocytic efficiency.

One patient died in present study even before initiation of treatment due to massive hemoptysis. Pulmonary mucormycosis has a higher mortality rate shown in a study done by He R et al.¹²

CONCLUSION

Mucormycosis is a rare opportunistic fungal infection with rapidly progressive and fulminant course with often fatal outcome. Uncontrolled diabetes mellitus is a strong predisposing factor for mucormycosis. Elevated ESR with leukocytosis may be seen in most patients suspicious of mucormycosis.

Funding: No funding sources

Conflict of interest: None declared

Ethical approval: The study was approved by the Institutional Ethics Committee

REFERENCES

1. Torres-Narbona M, Guinea J, Munoz P, Bouza E. Zygomycetes and zygomycosis in the new era of

- antifungal therapies. *Spanish J Chemotherapy*. 2007 Dec;20(4):375-86.
2. Chayakulkeeree M, Ghannoum MA, Perfect JR. Zygomycosis: the re-emerging fungal infection. *European Journal of Clinical Microbiology and Infectious Diseases*. 2006 Apr 1;25(4):215-29.
3. Prabhu RM, Patel R. Mucormycosis and entomophthoromycosis: a review of the clinical manifestations, diagnosis and treatment. *Clin Microbiol Infection*. 2004 Jan 1;10:31-47.
4. Maschmeyer G. The changing epidemiology of invasive fungal infections: new threats. *Int J Antimicrobial Agents*. 2006 Jun 1;27:3-6.
5. Mignogna MD, Fortuna G, Leuci S, Adamo D, Ruoppo E, Siano M, et al. Mucormycosis in immunocompetent patients: a case-series of patients with maxillary sinus involvement and a critical review of the literature. *Int J Infectious Dis*. 2011 Aug 1;15(8):e533-40.
6. Gupta SK. Clinical profile of mucormycosis: a descriptive analyses. *Int J Sci Stud*. 2017;5(6):160-3.
7. Talmi YP, Goldschmied-Reouven A, Bakon M, Barshack I, Wolf M, Horowitz Z, et al. Rhino-orbital and rhino-orbito-cerebral mucormycosis. *Otolaryngology-Head Neck Surg*. 2002 Jul;127(1):22-31.
8. Nezafati S, Kazemi A, Asgari K, Bahrami A, Naghili B, Yazdani J. Rhinocerebral mucormycosis, risk factors and the type of oral manifestations in patients referred to a university hospital in Tabriz, Iran 2007 to 2017. *Mycoses*. 2018 Jun 13.
9. Chakrabarti A, Chatterjee SS, Das A, Panda N, Shivaprakash MR, Kaur A, et al. Invasive zygomycosis in India: experience in a tertiary care hospital. *Postgraduate Med J*. 2009 Nov 1;85(1009):573-81.
10. Ghafur A, Shareek PS, Senthur NP, Vidyalakshmi PR, Ramasubramanian V, Parameswaran A, et al. Mucormycosis in patients without cancer: a case series from a tertiary care hospital in South India. *J Association Physicians India*. 2013 May;61:11.
11. Baldin C, Ibrahim AS. Molecular mechanisms of mucormycosis-The bitter and the sweet. *PLoS Pathogens*. 2017 Aug 3;13(8):e1006408.
12. He R, Hu C, Tang Y, Yang H, Cao L, Niu R. Report of 12 cases with tracheobronchial mucormycosis and a review. *Clin Respiratory J*. 2018 Apr;12(4):1651-60.

Cite this article as: Bhat A. Mucormycosis: the clinical spectrum. *Int J Adv Med* 2018;5:1364-8.