

Case Report

A case of herpes zoster oticus with multiple cranial nerve palsy

Debananda Sahoo, Shubhransu Patro*, Pankaj K. Khora, Udaya N. Panda

Department of General Medicine, Kalinga Institute of Medical Sciences, K.I.I.T University, Bhubaneswar, Odisha, India

Received: 31 May 2016

Accepted: 02 July 2016

*Correspondence:

Dr. Shubhransu Patro,

E-mail: shubhransu@rediffmail.com

Copyright: © the author(s), publisher and licensee Medip Academy. This is an open-access article distributed under the terms of the Creative Commons Attribution Non-Commercial License, which permits unrestricted non-commercial use, distribution, and reproduction in any medium, provided the original work is properly cited.

ABSTRACT

Herpes zoster oticus (HZO) otherwise called as Ramsay Hunt syndrome is a rare complication due to reactivation of the herpes zoster virus in the geniculate ganglion of facial nerve presenting with vesicular eruptions over external ear along with severe otalgia and LMN type of 7th cranial nerve palsy. This syndrome often misdiagnosed because of absence of these symptoms. About 12% of all peripheral facial nerve palsies are caused by varicella zoster virus. The occurrence rate of associated cranial polyneuropathy has been reported to be 1.8-3.2% and cranial nerves VII, VIII, IX and X are the ones most commonly affected. Here, we present a case of Ramsay Hunt syndrome with cranial polyneuropathy. The patient was treated with antiviral and oral steroid and the symptoms were improved.

Keywords: Ramsay Hunt syndrome, Geniculate ganglion, Varicella zoster virus, Otolgia, Acyclovir

INTRODUCTION

Varicella zoster virus (VZV) infection of the head and neck region may present with various symptoms. We present a case of VZV infection of the external ear (cranial nerve V), pharynx and larynx with neuropathy of four ipsilateral lower cranial nerves (VII, IX, X, XII).

Primary infection to *Varicella zoster virus* (VZV), a DNA virus of the Herpesviridae family, produces the typical picture of chickenpox. After primo-infection occurs generally during childhood, the virus remains quiescent. The most frequent sites of latency of VZV are dorsal root ganglia of the spinal nerves, but any autonomic ganglion or cranial nerve can be involved. Reactivation of this virus during adulthood can produce zoster (shingles), which presents with painful vesicles following a skin segmental distribution.¹

Involvement of the ophthalmic division of the trigeminal nerve (Herpes zoster ophthalmicus) and involvement of the facial nerve (Herpes zoster oticus) are the two most widely known clinical presentations regarding cranial

nerves. Involvement of other cranial nerves by VZV is more rarely reported. We present a case of VZV infection of the external ear of left side (cranial nerve V), pharynx and larynx with neuropathy of four ipsilateral lower cranial nerves (VII, IX, X, XII).

CASE REPORT

In March 2016, a 54 year old male was presented with chief complain of dragging of mouth to right side since last 5 days, difficulty in deglutition with regurgitation of food through nostril associated with left sided ear pain and hoarseness of voice since last 3 days. There was no hearing loss or dizziness. There was associated dribbling of saliva from left side of mouth.

On physical examination, pt. was in a stable clinical condition with intact sensorium. Multiple vesicular eruptions with crusts were present on the left ear pinna (Figure 1 A, B, C). Along with there was ipsilateral (left side) paralysis of the soft palate and deviation of tongue to left on protrusion. Palatal reflex and pharyngeal reflex were absent on left side and preserved on right side.

There was infranuclear type of palsy of left 7th cranial nerve along with Bell's eye phenomenon (Figure 2). Tympanic membrane was intact with normal oral cavity and oropharynx. Extra ocular movements were intact and the pupils were normal in size and reacted to light bilaterally.

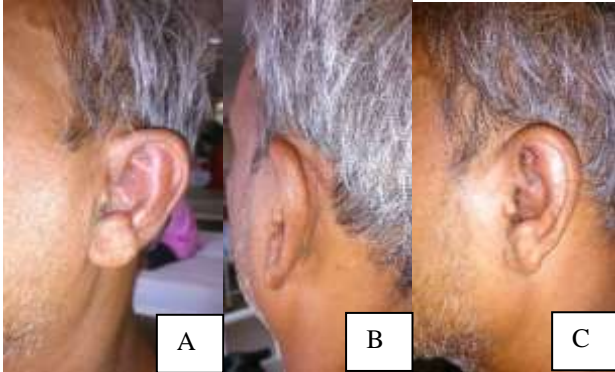

Figure 1(A, B, C): Multiple vesicular eruptions with crusts on the left pinna.

Other systemic examination including the examination of neurological system reveals no abnormality except loss of taste sensation of anterior 2/3rd of tongue of left side. The patient was admitted and investigated. All blood reports like CBC, FBS, PPBS, LFT, and RFT were within normal range. Endoscopic examination showed there was fixation of left vocal cord in para median position irrespective of phonation and breathing (Figure 3A, B, C). MRI scan of brain revealed no abnormality (Figure 4). CSF sample was positive by PCR and showed amplification of VZV DNA.

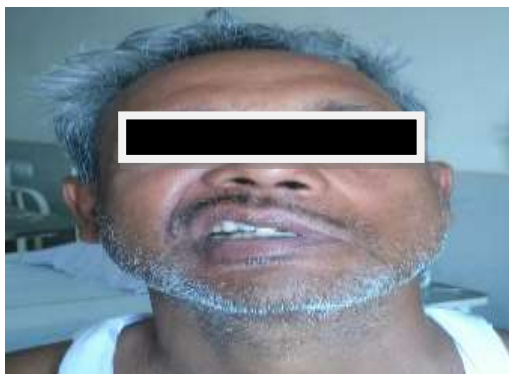

Figure 2: Infranuclear type of palsy of left 7th cranial nerve.

During hospital stay, patient was treated with parenteral acyclovir 500 mg 3 times a day for 7 days and a short course of oral prednisolone 60 mg per day for 10 days along with other supportive medications and care like physiotherapy with an impression of multiple lower cranial nerve involvement by herpes zoster virus. After 5 days of admission, the skin lesions over the auricle were healed but the paretic symptoms were persisted. On the 10th day of admission, he was discharged. After 2 weeks,

when the patient revisited, the skin lesions were completely healed and the paresis of left vocal cord, left soft palate and left sided facial palsy were minimal. On subsequent follow up visit, patient improved a lot clinically with mild residual palsy of lower cranial nerves of left side and was advised to continue physiotherapy.

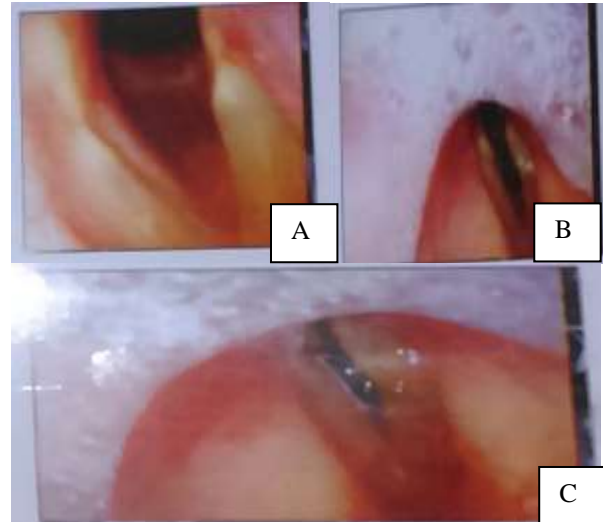


Figure 3A, B, C: Endoscopic examination showed fixation of left vocal cord in para-median position irrespective of phonation and breathing.

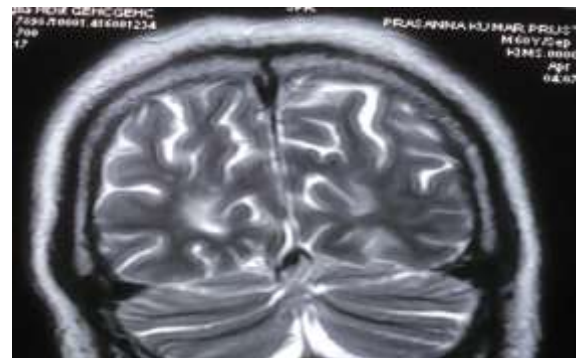


Figure 4: MRI scan of brain revealed no abnormality.

DISCUSSION

Differentiation of Ramsay Hunt syndrome or herpes zoster oticus associated with cranial polyneuropathy from other diseases is essential for accurate diagnosis and proper management. After primary infection, the varicella viruses usually remain dormant in sensory dorsal root ganglia and activated from latency in elderly, diabetes and immuno-compromised patients. Reactivation of varicella from geniculate ganglion causing LMN type of 7th cranial nerve palsy and vesicular rash in external ear along with severe otalgia comprises the Ramsay Hunt syndrome.

The most common presentation of herpes zoster in the head and neck region is called Ramsay Hunt syndrome

(RHS), which rarely accompanies multiple cranial nerve involvement. Herpes zoster also involves the mucous membrane of the tongue, palate, pharynx, and larynx. Herpes zoster infection of the larynx accompanied by RHS with cranial polyneuropathy is extremely rare, with only few reported cases in the literature.¹⁻⁵

About 12% of all peripheral facial nerve palsies are caused by varicella zoster virus. The occurrence rate of associated cranial polyneuropathy has been reported to be 1.8-3.2% and cranial nerves VII, VIII, IX and X are the ones most commonly affected.^{6,7}

In present case, the skin lesions which were confined to left pinna with associated LMN type of left facial palsy was the key to the diagnosis of RHS. Besides these abnormalities, oropharyngeal discomfort and complaints such as dysphagia and hoarseness were more troublesome symptom due to paralysis of the left sided pharyngeal muscles.

Although MRI scan of Brain can show the enhancement of the involved nerve in some cases, the findings do not provide information about severity or prognosis.^{8,9} In present case, no enhancement of involved cranial nerve (CN) was noted on MRI with gadolinium enhancement even with multiple involvement of CN VII, IX,X and XII.

The cause of multiple CN involvement has been explained as a consequence of an inflammation-induced infarction of a small vessel knowing that a small branch of the carotid artery supplies two or three contiguous nerves.⁴ Also the occurrence of anastomosis among 5th, 7th, 9th and 10th cranial nerve explains why the symptoms occur in these nerves. In addition, cranial nerves neighbourhood in the cavernous sinus also explain the theory of HZO with multiple cranial nerve palsy.¹⁰

As the patient was able to take semisolid diet orally, he was given parenteral acyclovir along with oral steroid. There was no statistical significant difference in the outcome were noted among patients treated with oral and intra venous acyclovir. Recent data suggests that treatment with acyclovir prevents the permanent facial palsy in Ramsay Hunt syndrome.

CONCLUSIONS

Multiple cranial nerve palsy has been observed in some cases of patients who were referred with a preliminary diagnosis of Ramsay Hunt syndrome. These patients are required to be examined in detail for involvement of other cranial nerves. Early diagnosis and treatment is required for reversing the functions of cranial nerves and decreasing the chance of developing other complications.

ACKNOWLEDGEMENTS

The authors would like to acknowledge the Kalinga Institute of Medical Sciences authority for the support for managing the case.

Funding: No funding sources

Conflict of interest: None declared

Ethical approval: Not required

REFERENCES

1. Steiner I, Kennedy PG. Herpes simplex virus latent infection in the nervous system. *J Neurovirol* 1995;1(1):19-29.
2. Chitose SI, Umeno H, Hamakawa S, Nakashima T, Shoji H. Unilateral associated laryngeal paralysis due to varicella-zoster virus: virus antibody testing and videofluoroscopic findings. *J Laryngol Otol*. 2008;122(2):170-6.
3. Nishizaki K, Onoda K, Akagi H, Yuen K, Ogawa T, Masuda Y. Laryngeal zoster with unilateral laryngeal paralysis. *ORL J Otorhinolaryngol Relat Spec*. 1997;59(4):235-7.
4. Bossche VDP, Bossche VDK, Vanpoucke H. Laryngeal zoster with multiple cranial nerve palsies. *Eur Arch Otorhinolaryngol*. 2008;265(3):365-7.
5. Watelet JB, Evrard AS, Lawson G, Bonte K, Remacle M, Van Cauwenberge P, et al. Herpes zoster laryngitis: case report and serological profile. *Eur Arch Otorhinolaryngol*. 2007;264(5):505-7.
6. Kim YH, Chang MY, Jung HH, Park YS, Lee SH, Lee JH, et al. Prognosis of Ramsay Hunt syndrome presenting as cranial polyneuropathy. *Laryngoscope*. 2010;120:2270-6.
7. Patro S, Mishra GC, Toppo L, Khatua P. Ramsay Hunt Syndrome with 8th cranial nerve palsy in a diabetic patient. *Orissa Physicians Journal*. 2010;6:98-102.
8. Korzec K, Sobol SM, Kubal W, Mester SJ, Winzelberg G, May M. Gadolinium-enhanced magnetic resonance imaging of the facial nerve in herpes zoster oticus and Bell's palsy: clinical implications. *Am J Otol*. 1991;12:163-8.
9. Engström M, Abdsaleh S, Ahlström H, Johansson L, Stålberg E, Jonsson L. Serial gadolinium-enhanced magnetic resonance imaging and assessment of facial nerve function in Bell's palsy. *Otolaryngol Head Neck Surg*. 1997;117:559-66.
10. Ohashi T, Fusimoto M, Shimizu H, Atsumi T. A case of isolated vagus nerve palsy with herpes zoster. *Rhinso Shinkeigaku*. 1994;34:928-9.

Cite this article as: Sahoo D, Patro S, Khora PK, Panda UN. A case of herpes zoster oticus with multiple cranial nerve palsy. *Int J Adv Med* 2016;3:780-2.