

Review Article

Amyand's hernia: a need for greater surgical awareness

Ketan Vagholkar*, Amish Pawanarkar, Suvarna Vagholkar, Kashmoorvalishah Pathan

Department of Surgery, D. Y. Patil University School of Medicine, Navi Mumbai 400706, Maharashtra, India

Received: 10 April 2016

Accepted: 15 April 2016

*Correspondence:

Dr. Ketan Vagholkar,

E-mail: kvagholkar@yahoo.com

Copyright: © the author(s), publisher and licensee Medip Academy. This is an open-access article distributed under the terms of the Creative Commons Attribution Non-Commercial License, which permits unrestricted non-commercial use, distribution, and reproduction in any medium, provided the original work is properly cited.

ABSTRACT

Amyand's hernia is typically described as a inguinal hernia containing the appendix in its sac. The true incidence of this hernia is still not discernible in view of its rarity. However the chances of complications in this type of hernia are extremely high. The clinical presentation of Amyand's hernia is variable making the diagnosis challenging. This paper describes the pathophysiology and surgical approaches to Amyand's hernia to create awareness of this occasional surprise.

Keywords: Amyand's hernia, Appendix, Diagnosis, Treatment

INTRODUCTION

Inguinal hernia continues to be the commonest surgical lesion confronted by the general surgeon. A wide range of contents are usually encountered in an inguinal hernia sac. Omentum and small intestine are the commonest. However appendix can be a rare content posing both a diagnostic and technical challenge. Amyand's hernia was first described by Claudius Amyand, who first performed an appendectomy in a patient who presented with a right inguinal hernia.¹ Majority of these hernias are complicated by virtue of inflammation of appendix in the hernia sac.²⁻⁴ This renders management extremely difficult.⁴⁻⁶

Pathophysiology

The appendix in a hernia sac is vulnerable to inflammation. When inflammation develops the signs of incarceration of the hernia develop. The inflammatory process may proceed to gangrene and perforation adding to the mortality of the disease if misdiagnosed. Inflammation in the hernia sac can also cause damage to surrounding structures. This can cause damage to adjacent testis as well as lead to necrotising fasciitis.⁵⁻⁸

This in turn can also lead to spread of infection to the peritoneal cavity leading to peritonitis.⁸⁻¹¹ Rare adenocarcinoid tumours have also been described in the appendix in Amyand's hernia.¹² Surprisingly an inflamed appendix may even appear in a left sided inguinal hernia.¹³ Till date only seven cases of left sided Amyand's hernia have been described. This can be a serious challenge not only in diagnosis but also in treatment. Left sided Amyand's hernia could be associated with either a mobile caecum, intestinal malrotation or situs inversus.¹³ Awareness of all these possibilities is essential to develop a surgical algorithm in managing Amyand's hernia.

Diagnosis

Pre-operative diagnosis of Amyand's hernia is an uncommon phenomenon.¹⁴⁻¹⁶ A contrast enhanced CT scan may perhaps document the presence of the caecum as a content of a large long standing hernia sac.¹⁷ This should raise the suspicion of the possibility of Amyand's hernia. In majority of cases Amyand's hernia is diagnosed intraoperatively (Figure 1). Adequate surgical expertise is therefore required to make a decision regarding the further course of management.

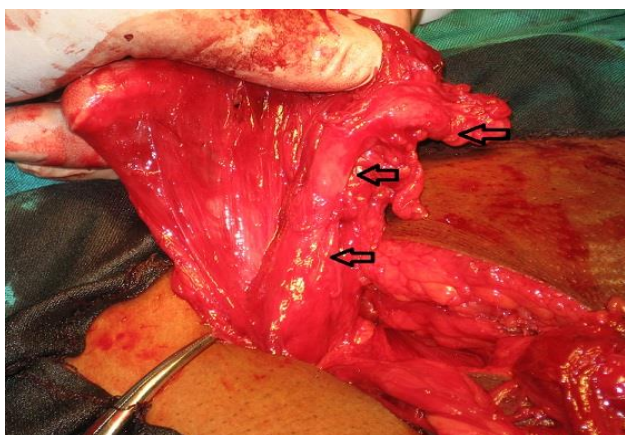


Figure 1: Appendix as the content of a right sided inguinal hernia sac.

Management

Losanoff, et al has proposed a classification system for Amyand's hernia with a view to improve the treatment outcome.¹⁸ It is based on the status of the appendix within hernia sac.

Type 1 is normal appendix where in reduction of contents with mesh hernioplasty will suffice.

Type 2 is where acute appendicitis has developed within the hernia sac. Appendectomy needs to be performed followed by repair of the hernia.

Type 3 is where the severity of inflammation of the appendix is complicated by peritonitis. This may necessitate appendectomy through a lower midline laparotomy.

Type 4 is where the appendix may be accompanied by an abnormal pathology such as a tumour. These cases may require further workup and definitive treatment.

The type of hernia repair to be performed is the most contentious issue in Amyand's hernia.¹⁹⁻²¹ A simple herniorrhaphy in the form of either a Bassini's or Shouldice's repair should suffice. Performing a hernioplasty by placement of prosthesis would be a dangerous proposition. This violates the basic concept of preventing surgical site infection as one combines a clean procedure with a clean contaminated procedure.^{22,23}

Despite utmost precautions to prevent inadvertent contamination by gastrointestinal luminal organisms yet chances of infection continue to remain high leading to infection of the prosthesis, which can be a surgical disaster. Therefore it would be a safe practice to combine reduction of contents in a non-inflamed appendix with a hernioplasty procedure or an appendectomy in case of complications with a herniorrhaphy procedure.^{24,25}

CONCLUSION

Amyand's hernia is a rare type of inguinal hernia containing the vermiform appendix in a state ranging from normalcy to either an inflamed state or in a perforated state.

Majority of cases are diagnosed intra operatively. An appendectomy can be done through a hernia incision in cases of an inflamed appendix.

Herniorrhaphy for repair is the safest option.

ACKNOWLEDGEMENTS

We would like to thank Parth K. Vagholkar for his help in typesetting the manuscript.

Funding: No funding sources

Conflict of interest: None declared

Ethical approval: Not required

REFERENCES

1. Amyand C. Of an inguinal rupture, with a pin in the appendix caeci, incrusted with stone; and some observations on wounds in the guts. Phil Trans R Soc Lond. 1973;39:329.
2. Ali SM, Malik KA, Al- Qadhi H. Amyand's hernia: study of four cases and literature review. SQU Medical Journal. 2012;12:232-36.
3. Sharma H, Gupta A, Shekhawat NS. Amyand's hernia: a report of 18 consecutive cases over a 15 year period. Hernia. 2007;11:31-35.
4. Pelligrino JM, Feldman SD. Case report: Acute appendicitis in an inguinal hernia. N J Med. 1992;89:225-26.
5. Hutchinson R. Amyand's hernia. J R Soc Med. 1993;86:104-5.
6. Lyass S, Kim A, Bauer J. Perforated appendicitis within an inguinal hernia: Case report and review of literature. Am J Gastroenterol. 1997;92:700-2.
7. Kueper Ma, Kirschniak A, Ladurner R. Incarcerated recurrent inguinal hernia with covered and perforated appendicitis and periappendicualr abscess: case report and review of the literature. Hernia. 2007;11:189-91.
8. Serrano A, Ackerman NB. Perforated appendix in an incarcerated inguinal hernia. Arch Surg. 1979;114:968.
9. Milburn JA, Youngson GG. Amyand's hernia presenting as neonatal testicular ischaemia. Pediatr Surg Int. 2006;22:390-2.
10. Francko J, Raftopoulos J, Sulkowski R. A rare variation of Amyand's hernia. Am J Gastroenterol. 2002;97:2684-85.
11. Osorio JK, Guzman- Valdivia GG. Ipsilateral Amyand's and Richter's hernia, complicated by necrotising fasciitis. Hernia. 2006;10:443-46.

12. Wu CI, Yu CC. Amyand's hernia with adenocarcinoid tumor. *Hernia.* 2010;14:423-35.
13. Gupta S, Sharma R, Kaushik R. Left sided Amyand's hernia. *Singapore Med J.* 2005;46:424-25.
14. Singh K, Singh RR, Kuar S. Amyand's hernia. *J Indian Assoc of Pediatr Surg.* 2011;16:171-72.
15. Mullinax JE, Allins A, Avital I. Laparoscopic appendectomy for Amyand's hernia: A modern approach to a historic diagnosis. *J Gastrointest Surg.* 2011;15:533-35.
16. Sagar VR, Singh K, Sarangi R. Endoscopic total extraperitoneal management of Amyand's hernia. *Hernia.* 2004;8:164-65.
17. Torino G, Campisi C, Testa A, Baldassarre E, Valenti G. Prosthetic repair of aperforated Amyand's hernia: hazardous or feasible? *Hernia* 2007;11:551-52.
18. Losanoff JE, Basson MD. Amyand's hernia: what lies beneath – a proposed classification scheme to determine management. *Am Surg.* 2007;73:1288-90.
19. Upadhyaya VD, Kumar V, Srivastava P, Gangopadhyaya AN. Amyand's hernia in infant: A rare entity. *Kathmandu Univ Med J (KUMJ).* 2009;7:143-44.
20. Milanchi S, Allins AD. Amyand's hernia: history, imaging, and management. *Hernia.* 2008;12:321-22.
21. Anagnostopoulou S, Dimitroulis D, Troupis TG. Amyand's hernia: A case report. *World J Gastroenterol.* 2006;12:4761-63.
22. Inan I, Myers PO, Hagen ME, Gonzalez M, Morel P. Amyand's hernia: 10 years' experience. *Surgeon.* 2009;7(4):198-202.
23. Chatzimavroudis G, Papaziogas B, Koutelidakis I, Tsiaousis P, Kaloqirou T, Atmatzidis S, et al. The role of prosthetic repair in the treatment of an incarcerated recurrent inguinal hernia with acute appendicitis (inflamed Amyand's hernia) *Hernia.* 2009;13(3):335-6.
24. Michalinos A, Moris D, Vernadakis S. Amyand's hernia: a review. *Am J surg.* 2014;207(6):989-95.
25. Ciqsar EB, Karadaq CA, Sever N, Dokucu AI. Should appendectomy be performed in Amyand's hernia? Two case reports. *Ulus Travma Acil Cerrahi Derg.* 2013;19(5):488-90.

Cite this article as: Vagholkar K, Pawanarkar A, Vagholkar S, Pathan K. Amyand's hernia: a need for greater surgical awareness. *Int J Adv Med* 2016;3:145-7.