

## Letter to the Editor

# Drug rash with eosinophilia and systemic symptoms, uncommon and commonly missed

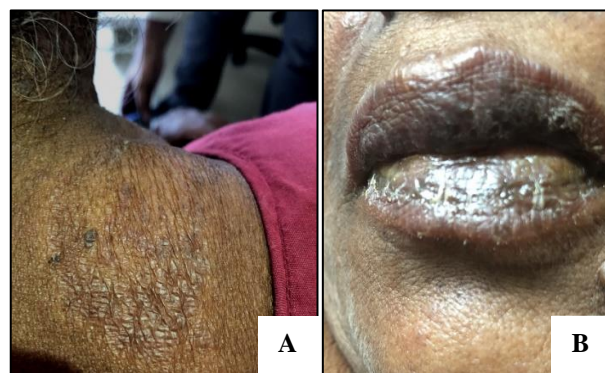
Sir,

Drug Rash with eosinophilia and systemic symptoms, also called DRESS syndrome, is a rare form of drug induced hypersensitivity reaction that presents with skin eruptions, blood count abnormalities (eosinophilia) and internal organ involvement (lung, kidney, liver), making it life threatening at a rapid pace. The most commonly affected organ is liver, mimicking condition similar to acute hepatitis.

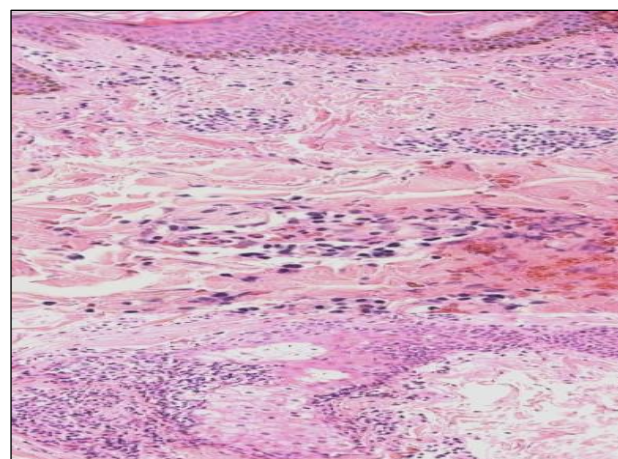
Authors report a case of a 65 year old South Indian female who presented at the Outpatient Department with complaints of generalized body weakness and abdominal pain since 2 weeks. She gave a history of raised temperature 2 days back (101 degrees F). There was no history of breathlessness, burning micturition or chest pain. She gave a positive drug history of taking dapsone for suspected erythema nodosum and was in continuation. She was not a known case of systemic hypertension, diabetes or coronary artery disease, and with no history of alcohol consumption, smoking or chewing of tobacco. On examination, patient was conscious, oriented and afebrile. On physical examination, heart rate was 102 beats/minute, regular, blood pressure of 100/70 mmHg, respiratory rate of 24 breaths/minute. There was no evidence of pallor, icterus, lymphadenopathy, cyanosis. Erythematous patches were seen over her back and lower limbs. There was no evidence of genital involvement. Blood investigations revealed raised eosinophil count and leukocytosis. Liver enzymes showed abnormal increase of transaminases the patient also had elevated liver enzymes-alanine aminotransferase 98 IU/L, aspartate aminotransferase 128 IU/L, alkaline phosphatase 1215 IU/L, gamma-glutamyl transferase 848 IU/L, and elevated bilirubin levels -total bilirubin 20.2 mg/dL and direct bilirubin 16.2 mg/dL (>6 times above the normal range), with direct hyperbilirubinemia suggestive of hepatitis.

Chest x-ray and 2D ECHO done were normal confirming no other organ involvement. Serological test done were negative for HIV, hepatitis A, E, C, HBsAg and HCV. Other selective investigations were done to rule out possible causes of raised eosinophil counts i.e. ANA and ANCA to rule out systemic illness, stool examination was done to eradicate parasitic infestations, sputum analysis for suspected pulmonary infections and were confirmed negative. Ultrasound abdomen showed mild hepatomegaly with no other organs involved.

Skin lesions seen over the back and involving oral mucosa (Figure 1). Skin biopsy was done and was consistent to a drug reactivity showing spongiosis, along with satisfying the RegiSCAR criteria, a diagnosis of DRESS syndrome was made. She was immediately discontinued off dapsone and was started on methylprednisolone 1mg/kg for a period of 7 days, which was then tapered and stopped over a period of 4 weeks.



**Figure 1: A) Skin lesions seen over the back, B): involving oral mucosa.**



**Figure 2: Eosinophils and spongiosis.**

On a repeat follow up after 4 weeks, the propensity of the rashes had markedly decreased, though leaving a few, and repeat liver enzymes showed a distinctive improvement. She was counselled against the use of the drug as the symptoms may re occur proposing a severe life threat. In the past, different terms have been used to describe Drug Hypersensitivity due to Dapsone, Lo Authors and all day

first coined DDS SYNDROME in 1950 or sulfone syndrome. Later, investigations showed its correlation with a hypersensitivity reaction, hence named as “dapson hypersensitivity syndrome.” Currently DHS is treated as an example of DRESS (Drug Reaction with Eosinophilia and Systemic Symptoms), also known as DiHS (Drug induced Hypersensitivity Syndrome). This is solely because not all patients exhibit raised eosinophil counts.<sup>1</sup> The large multitude of terminologies make it challenging for a definite diagnosis. DRESS syndrome is often seen to present with symptoms within 6-8 weeks of the initiation of a particular drug. A varied range of drugs are known to cause DRESS like minocycline, allopurinol, ATT drugs, DAPSONE, but the commonest class of drugs being anti convulsants mainly phenytoin, phenobarbital, carbamazepines and antimicrobials (minocycline,  $\beta$ -lactams, sulfonamides, abacavir, and nevirapine).<sup>2</sup> The approximate incidence of DRESS syndrome varies from 1 in 1000 to 1 in 10,000 drug exposures. The overall mortality associated with DRESS syndrome is about 10% and occurs usually in patients with severe multiorgan involvement, prime cause being liver involvement attributed to eosinophilic infiltration of liver. Diagnostic tests are not standardized, and skin biopsy may or may not be indicative.<sup>3,4</sup>

DRESS syndrome is characterized by the following :

- Widespread cutaneous infestations
- One or more haematological abnormalities
- Systemic involvement-lymphadenopathy and/or one or more than one organ involved (e.g. pericarditis, hepatitis, interstitial nephritis among others).

Successful treatments of DRESS have been reported with the empirical administration of oral prednisone in 30 to 60 mg/day doses. Nonetheless, there are no double-blind studies that reveal the true effectiveness of prednisone.<sup>5-7</sup> The preferred recommendation is to gradually taper the use of prednisone dose. This is because dapson persists in the body for an average of 35 days since it binds to proteins and undergoes entero-hepatic circulation.

Dapsone, on absorption is metabolized by two pathways: N-acetylation and N-hydroxylation. N-hydroxylation gives a potentially toxic metabolite hydroxylamine which could be involved in the pathogenesis.<sup>8</sup> Liver involvement was described either as raised aminotransferase or hepatomegaly, and this case reported both. Other organs such as the kidney or the central nervous system rarely have shown to be involved. Although there is no definitive diagnostic laboratory test for DRESS, a careful history from the patient, complete blood count evaluation along with liver and renal parameters, chest x-ray and an echocardiogram can help us to make a prompt and early diagnosis. Skin biopsy may or may not be indicative.

An early decision to discontinue the causative drug is the primary management of DRESS. DRESS caused by

dapsone is very rare and barely reported. Management of DRESS syndrome is often delayed due to:

- Patients require and early and prompt therapy.
- Diagnostic tests are not standardized.
- In some cases, it is difficult to offer an alternate treatment.

## DISCUSSION

Dress syndrome being a severe adverse drug reaction with a considerable morbidity and mortality, a high level of suspicion is mandatory to diagnose this as early as possible to improve the outcome. An early diagnosis and the start of an effective treatment is of utmost importance, with discontinuation of the offending drug being the primary treatment, as a delay in the initiation of treatment may even to death. The use of systemic steroids is the mainstay of treatment in dress along with other supportive measures. Steroids must be tapered slowly over a period of three to four weeks as there is a high possibility of relapse of symptoms to occur.

## CONCLUSION

The possibility of phantom lung tumor should be considered and excluded in any patient presenting with congestive heart failure and an apparent lung mass on a CXR. It might be the part of congestive cardiac failure.

**Dona Das\*, Dinesh E. Ragav, A. Nasreen Begum**

Department of Medicine, Shri Sathya Sai Medical College and Research Institute, Sri Balaji Vidyapeeth, Tirupurur- Guduvancherry Main Road, Ammapettai, Nellikuppam Chengalpet Taluk, Kancheepuram District, Tamil Nadu, India

**\*Correspondence to**

Dr. Dona Das,  
Email: donad35@gmail.com

## REFERENCES

1. Criado PR, Criado RF, Avancini JD, Santi CG. Drug reaction with Eosinophilia and Systemic Symptoms (DRESS)/Drug-induced Hypersensitivity Syndrome (DIHS): a review of current concepts. *Braz Ann Dermatol.* 2012;87(3):435-49.
2. Ghislain PD, Roujeau JC. Treatment of severe drug reactions: Stevens-Johnson syndrome, toxic epidermal necrolysis and hypersensitivity syndrome. *Dermatol Online J.* 2002;8(1):5.
3. Tas S, Simonart T. Management of drug rash with eosinophilia and systemic symptoms (DRESS syndrome): an update. *Dermatol.* 2003;206(4):353-6.
4. Lee JY, Seol YJ, Shin DW, Kim DY, Chun HW, Kim BY, et al. A case of the drug reaction with eosinophilia and systemic symptom (DRESS)

- following isoniazid treatment. *Tuberculosis Respiratory Dis*. 2015;78(1):27-30.
5. Zhu YI, Stiller MJ. Dapsone and sulfones in dermatology: overview and update. *J Am Academy Dermatol*. 2001;45(3):420-34.
  6. Prussick R, Shear NH. Dapsone hypersensitivity syndrome. *J Am Acad Dermatol*. 1996;35(2):346-9.
  7. Bucarechi F, Vicente DC, Pereira RM, Tresoldi AT. Dapsone hypersensitivity syndrome in an adolescent during treatment during of leprosy. *J Institute Trop Med São Paulo*. 2004;46(6):331-4.
  8. Koseifi SG, Guha B, Nassour DN, Chi DS, Krishnaswamy G. The Dapsone hypersensitivity syndrome revisited: a potentially fatal multisystem disorder with prominent hepatopulmonary manifestations. *J Occupational Med Toxicol*. 2006;1(1):9.

**Cite this article as:** Das D, Jain S, Ragav DE, Begum AN. Dress syndrome, uncommon and commonly missed. *Int J Adv Med* 2019;6:1360-2.