

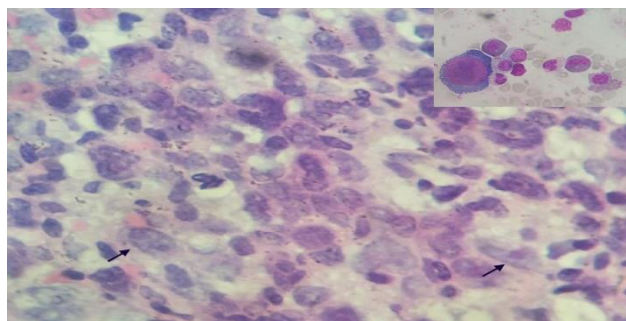
## Letter to the Editor

# An unusual cause of anemia in a case of Hodgkin lymphoma

Sir,

Pure red cell aplasia (PRCA) due to parvovirus has been found to be a cause of anaemia in a variety of settings. Rarely, this may complicate the course of a hematolymphoid malignancy. Very few cases of Hodgkin lymphoma with PRCA described in literature and all the cases had PRCA following chemotherapy. This case is unique where the patient presented with anemia at presentation of the primary disease.

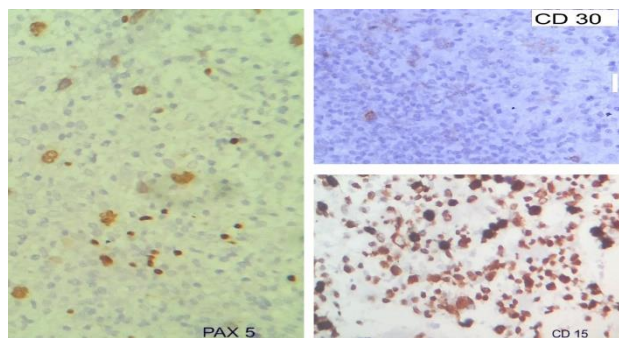
A 10 year old boy presented with right axillary swelling, easy fatigability and high grade fever for one month. On examination, he had anemia, bilateral axillary lymphadenopathy and hepatosplenomegaly. Peripheral blood examination showed hemoglobin 60g/L with normal WBC and platelets. Reticulocyte count was 0.5%. Lymph node biopsy with IHC was suggestive of classical Hodgkin lymphoma. Bone marrow aspiration was cellular with paucity of erythroid precursors. Intranuclear inclusions and few giant proerythroblasts were noted (Figure 1, Inset). Imaging revealed enlarged mediastinal and mesenteric lymph nodes and hepatosplenomegaly.



**Figure 1: Bone marrow trephine biopsy (magnification 400x) shows presence of pleomorphic cell population with large atypical cells (arrow) which are mostly mononucleated with prominent basophilic nucleoli; Inset - bone marrow aspiration (magnification 400x)– giant proerythroblasts with intranuclear inclusions.**

Serology for parvovirus IgM and IgG were positive. BM biopsy showed marrow infiltration by atypical mononuclear cells (Figure 1) and were positive for CD 15, CD 30 and PAX 5 and negative for CD3, CD20, CD 43, CD45 and ALK1 (Figure 2). A diagnosis of classical Hodgkin lymphoma with bone marrow involvement and parvovirus B-19 induced red cell aplasia was made.

Patient started on chemotherapy with proper transfusion support.



**Figure 2: Immunohistochemistry (magnification 400x) - the large atypical cells are positive for PAX 5, CD 30 and CD 15.**

Pure red cell aplasia (PRCA) due to parvovirus has been found to be a cause of anemia in a variety of settings. Rarely, this may complicate the course of a hematolymphoid malignancy. There are 4 cases of Hodgkin lymphoma with PRCA described in literature and all the cases had PRCA following chemotherapy.<sup>1</sup> This case is unique where the patient presented with anemia at presentation of the primary disease.

**Prakas K. Mandal\*, Kartthik S.**

Department of Hematology, NRS Medical College; Kolkata-700014, India

**\*Correspondence to:**

Dr. Prakas K. Mandal,  
E-mail: prakas70@gmail.com

## REFERENCES

1. Hirokawa M, Sawada KI, Fujishima N, Kawano F, Kimura A, Watanabe T, et al. Acquired pure red cell aplasia associated with malignant lymphomas: a nationwide cohort study in Japan for the PRCA collaborative study group. *Am J Hematol.* 2009;84(3):144-8.

**Cite this article as:** Mandal PK, Kartthik S. An unusual cause of anemia in a case of Hodgkin lymphoma. *Int J Adv Med* 2016;3:443-3.