

Case Report

Thrombolytic therapy in prosthetic valve thrombosis in the second trimester of pregnancy

Santhosh Jadhav, H. S. Natraj Setty*, Shankar S., Phani Teja Mundru, Yeriswamy M. C.,
Babu Reddy, Jayashree Kharge, Sathwik Raj, Arunkumar Ullegaddi, Rahul Patil,
T. R. Raghu, C. N. Manjunath

Department of Cardiology, Sri Jayadeva Institute of Cardiovascular Sciences and Research, Bangalore, Karnataka, India

Received: 20 February 2020

Revised: 28 February 2020

Accepted: 20 March 2020

***Correspondence:**

Dr. H. S. Natraj Setty,

E-mail: drnatrajsetty75@gmail.com

Copyright: © the author(s), publisher and licensee Medip Academy. This is an open-access article distributed under the terms of the Creative Commons Attribution Non-Commercial License, which permits unrestricted non-commercial use, distribution, and reproduction in any medium, provided the original work is properly cited.

ABSTRACT

Pregnancy with mechanical valves requires anticoagulation, the risk of bleeding and embryopathy associated with oral anticoagulation must be weighed against the risk of valve thrombosis. In the presence of a mechanical valve thrombosis, an appropriate treatment modality must be selected. Prosthetic valve thrombosis during pregnancy requires immediate therapy such as valve replacement, thrombolytic therapy, or surgical thrombectomy. A course of thrombolytic therapy may be considered as a first-line therapy for prosthetic heart valve thrombosis. We describe a primigravida (second trimester) with mitral valve replacement status presenting with acute prosthetic valve thrombosis and treated successfully with intravenous streptokinase.

Keywords: Pregnancy, Prosthetic valve, Thrombolysis, Thrombosis

INTRODUCTION

In a developing nation like India, where rheumatic heart disease is rampant, it can be expected that the prevalence of patients with mechanical heart valve replacement in young female patients would be high.¹ As pregnancy is a prothrombotic state, the incidence of prosthetic valve thrombosis in this patient group is not known, as well as the management options are limited to emergent surgery or pharmacologic thrombolysis. Surgery for PVT in pregnancy is associated with high maternal and fetal morbidity, and the resources are limited in developing countries. The success rate and the complications of pharmacolysis, which is proposed as an alternate option in pregnancy are less studied, and there is sparse data regarding the same in literature.

CASE REPORT

A 32-year-old woman primigravida at 20 weeks of gestation presented with acute onset of shortness of breath of one-day duration, which gradually progressed to NYHA IV. Upon arrival, she was in severe respiratory distress and shock. On inquiry and on reviewing the old reports it was found that she had undergone mitral valve replacement surgery in 2011 with TTK Chitra valve (27mm) for CRHD in our institute. Due to her pregnancy, she was advised to take low molecular weight heparin (LMWH) 60mg SC BID. She was compliant with the medication before the presentation. Appropriate measures were taken with BiPAP support, injection Lasix, and inotropes. The mechanical valve click was not heard on auscultation. Transthoracic echocardiogram showing a

soft thrombus (Yellow arrow) on the mechanical valve with restricted mobility of the leaflets and continuous wave Doppler recording across prosthetic mitral valve with mean gradient 15mmHg (Figure 1 and 2).

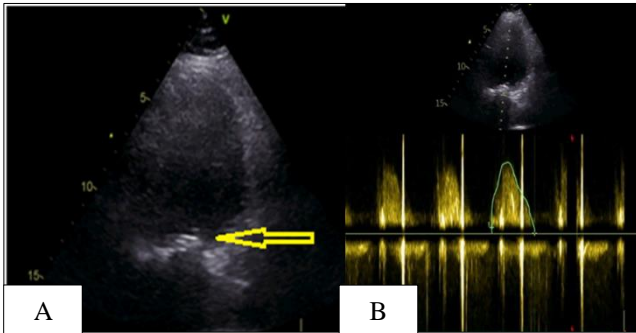


Figure 1: A) Transthoracic echocardiogram showing a soft thrombus (Yellow arrow) on the mechanical valve with restricted mobility of the leaflets, B) continuous wave Doppler recording across prosthetic mitral valve (mean gradient 15mmHg).

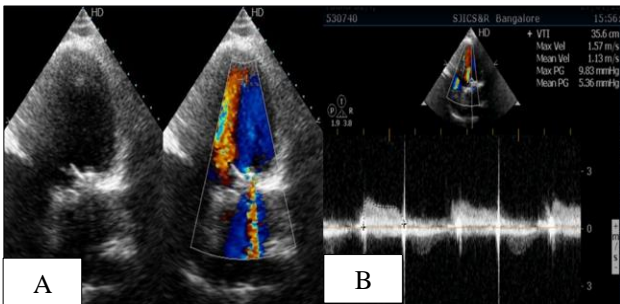


Figure 2: A) Post-thrombolysis reduced turbulence across mitral valve prosthesis, B) Post-thrombolysis continuous wave Doppler recording across prosthetic mitral valve showing significantly reduced gradient (mean gradient 9mmHg).

The diagnosis of Prosthetic valve thrombosis was made based on the clinical scenario and echo findings. The dilemma in management is to treat with emergent surgical exploration vs. pharmacologic thrombolysis. We have planned after discussing with the family and cardio team, pharmacologic thrombolysis with streptokinase 2.5 lakh units bolus over 30min and followed by 1lakh units per hour. Within a few hours after the initiation of thrombolysis, her symptom status improved. After 12 hours after initiation of thrombolysis, the mechanical click was audible, and the screening echo showed that the soft clot was dissolved, post-thrombolysis reduced turbulence across mitral valve prosthesis and Post-thrombolysis continuous wave Doppler recording across prosthetic mitral valve showing significantly reduced gradient (mean gradient 9mmHg) (Figure 2A and 2B). Streptokinase infusion was stopped, and after 6hrs, she was given UFH infusion for another 12 hours maintaining therapeutic aPTT levels. She was able to maintain stable saturations around 95% on room air and BP without

inotropes. She was started on warfarin, which was overlapped with LMWH for three days and discharged on oral warfarin after achieving therapeutic INR. Foetalecho during the admission period was normal, without any congenital disease.

DISCUSSION

The most dreaded complication of mechanical prosthetic valve replacement is dehiscence, disruption, dysfunction, infection, embolism, and thrombosis. Thrombotic prosthetic valve occlusion is uncommon and is reported to occur in 0.5-8% of the left-sided mechanical prosthetic valves and up to 20% of the tricuspid prosthesis.²⁻⁴ The incidence may be still higher in pregnancy. Pregnancy is a prothrombotic state. During pregnancy, and peaking at term and the immediate peripartum period, there is a state of relative hypercoagulability-marked by an increase in the majority of pro-clotting factors, a reduction in natural thrombolytic activity and a reduction in anticoagulant protein activity (e.g., Activated protein C, protein S). Following delivery, these coagulation changes cease, and normal hemostasis generally returns 3-4 weeks following delivery.⁵ Lengyel et al concluded that anticoagulation was inadequate in 82% of patients with prosthetic valve thrombosis.⁶ In general, PVT develops more frequently in the mitral position than at the aortic valve position. PVT should be kept in mind for patients with a history of new or worsening symptoms. The clinical presentation of PVT may vary from dyspnoea, embolic events, and symptoms of cardiac insufficiency, to cardiogenic shock and pulmonary edema. The ideal management of PVT is still controversial. According to AHA recommendations, surgery is the preferred treatment for left-sided PVT. Many authors recommend against using thrombolytic therapy in patients with left heart prosthesis, as it carries a high risk of precipitating cerebral or peripheral embolism, and the re-thrombosis rate is higher. In a limited resource country like India, fibrinolytic therapy has emerged as a promising alternative for surgery, particularly in critically ill patients. The initial success rate was ranging from 75-88% was reported.⁷ Fibrinolytic therapy was found to be safe in pregnancy without increased additional bleeding risk when compared to non-pregnant patients. In a review of many case reports, case studies thrombolytic therapeutic agents didn't show any increased incidence of congenital disease in the newborn. Our patient developed PVT despite taking LMWH regularly. This might be because of the hyper-coagulable state of pregnancy. In general, the dose of LMWH will be given based on the weight of the patient, as 1mg per kg bodyweight. For patients who are on LMWH generally, measurement of the therapeutic efficacy is not advised. But monitoring of anti-Xa activity, as an indicator of efficacy, is advised for high-risk patients like obese patients and in chronic renal failure patients. As pregnancy is a pro-coagulant state with an increased risk of thrombosis, and also because of the weight gain or loss changes associated with pregnancy, it is advisable to monitor levels of anti-Xa levels in pregnancy also. Our

patient received successful thrombolysis with streptokinase, and improvement was dramatic. The fetal echo also revealed no abnormality. The patient was advised to take warfarin as the patient is already in 2nd trimester of pregnancy, where warfarin-induced fetal embryopathy is not reported. She was advised to switch over to UFH at the time of delivery. She was under follow-up.

CONCLUSION

Pregnancy is a prothrombotic state, and strict control of anticoagulation therapy and frequent monitoring is necessary for those patients with mechanical prosthetic valves. Thrombolytic therapy is a safe alternative to emergent surgery, even during pregnancy.

Funding: No funding sources

Conflict of interest: None declared

Ethical approval: Not required

REFERENCES

1. Sani MU, Karaye KM, Borodo MM. Prevalence and pattern of rheumatic heart disease in the Nigerian savannah: an echocardiographic study. *Cardiovasc J Africa*. 2007 Jul;18(5):295-9.
2. Edmunds LH. Thromboembolic complications of current cardiac valvular prosthesis. *Ann Thorac Surg*. 1982;34:96-106.
3. Kontos Jr GJ, Schaff HV, Orszulak TA, Puga FJ, Pluth JR, Danielson GK. Thrombotic obstruction of disc valves: clinical recognition and surgical management. *Ann Thorac Surg*. 1989;48(1):60-5.
4. Thorburn CW, Morgan JJ, Shanahan MX, Chang VP. Long-term results of tricuspid valve replacement and the problem of prosthetic valve thrombosis. *Am J Cardiol*. 1983;51:1128-32.
5. Gartman EJ. The use of thrombolytic therapy in pregnancy. *Obstetr Med*. 2013 Sep;6(3):105-11.
6. Lengyel M, Laszlo V. The role of thrombolysis in the management of left-sided prosthetic valve thrombosis: a study of 85 cases diagnosed by transesophageal echocardiography. *J Heart Valve Dis*. 2001;10:636-49.
7. Silber H, Khan SS, Matloff JM, Chau A, DeRobertis M, Gray R. The St. Jude valve. Thrombolysis as the first line of therapy for cardiac valve thrombosis. *Circulation*. 1993;87:30-7.

Cite this article as: Jadhav S, Setty HSN, Shankar S, Mundru PT, Yeriswamy MC, Reddy B, et al. Thrombolytic therapy in prosthetic valve thrombosis in the second trimester of pregnancy. *Int J Adv Med* 2020;7:853-5.