

Case Report

Wasp sting complicated with chronic DVT and pulmonary artery thromboembolism: a rare case report

Suresh Kumar Yogi*, C. R. Choudhary, Hemant Borana, Govind Desai

Department of Respiratory Medicine, Dr. S N Medical College, Jodhpur, Rajasthan, India

Received: 06 May 2020

Accepted: 01 June 2020

*Correspondence:

Dr. Suresh Kumar Yogi,

E-mail: sureshyogi13886@gmail.com

Copyright: © the author(s), publisher and licensee Medip Academy. This is an open-access article distributed under the terms of the Creative Commons Attribution Non-Commercial License, which permits unrestricted non-commercial use, distribution, and reproduction in any medium, provided the original work is properly cited.

ABSTRACT

Pulmonary embolism remains a disease that needs high clinical suspicion to prevent mortality and morbidity. More so in young healthy individuals, the suspicion is very low as compared to old age individuals with multiple co-morbid conditions. Pulmonary embolism carries high mortality if not suspected and treatment initiated as early as possible. Authors describe a case of yellow wasp stings associated with chronic left leg DVT and pulmonary artery thrombosis, which is rare following wasp stings and therefore extend the clinical spectrum of wasp envenomation.

Keywords: Deep venous thrombosis, Pulmonary embolism, Wasp envenomation, Yellow wasp stings

INTRODUCTION

Acute pulmonary embolism is a component of venous thromboembolism (VTE), which may prove fatal if not suspected and subsequently treated. The incidence of pulmonary embolism is around 0.5-1 case per 1000.¹ Clinical suspicion is very low in young healthy individuals as compared to old age individuals with multiple co-morbid conditions.

Young patients are more likely to be mismanaged, as suspicion in a healthier young patient is very low, and despite various diagnostic modalities high clinical suspicion remains the key for diagnosis.

CASE REPORT

A 40-year-old male the patient presented to our OPD with a history of dry cough, left-sided chest pain and shortness of breath for 10days, He was a nonsmoker. He had a history of wasp sting on his left leg at the calf region 2 months back while he was working in his garage.

Initially, there was just local pain and inflammation without any systemic reaction, later he had noticed that his left leg became red, swollen, and painful. He was treated at a peripheral hospital with chlorpheniramine and Hydrocortisone injection. There was no history of immobilization, hypertension, hyperlipidemia, diabetes mellitus, cancer, atrial fibrillation, recent trauma or surgery, and chronic medication.

Initial examination on admission, he was apparently well, conscious and oriented, SpO₂ 94% on room air, regular pulse of 108 beats per minute and blood pressure of 100/60 mmHg. The general physical examination was normal. On percussion there was a stony dull note, on auscultation he had reduced breath sounds on the left side of the chest. The initial investigations were WBC= 8900/cmm, Hb-15g/dl, platelet count 341000/ul. Prothrombin time and activated partial thromboplastin time were 16 seconds and 24 seconds, respectively. Random blood sugar was 107 mg/dL.

Renal and liver function tests were normal. Serum D-dimer was high. Total serum IgE was high but wasp

venom specific IgE could not be done due to lack of availability of the test at our center. HIV serology was negative. Sputum microscopy for AFB is negative. Chest x-ray was suggestive of left-sided pleural effusion (Figure 1). Thoracocentesis was done. The pleural fluid analysis was suggestive of exudative fluid. ECG was normal in sinus rhythm. Echocardiography was revealed preserved left ventricular systolic function (LVEF = 56%) without intracardiac vegetation or thrombosis.

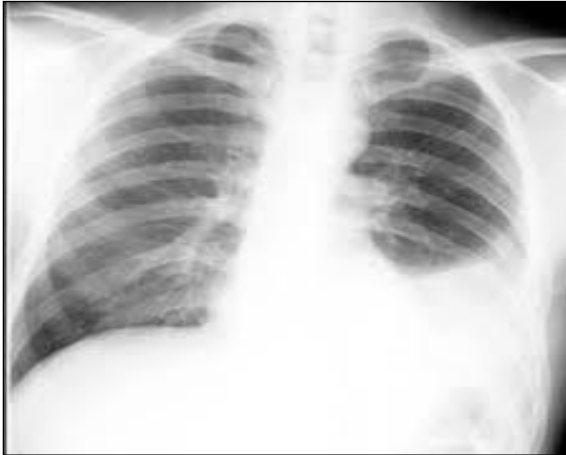

Figure 1: Chest radiograph P/A view left sided pleural effusion.

CECT - thorax shows moderate left pleural effusion with filling defect in the distal right main pulmonary artery (causing 80-85% luminal compromise) and its segmental branches. The filling defect also noted in upper lobar and descending interlobar and its segmental branch of the left pulmonary artery causing 90% luminal narrowing. (Figure 2).

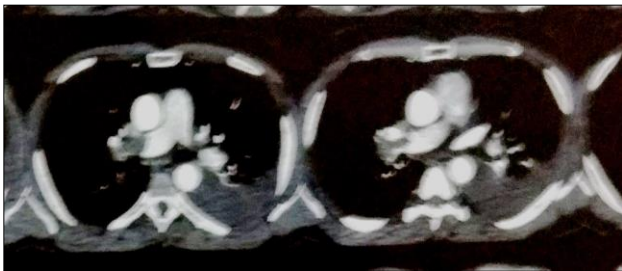


Figure 2: Defect in a distal right main pulmonary artery with left side pleural effusion.

CT Pulmonary angiography- Moderate left pleural effusion with there was no enhancing filling defect seen in the right pulmonary artery and its branches causing 85-90% luminal compromise of right pulmonary artery another loan announcing feeling defect are also noted in the distal part of left coronary artery and its branches (upper lobar and interloper) causing 50- 60% luminal compromise of the lower segmental branch, suggestive of thrombosis (Figure 3).

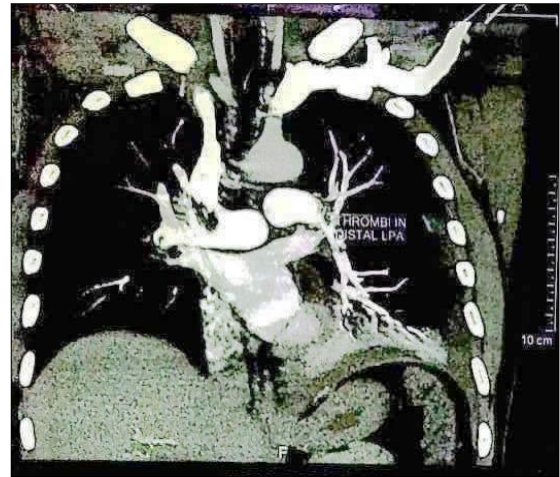


Figure 3: Thrombosis in the left pulmonary artery and extending into lobar branches.

Color Doppler of lower limbs showed echogenic material in left external iliac vein, common femoral vein, femoral vein, popliteal vein and tibial vein suggestive of chronic deep vein thrombosis.

The patient was started on anticoagulants and referred to the CTVS department for further management.

DISCUSSION

Pulmonary thromboembolic disease is the condition in which blood clots (thrombus or multiple thrombi) migrate from the systemic circulation to the pulmonary vasculature. Most of the thrombi arise from the deep veins of the lower and upper extremities (deep venous thrombosis (DVT)). A recent systematic review revealed that silent pulmonary embolism was present in 32% of patients with deep venous thrombosis.² Mechanism of thrombus formation in the venous system is described by Virchow, as Virchow's triad:

- Relative venous stasis,
- Injury to the wall of the vein and
- Increased coagulability of the blood itself.

The risk factors of thrombosis like immobilization, hypertension, hyperlipidemia, diabetes mellitus, cancer, atrial fibrillation, recent trauma or surgery, and chronic medication. The above-mentioned risk factors were absent in our patient, except for the history of wasp sting at the calf region of the left leg.

Yellow Wasps belong to the order Hymenoptera.³ A wasp sting is a common event that has occurred worldwide, especially in developing countries like India. Despite the common occurrence of wasp stings and local and systemic allergic reactions, vascular complications like pulmonary thromboembolism following wasp sting is rarely reported.³ Some cases had been reported like acute

myocardial infarction, descending aortic thrombosis and cerebral infarctions, following a wasp sting.^{4,6}

The exact pathogenesis of vascular complications following a wasp sting is not known. The possible pathophysiological mechanisms responsible for vascular events are related to vasoactive and thrombogenic substances present in the wasp venom.⁶ Wasp venom contains a wide range of vasoactive, inflammatory, and thrombogenic peptides and amines including histamines, leukotrienes, and thromboxane that are responsible for the local and systemic reaction.⁷ Leukotrienes and thromboxane cause platelet aggregation, vasoconstriction, and thrombosis.⁸

CONCLUSION

Physicians encounter large numbers of hymenopteran sting cases each year. These patients typically present with local reactions. Systemic manifestations, such as anaphylaxis, are less common. Pulmonary manifestations are extremely rare. Treating physicians should be aware of the rare but possible complication of venous thromboembolism (VTE) and pulmonary artery thrombosis in a case of a wasp sting.

Funding: No funding sources

Conflict of interest: None declared

Ethical approval: Not required

REFERENCES

1. Heit JA. The epidemiology of venous thromboembolism in the community. *Arterioscler, Thromb, Vascular Biol.* 2008 Mar 1;28(3):370-2.
2. Stein PD, Matta F, Musani MH, Diaczok B. Silent pulmonary embolism in patients with deep venous thrombosis: a systematic review. *Am J Med.* 2010 May 1;123(5):426-31.
3. Wan PW. ABC of allergies: Venom allergy. *BMJ.* 1998;316:1365-8.
4. Wagdi P, Mehan VK, Bürgi H, Salzmann C. Acute myocardial infarction after wasp stings in a patient with normal coronary arteries. *Am Heart J.* 1994 Oct 1;128(4):820-3.
5. Valla M, Moulin F, Angioi M, Groben L, Sadoul N, Aliot E. Myocardial infarction in a 45-year-old man following an anaphylactic reaction to a wasp sting. *Int J Cardiol.* 2011 May 5;148(3):e63-5.
6. Chen DM, Lee PT, Chou KJ, Fang HC, Chung HM, Chang LK. Descending aortic thrombosis and cerebral infarction after massive wasp stings. *Am J Med.* 2004 Apr 15;116(8):567-9.
7. Sookrung N, Wong-din-dam S, Tungtrongchitr A, Reamtong O, Indrawattana N, Sakolvaree Y, et al. Proteome and allergenome of Asian wasp, *Vespa affinis*, venom and IgE reactivity of the venom components. *J Prot Res.* 2014 Mar 7;13(3):1336-44.
8. Wilson JD, Braunwald E, Isselbacher KJ, Wallace JF. Disorders caused by venoms, bites and stings. In: Wilson JD, Braunwald E, Isselbacher KJ, editors. *Harrison's principles of internal medicine.* New York: Mc Graw Hill; 1992:2187-2194.

Cite this article as: Yogi SK, Choudhary CR, Borana H, Desai G. Wasp sting complicated with chronic DVT and pulmonary artery thromboembolism: a rare case report. *Int J Adv Med* 2020;7:1184-6.