

Original Research Article

A clinical study of corneal complications of cataract surgery

Anjana, N. L. Padmaja*, D. Sundararajan, K. Namitha Bhuvaneshwari, Manjunathan

Department of Ophthalmology, Meenakshi Academy of Higher Education and Research, Meenakshi Medical College Hospital and Research Institute, Enathur, Kanchipuram, Tamil Nadu, India

Received: 26 July 2020

Accepted: 14 September 2020

***Correspondence:**

Dr. N. L. Padmaja,

E-mail: raghurananjana@gmail.com

Copyright: © the author(s), publisher and licensee Medip Academy. This is an open-access article distributed under the terms of the Creative Commons Attribution Non-Commercial License, which permits unrestricted non-commercial use, distribution, and reproduction in any medium, provided the original work is properly cited.

ABSTRACT

Background: In this study we investigate the incidence of corneal complications of extra capsular cataract extraction (ECCE) and manual small incision cataract surgery (SICS). We study the various etiological factors leading to these complications and also to highlight various prophylactic intra and post-operative measures to reduce these complications.

Methods: Cataract surgery was conducted on 100 patients at Meenakshi Medical College Hospital and Research Institute. Patients were randomly divided into two groups. Group A of 50 patients were subjected to ECCE with posterior chamber intraocular lenses (PCIOL) and group B of 50 patients to small incision cataract surgery with PCIOL.

Results: On the first post-operative day, 5 post-operative cases developed corneal edema (10%) in ECCE and 4 cases (8%) in SICS. Striate keratitis developed in 4 cases of ECCE (8%) and 3 SICS (6%). Nearly 62% patients who underwent ECCE accepted cylinder between 0.25-0.75 D while there were 52% cases in SICS.

Conclusions: In this study we conclude that with various advances in cataract surgery the incidence of corneal complication have reduced and have helped in early visual rehabilitation and minimization of post-operative astigmatism by careful selection of incision type and location for MSICS.

Keywords: Cataract surgery, Corneal edema, Extra capsular cataract extraction, Manual small incision cataract surgery

INTRODUCTION

The current aim of cataract surgery is, no longer restricted to just restoration of vision, but is now considered to be a refractive surgery i.e. to achieve the state of emmetropia. As a result of the changing trends of cataract surgery, the surgical technique has revolutionized rapidly from intra capsular cataract extraction to extra capsular cataract extraction, from sutured surgery to suture less cataract extraction to most advanced technique of phacoemulsification and so on.

With the recent advances in cataract surgery the incidence of corneal complications have reduced, however this newer technology has also led to a variety of new complications like epithelial toxicity, mechanical or toxic injury to endothelium, stripped Descemet's membrane

(DM), and sterile corneal ulcer. Therefore, careful attention during cataract surgery and in the post-operative period can prevent most of the serious corneal complications.¹

With the evolution of various techniques in cataract surgery preservation of corneal endothelial function continues to be a major goal. Several studies have been conducted to determine the effect of incision size and location on endothelial cell loss.² Even though advancements in surgical technique have led to a reduced incidence of DM detachment and epithelial and fibrous down growth, timely reorganization and intervention is crucial.

In the present era, surgically induced astigmatism had added an entirely unique dimension to cataract surgery

with emphasis focused more on refractive aspects of cataract surgery.

Review of literature shows a trend towards minimization of post-operative astigmatism and early visual rehabilitation by careful selection of location and incision type for small incision cataract surgery.³

This study has been conducted to throw light on the various complications in conventional extra capsular cataract extraction and manual small incision cataract surgery and to identify the causative factors leading to these complications.

METHODS

This is a prospective study carried out at Meenakshi Medical College Hospital and Research Institute, Kanchipuram from January 2019 to December 2019. In this study 100 cataract patients were included and were randomly divided into two groups. Group A of 50 patients were subjected to extra capsular cataract extraction (ECCE) with posterior chamber intraocular lenses (PCIOL). Group B of 50 patients were subjected to small incision cataract surgery (SICS) with PCIOL.

Patients had senile cataract without any obvious ocular co morbidity like corneal opacity, corneal dystrophy or degeneration, glaucoma, uveitis, pseudo-exfoliation or any obvious retinal pathology. Hypertensive and diabetic patients were excluded from study.

A detailed history was elicited. Pre-operative visual acuity was determined. A detailed slit lamp examination and fundus examination was done. Intra-ocular pressure (IOP) measurement using Goldmann applantation-tonometer and syringing to test potency of lacrimal passages was done. IOL power was calculated with keratometer and A-scan.

All the surgeries were performed under microscope under peribulbar anesthesia. Surgeries performed were ECCE or SICS with PCIOL implantation using standard operating technique. Suture material used was 10.0 ethilon. Post-operatively oral antibiotic, analgesics, systemic steroids (only when required) and topical antibiotic steroids were given based on standard post-operative protocols.

Patients were assessed on first post-operative day and were discharged on the third post-operative day. All patients were regularly followed up at 1 week, 6 weeks and 3 months. Visual acuity was assessed and spectacle correction was given at the end of 6 weeks.

RESULTS

Sex wise distribution

Amongst the 100 eyes operated 50 had surgery in the right eye (RE) and 50 had surgery in the left eye (LE). There

were 60 males and 40 females in the study (Table 1). Surgery was done on 48 mature cataracts and 52 immature cataracts. On the first post-operative day 5 cases of corneal oedema (10%) developed in SICS and 4 cases (8%) in ECCE. Striate keratitis developed in 4 SICS cases (8%) and 3 ECCE (6%). Nearly 62% patients in SICS accepted cylinder between 0.25-0.75 D while 52% cases in ECCE group are in this category.

Table 1: Sex wise distribution.

Sex	No. of cases	Percentage
Male	60	60
Female	40	40
Total	100	100

Age wise distribution

Table 2 shows distribution of cataract in different age groups. The maximum number of patients i.e. 40 (40%) were in the age group of 60-69 years. There were 4 patients (4%) in the 40-49 years age group, 21 patients (21%) in the 70-79 year age groups, and 33 patients (33%) in the 50-59 age group and 2 (2%) patients in the 80 years and above age group.

Table 2: Age wise distribution.

Age group (years)	No. of cases	Percentage
40-49	04	4
50-59	32	33
60-69	39	40
70-79	22	21
80 and above	03	2
Total	100	100

Types of cataract

Figure 1 depicts that out of 100 cases operated 48 (48%) were mature cataract while 52 (52%) were immature cataract.

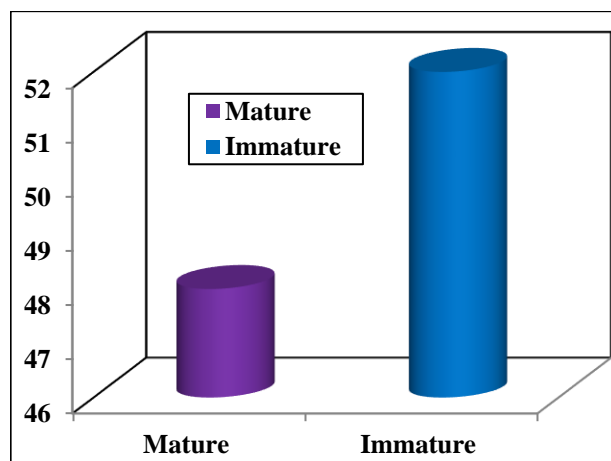


Figure 1: Types of cataract.

Types of cataract surgery

Table 3 shows that the SICS with PCIOL implantation was performed in 50 cases (50%), ECCE with PCIOL implantation in 50 cases (50%).

Table 3: Types of cataract surgery.

Surgery	No. of cases	Percentage
SICS with PCIOL	50	50
ECCE with PCIOL	50	50
Total	100	100

Immediate post-operative corneal complications (first post-operative day)

Table 4 shows that the corneal complications were seen in 16 cases (16%) cases on the first postoperative day. Striate keratitis was seen in ECCE with PCIOL in 4 cases (8%) and in SICS with PCIOL in 3 cases (6%). Corneal edema was seen in ECCE with PCIOL in 5 cases (10%) and in SICS with PCIOL in 4 cases (8%).

Table 4: Immediate post-operative corneal complications (first post-operative day).

Corneal complications	No. of cases		Percentage	
	ECCE PCIOL	SICS PCIOL	ECCE PCIOL	SICS PCIOL
Striate keratitis	4	3	8	6
Corneal edema	5	4	10	8
Total	9	7	18	14

Estimation of induced astigmatism

Table 5 shows that astigmatism of ≤ 0.75 has been induced in early 62% patients by ECCE and nearly 52% patients who underwent SICS.

Table 5: Estimation of induced astigmatism.

S. No.	Astigmatism	ECCE (n=50)	SICS (n=50)
1	0 to 0.75	31 (62%)	26 (52%)
2	1.0 to 1.5	13 (26%)	14 (28%)
3	1.75 to 2.5	03 (6%)	07 (14%)
4	2.51	03 (6%)	03 (6%)

DISCUSSION

Age related cataracts contribute to a substantial volume of cataract surgical load in several developing countries. India, being one of the developing nations, where cataract back log is still a major socio economic problem, procedures like phacoemulsification remain an expensive modality of management for majority of the population and they find it difficult to afford it. MSICS promises to be

a safe procedure especially in white cataracts, enhanced by the adjunctive use of trypan blue dye.^{4,5}

With various recent advances in cataract surgery the incidence of corneal complications has reduced. Review of literature shows a trend towards minimization of post-operative astigmatism and early visual rehabilitation by careful selection of location and incision type for small incision cataract surgery.^{3,6} The incidence of striate keratopathy and corneal edema was seen in maximum with ECCE compared to SICS. The reason here being one is retained viscoelastic in anterior chamber (AC) in many case and second is increased maneuvering in AC during expressing hard nucleus after prolapsing into AC.⁷

Striate keratitis and corneal edema resolved within 8 days of medical treatment. These findings were with correlation to study conducted by Sudhakar et al.³ They found that mild transient striate keratitis in nearly all cases cleared up within 3 days post-surgery.

This study results are comparable with national survey study and Sudhakar et al.³ A higher induced astigmatism of more than 2.5 D was noted in a few cases of ECCE and this could be due to the corneal flattening over the incision. Therefore, ECCE produces post-operative against rule astigmatism (ATR). However, SICS induces less amount of astigmatism as compared to ECCE as it minimizes the high pre-existing against the rule astigmatism, thereby improving the visual outcome. Also in SICS stabilization of astigmatism is achieved by the end of second day.⁷ The wound strength is better in SICS because of self-sealing tunnel. In SICS, good visual outcome is attributed to the incision and its location away from limbus and absence of sutures, there by producing lesser distortion of central corneal curvature.

CONCLUSION

We conclude that the corneal complication like striate keratopathy (6%) and corneal edema (8%) were transient and resolved by the end of 1 week in SICS group. Post-operative astigmatism of less than 1 D in ECCE with PCIOL (62%) in comparison with SICS with PCIOL where it is only in 52%. Therefore, recent advances in cataract surgery have reduced the incidence of corneal complication and helped in early visual rehabilitation and minimization of post-operative astigmatism by careful selection of incision type and location for MSICS.

Funding: No funding sources

Conflict of interest: None declared

Ethical approval: The study was approved by the Institutional Ethics Committee

REFERENCES

- Spandu U. Small incision cataract surgery (SICS=Modified ECCE). Trocar surgery for cataract surgeons. 2020;145-51.

2. Batlan SJ, Dodick JM. Corneal complications of cataract surgery. *Curr Opin Ophthalmol.* 1996;7(4):52-6.
3. Sakre MM, Nizami S, Singh R, Raghavendra A, Takalkar AA. Assessment of effectiveness of extracapsular cataract surgery versus manual small incision cataract surgery: an observational study. *Int J Comm Med Public Health.* 2019;6(8):3565-9.
4. Natchiar G, Thulasiraj R, Sundaram RM. Cataract surgery at Aravind Eye Hospitals: 1988-2008. *Comm Eye Health.* 2008;21(67):40-2.
5. Lumme P, Laatikainen LT. Risk factors for intraoperative and early post-operative complications in extracapsular cataract surgery. *Eur J Ophthalmol.* 1994;4(3):151-8.
6. Alhassan MB, Kyari F, Achi IB, Ozemela CP, Abiose A. Audit of outcome of an extracapsular cataract extraction and posterior chamber intraocular lens training course. *Br J Ophthalmol.* 2000;84(8):848-51.
7. Hardten. Corneal complications of cataract extraction and IOL implantation. *Curr Opinion Ophthalmol.* 1993;4(4):99-105.

Cite this article as: Anjana, Padmaja NL, Sundararajan D, Bhuvaneshwari KN, Manjunathan. A clinical study of corneal complications of cataract surgery. *Int J Adv Med* 2020;7:1550-3.