

## Case Report

# Corpus callosum infarction: a case report

Ziyad Almushayti\*

Department of Radiology, College of Medicine, Qassim University, Saudi Arabia

**Received:** 12 September 2020

**Revised:** 04 October 2020

**Accepted:** 05 October 2020

### \*Correspondence:

Dr. Ziyad Almushayti,

E-mail: ziyadalmushayti@qu.edu.sa

**Copyright:** © the author(s), publisher and licensee Medip Academy. This is an open-access article distributed under the terms of the Creative Commons Attribution Non-Commercial License, which permits unrestricted non-commercial use, distribution, and reproduction in any medium, provided the original work is properly cited.

### ABSTRACT

Infarctions of corpus callosal are rare due to an abundant collateral blood supply. Few case reports published in the literature regarding the corpus callosum infarction. We present a case of corpus callosum infarction in a 66-year-old man with a history of diabetes mellitus, hypertension, and coronary artery disease who presented to the emergency room with left lower limb weakness. Diagnosed was made based on magnetic resonance imaging and treated conservatively.

**Keywords:** Infarction of corpus callosum, Magnetic resonance imaging, Diffusion-weighted imaging, MR spectroscopy

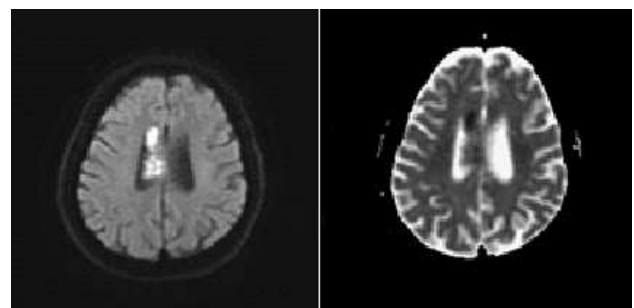
### INTRODUCTION

The largest commissural fibres is the corpus callosum, which connects the left and right cerebral hemispheres cortex, and it is the largest white matter tract in the brain.<sup>1</sup> The corpus callosum is consistent of: rostrum, genu, body, and splenium.<sup>2</sup> The corpus callosum has an abundant vascular supply. The majority of the corpus callosum supplied by three main arteries: The pericallosal artery, the posterior pericallosal artery, and the anterior communicating artery.<sup>3</sup> For that, the corpus callosum rarely involved by infarcts and isolated infarcts are even rarer.

### CASE REPORT

A 66-year-old man with a history of diabetes mellitus, hypertension, and coronary artery disease who presented to the emergency room with left lower limb weakness. On examination, the patient was conscious, oriented, responding with dysarthria, left lower limb weakness, and numbness. Head CT was done and revealed an ill-defined hypodense area in the right body of the corpus callosum.

On admission, a brain magnetic resonance (MR) exam was performed and revealed hyperintense signal on diffusion-weighted imaging sequence with correlated apparent diffusion coefficient (ADC) hypointensity in the right body of the corpus callosum (Figure 1).



**Figure 1: On diffusion-weighted imaging, restricted diffusion is seen in the right body of the corpus callosum and apparent diffusion coefficient images.**

MR spectroscopy reveals a mild reduction of NAA and marked elevation of lactate peaks with no significant rise

of cho peak (not shown). There was no evidence of enhancement on post-contrast T1-weighted images (not shown). These MR findings are consistent with infarction of the corpus callosum. MR angiography was also done and was found normal. The patient was managed conservatively. After that, the patient's neurologic status remained stable, and he transferred to a rehabilitation hospital.

## DISCUSSION

The corpus callosum infarctions are rare, and this is because of abundant blood supply.<sup>4</sup> Two arterial systems are supplying the corpus callosum, the carotid system mainly and the vertebrobasilar system. The pericallosal artery which is the distal portion of the anterior cerebral artery from the carotid system. The terminal branches of the vertebrobasilar system which make the vascularization of splenium.<sup>5</sup> Additional supply comes from the anterior communicating artery (carotid system) in 80% of specimens, by either the subcallosal artery or median callosal artery.<sup>6</sup> These two carotids and vertebrobasilar systems assure intrinsic vascularization of the corpus callosum, for that isolated infarcts are even rarer.<sup>7</sup> The clinical manifestations are nonspecific and complex in corpus callosum infarction.<sup>8,9</sup> So, it is an easily missed diagnosis in the early stage.<sup>10</sup> With the widely used magnetic resonance imaging, the diagnostic rate is much higher.<sup>11,12</sup> On MRI, restricted diffusion on diffusion-weighted imaging (DWI) is the earliest sign.<sup>13</sup> However, the combination of findings on advanced imaging techniques confirming the diagnosis. Atherosclerosis, hypertension, hyperlipidaemia, long-term smoking, diabetes, and coronary heart disease are the main risk factors for developing corpus callosum infarction.<sup>14</sup> The origin of infarction in our case was thought to be cardio-embolic from the patient's poor cardiac status with long-standing CAD.

## CONCLUSION

We present a rare location of infarction in the corpus callosum and have not been well documented in the literature. The clinical manifestations of corpus callosum infarctions are nonspecific and complex but can be diagnosed with magnetic resonance imaging. A Follow-up study should be utilized to observe the expected evolution of the infarction.

*Funding: No funding sources*

*Conflict of interest: None declared*

*Ethical approval: Not required*

## REFERENCES

1. Fitsiori A, Nguyen D, Karentzos A, Delavelle J, Vargas MI. The corpus callosum: white matter or terra incognita. *Brit J Radiol.* 2011;84(997):5-18.

2. Fabri M, Pierpaoli C, Barbaresi P, Polonara G. Functional topography of the corpus callosum investigated by DTI and fMRI. *W J Radiol.* 2014;6(12):895.
3. Pertierra LR, Hughes KA, Vega GC, Olalla-Tárraga MÁ. High resolution spatial mapping of human footprint across Antarctica and its implications for the strategic conservation of avifauna. *PloS one.* 2017;12(1):e0168280.
4. Chrysikopoulos H, Andreou J, Roussakis A, Pappas J. Infarction of the corpus callosum: computed tomography and magnetic resonance imaging. *Eur J Radiol* 1997; 25:2-8.
5. Kakou M, Velut S, Destrieux C. Arterial and venous vascularization of the corpus callosum. *Neurochirurg.* 1998;44(1):31-7.
6. Türe U, Yaşargil MG, Krisht AF. The arteries of the corpus callosum: a microsurgical anatomic study. *Neurosurg.* 1996;39(6):1075-84.
7. Kakou M, Velut S, Destrieux C. Arterial and venous vascularization of the corpus callosum. *Neurochirurg.* 1998;44(1):31-7.
8. Murthy SB, Chmayssani M, Shah S, Goldsmith CE, Kass JS. Clinical and radiologic spectrum of corpus callosum infarctions: Clues to the etiology. *J Clin Neurosci.* 2013; 20:175-7.
9. Ishizaki M, Ueyama H, Nishida Y, Imamura S, Hirano T, Uchino M. Crossed aphasia following an infarction in the right corpus callosum. *Clin Neurol Neurosur* 2012;114: 161-5.
10. Goenka AH, Mukund A, Ahuja J, Kumar A. Reversible lesion in the splenium of the corpus callosum in a child with influenza-associated encephalitis, encephalopathy (IAEE). *J Clin Neurosci.* 2010;17:678.
11. Yuan JL, Wang SK, Guo XJ, Hu WL. Acute infarct of the corpus callosum presenting as alien hand syndrome: evidence of diffusion weighted imaging and magnetic resonance angiography. *BMC Neurol.* 2011;11:142.
12. Kang K and Choi NC. Ipsilateral hemiparesis and spontaneous horizontal nystagmus caused by middle cerebral artery territory infarct in a patient with agenesis of the corpus callosum. *Neurol Sci.* 2012;33:1165-8.
13. Kazi AZ, Joshi PC, Kelkar AB, Mahajan MS, Ghawate AS. MRI evaluation of pathologies affecting the corpus callosum: A pictorial essay. *Ind J Radiol Imag.* 2013;23:321-32.
14. Yang LL, Huang YN, Cui ZT. Clinical features of acute corpus callosum infarction patients. *Int J Clin Exp Pathol.* 2014;7(8):5160-4.

**Cite this article as:** Almushayti Z. Corpus callosum infarction: a case report. *Int J Adv Med* 2020;7:1751-2.