

## Case Series

# A cardiac manifestation in patients with COVID-19: a case series

Mahendra Munirathnam<sup>1</sup>, Archita Ravindranath<sup>1\*</sup>, Madhumati Ramaiah<sup>1</sup>, Parvaiz Kadloor<sup>2</sup>

<sup>1</sup>Department of Medicine, Bowring and Lady Curzon Hospital, Bangalore, Karnataka, India

<sup>2</sup>Department of Cardiology, Charaka Superspeciality Hospital, Bangalore, Karnataka, India

**Received:** 21 October 2020

**Accepted:** 01 December 2020

### \*Correspondence:

Dr. Archita Ravindranath

E-mail: [mailrarchita@gmail.com](mailto:mailrarchita@gmail.com)

**Copyright:** © the author(s), publisher and licensee Medip Academy. This is an open-access article distributed under the terms of the Creative Commons Attribution Non-Commercial License, which permits unrestricted non-commercial use, distribution, and reproduction in any medium, provided the original work is properly cited.

### ABSTRACT

Severe acute respiratory syndrome coronavirus-2 (SARS-CoV-2) virus or the coronavirus 2019 (COVID-19) infection is a novel viral infection causing the 2020 pandemic affecting primarily the respiratory system in the form of influenza like illness, severe acute respiratory illness or asymptomatic respiratory illness and other systems. The cardiovascular system may also be affected, with or without a prior history of cardiovascular diseases. Myocardial injury is common among patients hospitalized with COVID-19 due to stress cardiomyopathy, hypoxic injury, ischemic injury due to cardiac microvascular damage or epicardial coronary artery disease and cytokine storm, however rhythm abnormalities is affected rarely in a transient or severe manner causing rhythm disturbances. The concerns about COVID-19 may result in a delay in proper approach and prompt management in many emergent medical conditions, such as cardiovascular problems. Here, we describe our experience with 4 COVID-19 patients with varied cardiac manifestations presenting to our hospital during the months of September- October 2020.

**Keywords:** COVID-19, Cardiovascular system, Myocardial infarction, Heart block

### INTRODUCTION

Globally, as of 19th October 2020, there have been 39,944,882 confirmed cases of coronavirus 2019 (COVID-19), including 1,111,998 deaths reported to World Health Organization (WHO). It has been noted that about 8% to 28% patients with COVID-19 have evidence of cardiac injury.<sup>1</sup> Moreover, patients with myocardial injury have a significantly higher in-hospital mortality rate (51.2%) compared with those without (4.5%).<sup>2</sup> Several cardiovascular complications of COVID-19 including myocardial infarction, myocarditis, stroke, tachyarrhythmias, transient AV blocks and pulmonary embolism have been reported during the current pandemic.<sup>3</sup> Evidence suggests that cardiac involvement is more common among inpatients hospitalized with COVID-19 disease. Furthermore, patients with cardiac risk factors and established cardiovascular disease have increased vulnerability to develop COVID-19 and tend to have more severe disease with poorer prognosis.

Multiple mechanisms have been suggested for cardiac damage based on studies on previous SARS and Middle eastern respiratory syndrome (MERS) epidemic and the currently ongoing COVID-19.<sup>4-7</sup> As a part of the systemic inflammatory response of severe disease, cytokine surge can result in injury to multiple organs, including cardiac myocytes. Studies have shown elevated levels of proinflammatory cytokines in patients with severe COVID-19 disease.<sup>6</sup> The virus uses ACE2 receptors as an entry point to the cell. This interaction of SARS-CoV2 with ACE2 can result in changes of ACE2 pathways leading to acute injury to the lung, heart, and endothelial cells.<sup>6</sup> As a result of increased cardiometabolic demand associated with systemic infection and hypoxia, it can lead to increased demand and demand-supply mismatch leading to myocardial damage.<sup>6</sup> Acute plaque rupture leading to acute coronary syndrome as a part of systemic inflammation and catecholamine surge can also occur, leading to acute coronary syndrome.<sup>6,8</sup> There are other possibilities, including medications side effects of

corticosteroids, antiviral medications, and immunological agents.

Hypoxia and dyselectrolytemia, both of which are known to contribute to the development of acute arrhythmias have been reported in severe COVID-19 infection, thus the exact contribution of COVID-19 infection in the development of arrhythmias is not exactly known.<sup>9</sup> A definitive mechanism for the development of bradyarrhythmia in patients with COVID-19 has not been established yet. As myocarditis has been reported in many patients with COVID-19, myocardial inflammation and injury may affect the conduction system resulting in complete heart block.<sup>10</sup>

Although the awareness regarding the adverse impact of cardiovascular involvement on prognosis and the cardiovascular manifestations of COVID-19 is increasing, the discrimination between the COVID-19 and non-COVID-related cardiovascular etiologies may be challenging.<sup>11</sup> Out of around the 4000 and odd patients admitted in our institute over the past 7 months, 3 patients developed myocardial infarction and 2 patients developed rhythm disturbances. Here, we present four such cases with varied cardiovascular manifestations of COVID-19 presenting during the months of September - October and also compare the transient AV nodal block caused secondary to the SARS-CoV-2 infection with a COVID-19 positive with congenital heart block.

**CASE SERIES**

**Case 1**

*Case history*

A 65-year-old male with reported history of close contact with a COVID-19-positive person presented with fever, cough, exertional dyspnea and fatigue. He had a history of hypertension and diabetes since the past 20 years and treatment with Amlodipine 5 mg/day, Metformin 500 mg BD and Glimiperide 1 mg OD. On admission, he had temperature of 38 degree Celsius, oxygen saturation (SPO2) of 95% on room air, blood pressure of 130/74 mm Hg and heart rate of 95 bpm. The physical examination was unremarkable except for diffuse bilateral crackles. On day 3 of admission, patient developed increased fatiguability and chest discomfort at rest. He was afebrile, with a heart rate of 80 bpm, GRBS of 146 mg/dl and BP of 140/80 mmHg.

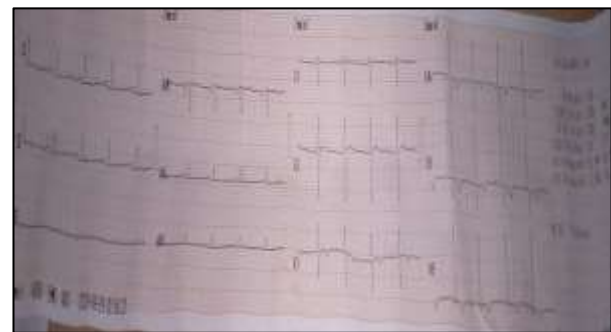
*Investigations, treatment and outcome*

The main laboratory findings are presented in Table 1. His RT-PCR was positive for the SARS-CoV 2 virus. His baseline electrocardiogram (ECG) revealed no significant abnormalities. ECG repeated on day 3 following the development of new symptoms showed a nonspecific pattern: normal sinus rhythm (NSR), left axis deviation, T wave inversions in V3-V6 without any ST-T abnormalities

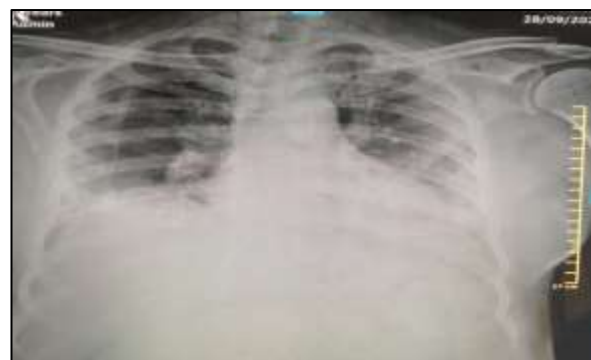(Figure 1). Transthoracic echocardiogram (TTE) showed normal LV size, left ventricular ejection fraction (LVEF) of about 45% without RWMA, grade one LV diastolic dysfunction and normal pulmonary artery pressure (PAP). The cardiac biomarkers were elevated more than 3 times the upper limit of normal. His chest X-ray is depicted in Figure 2.

**Table 1: Main laboratory findings.**

Parameters	Findings
<b>Haemogram</b>	Hb – 11.9 g/dl
	TC – 9900 /cumm,
	Polymorphs– 69.6%,
	Lymphocytes– 21.3%
	Platelet count - 4.11 lakh/mm <sup>3</sup>
<b>Inflammatory markers</b>	CRP – Quantitative - 189.42 mg/l
	D-Dimer - 234 ng/ml
	LDH - 483.3 U/L
	Ferritin - 276.6 ng/ml
<b>Renal function tests</b>	Urea – 46.4 mg/dl
	Creatinine – 0.89 mg/dl
<b>Liver function tests</b>	TB – 0.36 mg/dl
	DB – 0.13 mg/dl
	ALP – 94 U/L
	AST – 32 U/L
	ALT – 42 U/L



**Figure 1: ECG.**



**Figure 2: Chest X-ray.**

Chest X-ray shows evidence of in homogenous patchy opacities in bilateral lung fields, more over bilateral lower

zones with relative sparing of the apices obscuring the heart borders and the domes of the diaphragm suggestive of consolidation of bilateral lung fields.

The patient was diagnosed as SARI and was initiated on treatment with tablet doxycycline 100 mg BD for 5 days, tablet ivermectin 12 mg OD for 3 days, tablet oseltamavir 75 mg BD for 5 days along with multivitamins and other supportive care. On the third day of admission, following the onset of new ECG changes and elevation of cardiac biomarkers and Diagnosed as NSTEMI with COVID-19, patient was initiated on Injection Heparin 5000 U subcutaneous QID along with dual antiplatelets.

His symptoms gradually improved and was discharged on day 14 with advice to continue dual antiplatelets, statins, anti-hypertensives, oral antidiabetics and multivitamins. He had no chest pain or cough at the time of discharge. He was advised to be isolated, and all family members were educated. The patient has good clinical condition upon phone follow-up.

**Case 2**

*Case history*

A 60-year-old COVID-19 positive male presented with history of fever and cough of 1-week duration. He was a known diabetic for the last 10 years on tablet Metformin 500 mg BD with no other known co-morbidities. On admission, he had temperature of 97.5-degree Fahrenheit, oxygen saturation (SPO2) of 86% on room air, blood pressure of 165/88 mm Hg and heart rate of 110 bpm. The physical examination was unremarkable except for diffuse scattered bilateral crepitations. On day 4 of admission, patient developed acute onset of rest angina associated with sweating.

His vital parameters following the onset of new symptoms were as follows– he was afebrile, with a heart rate of 110 bpm, BP of 130/82 mm of Hg, GRBS of 180 mg/dl and saturation dropped to 70% on 10 L of oxygen. Over the next half an hour patient’s saturation and sensorium worsened and he required emergency intubation and ventilatory support. However, the patient succumbed to death in spite of all resuscitative measures on the same day.

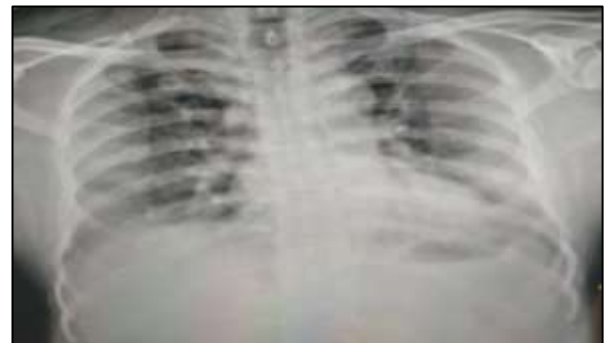*Investigations, treatment and outcome*

The main laboratory findings are presented in Table 2 and his X-ray depicted in Figure 3. His baseline ECG did not show any ischemic changes.

ECG repeated on day 4 following the development of new symptoms showed ST-segment elevation in the anterior precordial leads (Figure 4). Screening echocardiography couldn’t be done due to the rapid deterioration in the patient’s clinical condition. His cardiac troponin I (quantitative) was elevated to 72.8 pg/ml (normal value: 14-42.9 pg/ml).

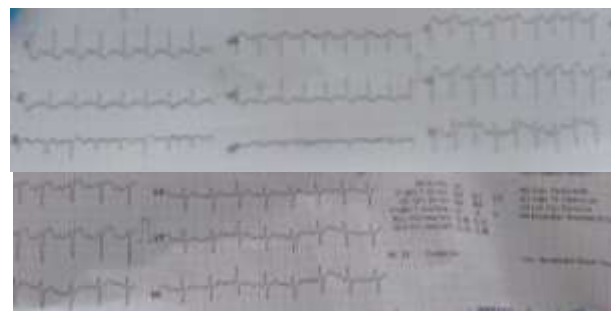
**Table 2: Main laboratory findings.**

Parameters	Findings
<b>Haemogram</b>	Hb-12.6 g/dl
	TC-2600 /cumm,
	Polymorphs- 76%, Lymphocytes– 16%, Platelet count-2.19 lakh/mm <sup>3</sup>
<b>Inflammatory markers</b>	CRP-Quantitative - 133.42 mg/l
	HsCRP-Quantitative-133.35 mg/l
	D-Dimer - 339 ng/ml
<b>Coagulation profile</b>	LDH – 367.1 U/L
	APTT – 24.6 sec
	PT – 11.6 sec
<b>Renal function tests</b>	INR – 0.9 sec
	Urea – 19.8 mg/dl
<b>Liver function tests</b>	Creatinine – 0.87 mg/dl
	TB – 0.49 mg/dl
	DB – 0.13 mg/dl
	ALP – 72 U/L
	AST – 38 U/L
	ALT – 22 U/L



**Figure 3: Chest X-ray.**

Chest X-ray shows evidence of mild peripheral haziness in bilateral lower zones with prominent bronchovascular markings.



**Figure 4: ECG.**

On admission he was diagnosed as Severe acute Respiratory infection and was initiated on treatment with oxygen supplementation via facemask 6 L/min, tablet doxycycline 100 mg BD, tablet ivermectin 12 mg OD, tablet oseltamavir 75 mg BD, Injection dexona 6 mg OD,

Injection clexane 40 U subcutaneous OD along with multivitamins and other supportive care. On the second day, patient was switched over from doxycycline and ivermectin to injection remdesvir along with the other medications. On the 4th day of admission, following the onset of new ECG changes and elevation of cardiac biomarkers, a diagnosis of high Septal wall myocardial infarction was made given loading doses of aspirin, clopilet and atorvastatin and was planning to be thrombolysed with fibrinolytics. But unfortunately, due to his rapidly worsening condition he could not be resuscitated and declared dead.

### Case 3

#### Case history

Patient 3 is an 81-year-old woman with a medical history significant for type 2 diabetes mellitus and hypothyroidism, who presented to the emergency department complaining of generalized weakness for the past 5 days. Her rapid antigen test (RAT) was positive. On arrival to the emergency department, she was noted to be in respiratory distress with bradycardia. Her vitals on admission were as follows – she was afebrile, with a heart rate of 40 beats/min, blood pressure of 130/90 mm of Hg, room air saturation of 82% and a respiratory rate of 25 cycles/min. Her systemic examination was unremarkable except for the presence for bilateral crepitations. She was admitted to the ICU for further management.

#### Investigations, treatment and outcome

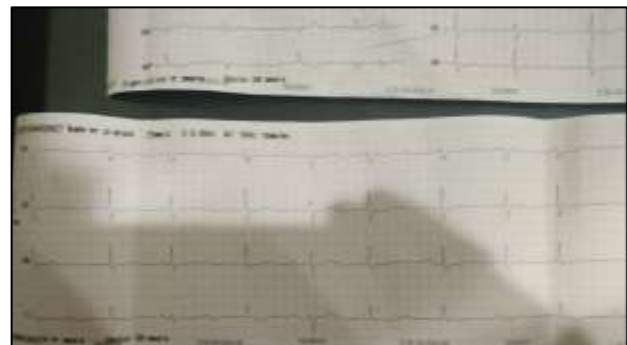Chest radiography revealed bilateral pneumonia (severity score of 13– moderate) and moderate cardiomegaly. Her initial lab work-up is shown in Table 3.

ECG on presentation (Figure 5) showed second-degree atrioventricular nodal block (Wenckebach block or Mobitz type 1 block) along with ischemic changes in the inferior leads (T wave inversions in II, III and aVF). 2D- ECHO could not be done for the patient due to the prevailing situation caused due to the pandemic. However, her previous 2D-ECHO showed sclerotic aortic valve with grade 1 left ventricular diastolic dysfunction. Cardiac MRI to look for the presence of myocarditis couldn't be done due to the non-availability of the same at our centre.

On admission, she was initiated on treatment with IV antibiotics, IV steroids, antiplatelets, low molecular weight heparin, proton pump inhibitors, high flow nasal oxygen, insulin along with multivitamins and other supportive care. After taking consent, she was given injection remdesvir for 5 days. Seroconversion plasma therapy was given (SARS-COV-2 antibodies were negative). She was also initiated on orciprenaline for bradycardia after cardiology opinion. Patient's clinical condition gradually improved after initiation of treatment with antivirals, anticoagulation and other supportive measures.

**Table 3: Main laboratory findings.**

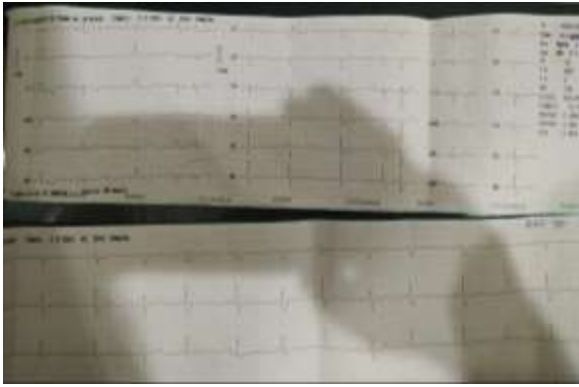
Parameters	Findings
<b>Haemogram</b>	Hb – 10.6 g/dl
	TC – 4800 /cumm,
	Polymorphs– 78%,
	Lymphocytes– 20%, Platelet count – 1.62 lakh/mm <sup>3</sup>
<b>Inflammatory markers</b>	ESR – 54 mm/hr
	CRP – Quantitative – 111.74 mg/l
	D-Dimer - 508 ng/ml
	LDH – 269 U/L
	Ferritin – 543.50 ug/l IL – 6 – 139.6 ng/ml
<b>Cardiac biomarkers</b>	Hs Troponin T – 18.62 pg/ml
	CPK – MB – 1.6 ng/ml
<b>Coagulation profile</b>	APTT – 37.5 sec
	PT – 14.1 sec, INR – 1.02 sec
<b>Serum electrolytes</b>	Sodium – 131 mEq/L
	Potassium – 3.8 mEq/L
	Chloride – 97 mEq/L
	Calcium – 8 mg/dl
	Magnesium – 2.06 mg/dl
<b>Renal function tests</b>	Urea – 24 mg/dl
	Creatinine – 0.86 mg/dl
<b>Liver function tests</b>	TB – 0.36 mg/dl
	DB – 0.18 mg/dl
	ALP – 95 U/L
	AST – 52 U/L
	ALT – 32 U/L



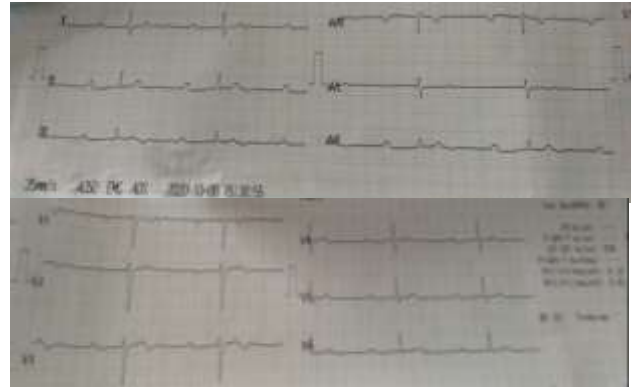
**Figure 5: ECG on presentation.**

ECG (Figure 6) repeated after 5 days of injection remdesvir and low molecular weight heparin showed improvement in the cardiac conduction abnormalities with persistence of some residual block, probably a pre-existing conduction abnormality secondary to an underlying degenerative/sclerotic process.

After 9 days of admission, patient is afebrile, with a heart rate of 50 beats/min but has persisting hypoxemia on high flow oxygen (SpO<sub>2</sub> – 88 % with 65 L/min, 100 % FiO<sub>2</sub>) and is in continuing institutional care for the same.



**Figure 6: ECG after 5 days of injection remdesvir and LMWH.**



**Figure 7: ECG.**

**Case 4**

In comparison to patient 3 presented above, a patient with probable underlying conduction system abnormalities aggravated due to infection with the SARS-COV-2 virus, which showed gradual improvement on treatment with antivirals and other appropriate supportive management, patient 4 is another COVID-19 positive patient whose ECG showed complete heart block of probable congenital etiology.

Patient 4 is a 29-year-old male with no significant past medical or family history who presented with easy fatigability and cough of 3-4 days duration. On arrival to the hospital, he was noted to be afebrile with a heart rate of 45 bpm, BP of 110/80 mm of Hg and oxygen saturation of 97% on room air.

Initial lab work-up was revealed mildly elevated inflammatory markers with a LDH of 301.1 U/L, CRP of 17.79 mg/dl, hs-CRP of 18.72 mg/dl with all other baseline investigations being within normal limits. Dengue serology was negative, serum electrolytes and cardiac biomarkers were within normal limits. ECG on admission showed complete heart block with no changes suggestive of ischemia or myocarditis (Figure 7). It was noted that his ECG showed the presence of narrow QRS complex when compared to the QRS complexes of patient 3.

Screening echocardiography showed LV dilated with mild LV dysfunction-LVEF-45-50% with no RWMA, MR, TR, AR, effusion or clot. Patient is planned for electrophysiological studies following completion of treatment for COVID-19.

His course in hospital was uneventful. He was treated with T. doxycycline 100 mg BD for 5 days, T. ivermectin 12 mg OD for 3 days, T. oseltamavir 75 mg BD for 5 days, T. Orciprenaline 10 mg BD along with multivitamins and other supportive care. He is currently recovering in the hospital.

**DISCUSSION**

Case 1 was initially manifested with an influenza like illness and developed Non-ST elevation myocardial infarction (NSTEMI) characterized by typical angina and elevation of cardiac biomarkers later on during the course of hospital stay. This patient had a history of hypertension and diabetes, both of which are important comorbidities and risk factors for progression of COVID-19 into its severe forms. His illness was complicated due to the involvement of the cardiovascular system in the form of myocardial ischemia by the SARS-COV-2 virus, but despite the history of his co-morbidities, he did not progress to acute respiratory distress syndrome or shock and responded well to the therapies. It has been shown that worse outcomes may be more prevalent in hypertensive and diabetic patients, possibly due to overexpression of angiotensin-converting enzyme 2 (ACE-2) receptors in alveolar epithelial cells. Some researchers speculate that as using ACEIs and ARBs upregulate ACE-2 expression, theoretically this effect could increase the virus entry and risk for COVID-19 or disease severity.<sup>12,13</sup> The endothelial dysfunction in the setting of coronavirus infection may lead to the plaque instability, microvascular dysfunction, and thrombus formation in previously diseased coronary arteries. On the other hand, prolonged hypoxemia in this patient could be considered a predisposing factor for the development of MI.

Patient 2 experienced a presentation classic for acute ST-elevation myocardial infarction. The degree to which the SARS-COV-2 virus contributed to his coronary event is worth considering. The patient had a long-standing history of diabetes mellitus- and thus, he was at risk for coronary atherosclerosis. Viral illnesses, especially influenza, are recognized to contribute to coronary events.<sup>13</sup> The etiology of this association is the increased inflammatory response predisposing at-risk patients to plaque rupture and subsequent thrombosis.<sup>13</sup> In patients with risk factors for atherosclerotic coronary disease, the utility of various “cardioprotective” medications in preventing COVID-19-induced myocardial infarction has been controversial. As SARS-CoV-2 utilizes the angiotensin-converting enzyme 2 for infecting the host cell, controversy exists regarding

the safety of the use of angiotensin-converting enzyme inhibitors (ACEi), angiotensin receptor blockers (ARB) and mineralocorticoid antagonists, as these medications are known to upregulate angiotensin-converting enzyme 2.<sup>14</sup> Statin therapy is also known to play a role in upregulation of angiotensin-converting enzyme 2, which may be partially responsible for the cardiovascular protection elicited with this medication class.<sup>14</sup> However, in a retrospective case series, there were no significant differences in the severity of disease or mortality in patients taking an ACEi/ARB for hypertension.<sup>15</sup>

In the third case, we present a patient with severe COVID-19 infection who showed evidence of transient conduction disturbances with second-degree atrioventricular (AV) block. AV blocks are known to be an uncommon presentation of acute myocarditis in adults. Myocarditis is an inflammatory disease of the heart that often poses a diagnostic challenge due to the heterogeneity of presentation and a wide range of aetiologies. Viral infections have been widely credited as causative factors of myocarditis. Since the onset of the current pandemic, cases of myocarditis in patients with COVID-19 have been reported. The actual incidence of myocarditis is difficult to estimate as a tissue diagnosis with an endomyocardial biopsy is rarely obtained which is the gold standard for diagnosis in COVID-19 scenario.<sup>16</sup> It is possible that COVID-19 may have caused subclinical myocarditis leading to the aggravation of conduction abnormalities in this patient because she did not have any other overt evidence of myocardial involvement, with normal cardiac biomarkers. Moreover, ACE2 receptors are abundant in the heart and are present in multiple cell types, including macrophages, endothelial cells, smooth muscle cells, and cardiomyocytes.<sup>17</sup> Thus, another possibility is that isolated involvement of the AV node and infra-Hisian conduction system by SARS-CoV-2 may have caused transient AV block. The favorable outcome may have reflected recovery from the viral infection or the anti-inflammatory effects of the medications, or both. While cardiac magnetic resonance imaging (MRI) might have offered more confirmation to the diagnosis, it would not have altered our management.

In contrast to case 3 discussed above, patient 4 was a young COVID-19 positive male who was detected to have a complete heart block on the ECG. However, he was hemodynamically stable and asymptomatic except for the presence of symptoms suggestive of an influenza like illness. Complete AV block can occur as an isolated congenital anomaly. Patients with asymptomatic congenital CHB and a structurally normal heart may not develop significant change in hemodynamic status during periods of acute stress or infections. In such patients, the block is nearly always within the AV node and the subsidiary pacemaker is situated distal to the block, mostly within the lower part of the AV node or the bundle of His, resulting in normal QRS complexes like seen in the fourth patient's ECG when compared to the third patient's. Moreover, idionodal rate is in the range of 55-65 beats/min

that is in a slightly higher rate range than that usually associated with an acquired block as seen above.<sup>18</sup>

## CONCLUSION

COVID-19 is an evolving pandemic with dominant respiratory manifestations, however, due to the interaction with the cardiovascular system; cardiac manifestations/complications also feature in this disease. Significant concerns relating to COVID-19 and the cardiovascular system have been highlighted, with COVID-19 inducing multiple cytokines and chemokines resulting in vascular inflammation, plaque instability, myocardial inflammation and conduction abnormalities. Additionally, pre-existing cardiovascular disease (CVD) predisposes to COVID-19 infection with elevated risk of adverse outcomes. It is important for clinicians to be aware of such worrisome potential effects of SARS-CoV-2 infection on the cardiovascular system and to encourage future investigations and studies to further characterize the potential effects of this virus on the cardiovascular system.

*Funding: No funding sources*

*Conflict of interest: None declared*

*Ethical approval: Not required*

## REFERENCES

1. Guan WJ, Ni ZY, Hu Y, Liang WH, Ou CQ, He JX, et al. Clinical characteristics of coronavirus disease 2019 in China. *N Engl J Med.* 2020;382:1708-20.
2. Fried JA, Ramasubbu K, Bhatt R. The variety of cardiovascular presentations of COVID-19. *Circulation.* 2020;141(23):1930-6.
3. Xu Z, Shi L, Wang Y, Zhang J, Huang L, Zhang C, et al. Pathological findings of COVID-19 associated with acute respiratory distress syndrome. *Lancet Respir Med.* 2020;8(4):420-2.
4. Zheng YY, Ma YT, Zhang JY, Xie X. COVID-19 and the cardiovascular system. *Nat Rev Cardiol.* 2020;17(5):259-60.
5. Xiong TY, Redwood S, Prendergast B, Chen M. Coronaviruses and the cardiovascular system: acute and long-term implications. *Eur Heart J.* 2020;41(19):1798-800.
6. Clerkin KJ, Fried JA, Raikhelkar J, Sayer G, Griffin JM, Masoumi A, et al. COVID-19 and Cardiovascular Disease. *Circulation.* 2020;141(20):1648-55.
7. Schoenhagen P, Tuzcu EM, Ellis SG. Plaque vulnerability, plaque rupture, and acute coronary syndromes: (multi)-focal manifestation of a systemic disease process. *Circulation.* 2002;106(7):760-2.
8. Gupta MD, Qamar A, Girish MP, Safal S, Batra V, Basia D, Mandal SK, Yusuf J, Mukhopadhyay S, Bansal A. Bradyarrhythmias in patients with COVID-19: a case series. *Indian Pacing Electrophysiol J.* 2020;20(5):211-2.
9. Driggin E, Madhavan MV, Bikdeli B. Cardiovascular considerations for patients, health

- care workers, and health systems during the COVID-19 pandemic. *J Am Coll Cardiol.* 2020;75(18):2352-71.
10. Zhou F, Yu T, Du R. Clinical course and risk factors for mortality of adult inpatients with COVID-19 in Wuhan, China: a retrospective cohort study. *Lancet.* 2020;395:1054-62.
  11. Guzik TJ, Mohiddin SA, Dimarco AI. COVID-19 and the cardiovascular system: implications for risk assessment, diagnosis, and treatment options. *Cardiovasc Res.* 2020.
  12. Guo J, Huang Z, Lin L, Lv J. Coronavirus disease 2019 (COVID-19) and cardiovascular disease: a viewpoint on the potential influence of angiotensin-converting enzyme inhibitors/angiotensin receptor blockers on onset and severity of severe acute respiratory syndrome coronavirus 2 infection. *J Am Heart Assoc.* 2020;9(7):e016219.
  13. Zhou F, Yu T. Clinical course and risk factors for mortality of adult inpatients with COVID-19 in Wuhan, China: a retrospective cohort study. *Lancet.* 2020;395(10229):1054-62.
  14. South AM, Diz DI, Chappell MC. COVID-19, ACE2, and the cardiovascular consequences. *Am J Physiol Heart Circulat Physiol.* 2020.
  15. Li J, Wang X, Chen J, Zhang H, Deng A. Association of renin-angiotensin system inhibitors with severity or risk of death in patients with hypertension hospitalized for coronavirus disease 2019 (COVID-19) infection in Wuhan, China. *J Am Med Assoc Cardiol.* 2020.
  16. Janardhanan R. Myocarditis with very high troponins: risk stratification by cardiac magnetic resonance. *J Thorac Dis.* 2016;8:E1333-6.
  17. Zisman LS. ACE and ACE2: a tale of two enzymes. *Eur Heart J.* 2005;26:322-4.
  18. Schamroth L. An introduction to electrocardiography. *Academic Medic.* 1964;39(10):977.

**Cite this article as:** Munirathnam M, Ravindranath A, Ramaiah M, Kadloor P. A cardiac manifestation in patients with COVID-19: a case series. *Int J Adv Med* 2021;8:124-30.