

## Case Report

# Survival from paraquat induced renal impairment in a 17 years old male

Medo M. Kuotsu\*, N. Biplab Singh, Nyamnyi Konyak, Vikie-o Khruomo, Senjele Kath, Deepak Dhakal, Ashwini Namanandi

Department of Medicine, Regional Institute of Medical Sciences, Imphal, Manipur, India

**Received:** 08 November 2020

**Revised:** 10 December 2020

**Accepted:** 07 January 2021

### \*Correspondence:

Dr. Medo M. Kuotsu,

E-mail: medoGeorge@rocketmail.com

**Copyright:** © the author(s), publisher and licensee Medip Academy. This is an open-access article distributed under the terms of the Creative Commons Attribution Non-Commercial License, which permits unrestricted non-commercial use, distribution, and reproduction in any medium, provided the original work is properly cited.

## ABSTRACT

N, N'-dimethyl-4, 4'-bipyridinium dichloride (paraquat) is a herbicide commonly used in India that leads to fatal outcome on ingestion. Paraquat interferes in the intracellular electron transfer systems inhibiting the reduction of NADP to NADPH resulting in accumulation of superoxide radical causing lipid cell membranes destruction leading to various organ damage. Life threatening effects such as acute kidney injury as paraquat elimination is mainly by kidney, acute respiratory distress syndrome and multi-organ failure are the causes of mortality in paraquat poisoning. There is no specific antidotes for paraquat poisoning so prevention and aggressive decontamination remains the mainstay of management in case of exposure or ingestion. Paraquat poisoning presentation may vary in cases depending on the amount of paraquat consumed and thus the outcome. Here we report a case of a 17 years old male who presented with acute kidney injury following ingestion of paraquat in a suicidal attempt. In our case, induced vomiting of the stomach content readily after ingestion of the poison, early haemodialysis, use of immunosuppression such as methylprednisolone, cyclophosphamide and antioxidants such as acetylcysteine, Vitamin C and Vitamin E as free radical scavenging agent, supportive measures such as adequate hydration and antibiotics might have helped in the patient's survival. The case fatality remains very high in paraquat poisoning till date owing to lack of effective treatment options.

**Keywords:** Paraquat, Poisoning, Kidney failure, Haemodialysis, Prognosis

## INTRODUCTION

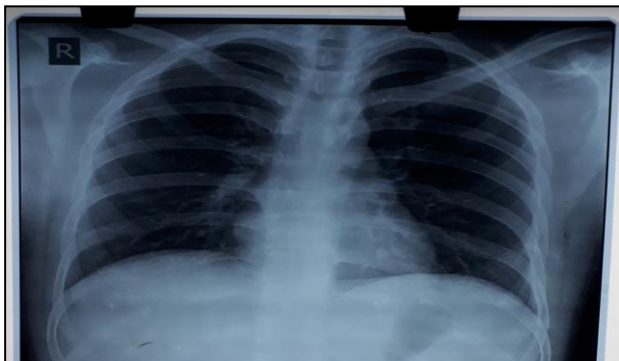
Paraquat is a rapidly-acting herbicide that causes fatal poisoning when ingested.<sup>1</sup> Suicidal ingestion of paraquat continues to be a major public health concern in Asia and Pacific nations. As no specific antidote to paraquat poisoning is available, aggressive decontamination to prevent further absorption remains the mainstay of supportive management.<sup>2</sup> Paraquat interferes with the intracellular electron transfer systems inhibiting the reduction of NADP to NADPH which results in accumulation of superoxide radical causing lipid cell membranes destruction leading to acute kidney injury

(AKI), acute respiratory distress syndrome (ARDS) and multi organ dysfunction syndrome (MODS).<sup>3</sup> Paraquat is mainly eliminated by kidney leading to AKI. Paraquat ingestion even in small quantity can cause severe damage to lung and kidney.<sup>4</sup>

## CASE REPORT

A 17-year-old male presented to RIMS Hospital Imphal in emergency department with an alleged history of consumption of 10 ml of paraquat (Gramoxone 24%) 28 hours ago following a familial dispute. The patient had chief complaints of multiple episode of vomiting, nausea,

sore throat and irritation on swallowing. There was no history of abdominal pain, seizures, loose stool or loss of consciousness. History of any prior psychological disorders or addictive behavior was ruled out. On examination the patient recorded blood pressure of 110/70 mmHg, oxygen saturation 95% at room air, pulse rate of 94/minute, respiratory rate 26 per minute and axillary temperature was 98.6 °F. On systemic examination patient was conscious, oriented to time, place and person with normal higher mental function. His pupils were bilaterally equally reacting to light and no focal neural deficit was seen. Bilateral lung field was clear on auscultation with no added sounds. Cardiovascular examination revealed normal S1S2, no rub, gallop or murmur. Abdomen was soft, non tender with normal audible bowel sounds. Chest X-ray showed no remarkable findings. Electrocardiogram showed sinus tachycardia. Initial arterial blood gas showed mild alkalemia: pH 7.48, partial pressure of oxygen 73.0 mm Hg, partial pressure of carbon dioxide 36.7 mm Hg, bicarbonate 26.8 mEq/L, and lactate 0.9 mmol/L. On laboratory examination the patient was found to have a serum creatinine of 1.30 mg/dL and normal urine output. Over the next 24 hours renal function worsened with serum creatinine rising to 1.90 mg/dL and within 48 hours serum creatinine reached 2.20 mg/dL with hypokalemia. Nephrology consultation was done and patient received a session of haemodialysis. The patient's serum creatinine levels steadily normalized and recorded 0.9 mg/dL on day 7.



**Figure 1: Normal chest X-ray posteroanterior view indicating no pulmonary involvement in our case.**

Liver dysfunction with hyperbilirubinemia was observed on day 3 with total bilirubin 7.1 mg%, and conjugated bilirubin 1.6 mg%. Serum transaminases and alkaline phosphatase showed moderate elevation. By day 7 serum total bilirubin improved to 1.0 mg%, and conjugated bilirubin 0.3 mg% and enzymes within normal limit. Urine routine and microscopic examination reported as normal. The patient was managed with adequate hydration, injection methylprednisolone 1 g in 200 ml normal saline 24 hourly for 3 days followed by maintenance dose of oral prednisolone, cyclophosphamide 15 mg/kg/day in three divided doses in 200 ml of normal saline over 2 hours for 3 days, injection N-acetylcysteine 1.2 g 8 hourly for 8 days, injection Ceftriaxone 1g 12 hourly for 5 days,

injection rabeprazole 20mg 12 hourly for 7 days and other supportive measures such as use of antioxidant in the form of Vitamin C and Vitamin E. Gastroenterologist opinion was sought to exclude possible esophageal strictures but an upper gastrointestinal (GI) endoscopy was deferred in view of the risk of esophageal rupture however on day 5 the patient was started on a liquid diet. The patient was discharged after 9 days of hospitalization with serum urea of 39 mg/dL and serum creatinine 0.7 mg/dL with normal stable vitals and no symptomatic complaints. The patient was advised for monthly review thereafter and continued to remain healthy till date after a lapse of 1 year.

## DISCUSSION

Paraquat interferes with the intracellular electron transfer systems inhibiting the reduction of NADP to NADPH which result in the accumulation of superoxide radical which causes destruction of lipid cell membranes.<sup>3</sup> Paraquat ingestion resulted in inflammation of oral mucosa and throat, liver dysfunction resulting in hyperbilirubinemia and acute kidney injury.<sup>5</sup> Paraquat poisoning can cause AKI without any signs and symptoms indicating silent renal impairment without respiratory involvement as the ingested paraquat may get eliminated by the kidney without significant metabolism, where the concentration of paraquat might have reached a high level.<sup>6</sup> As there is no specific antidote for paraquat poisoning, supportive treatment in the form of early fluid resuscitation, steroid pulse therapy (methylprednisolone) and cyclophosphamide to prevent pulmonary fibrosis, hemodialysis to eliminate paraquat from the system and gastric decontamination remains the mainstay of management.<sup>5,7</sup> Oxygen supplementation enhances the toxicity of Paraquat by providing more electron acceptors and so should be limited in lower concentrations in case patient presents with hypoxic status.<sup>8-11</sup>

In our study, patient's history with documenting the poison ingested as paraquat, clinical examination was vital in the diagnosis as serum levels of paraquat could not be measured due to unavailability of the test done in the region. Low dose of paraquat intake, vomiting the content of stomach immediately after ingestion, adequate fluid therapy, hemodialysis and use of antioxidant might have helped in the patient's survival. However, more studies and research are required to establish an effective treatment for paraquat poisoning.

## CONCLUSION

Paraquat consumption is a rare agent of suicidal poisoning, resulting in very high morbidity and mortality. Acute kidney injury is a common complication in paraquat poisoning and needs to be identified and treated promptly. Immediate and adequate interventions and hemodialysis has undeniable role in management. There is no specific antidote for paraquat poisoning and the treatment remains supportive.

*Funding: No funding sources*

*Conflict of interest: None declared*

*Ethical approval: Not required*

## REFERENCES

1. Fairshter RD, Wilson AF. Paraquat poisoning: manifestations and therapy. *Am J Med.* 1975;59(6):751-3.
2. Safaei Asl A, Dadashzadeh P. Acute kidney injury in patients with paraquat intoxication; a case report and review of the literature. *J Renal Inj Prev.* 2016;5(4):203-06.
3. Suntres ZE. Role of antioxidants in paraquat toxicity. *Toxicol.* 2002;180(1):65-77.
4. Saravu K, Sekhar S, Pai A, Barkur AS, Rajesh V, Earla JR. Paraquat – A deadly poison: Report of a case and review. *Indian J Crit Care Med.* 2013;17:182-4.
5. Tominack R, Pond S. *Herbicides. Goldfrank's toxicologic emergencies.* 7th ed. New York: McGraw-Hill. 2002;1393-410.
6. Houzé P, Baud FJ, Mouy R, Bismuth C, Bourdon R, Scherrmann JM. Toxicokinetics of paraquat in humans. *Hum Exp Toxicol.* 1990;9(1):5-12.
7. Khosya S, Gothwal S. Two Cases of Paraquat Poisoning from Kota, Rajasthan, India. *Case Rep Crit Care.* 2012;2012.
8. Agarwal R, Srinivas R, Aggarwal AN, Gupta D. Experience with paraquat poisoning in a respiratory intensive care unit in North India. *Singapore Med J.* 2006;47:1033-7.
9. Singh S, Bambery P, Chaudhry D, Makharia G, Kakkar N, Singh D. Fatal paraquat poisoning: Report of two cases. *J Assoc Physicians India.* 1999;47:831-2.
10. Böhrer J, Riegel W, Keller E, Logemann E, Just H, Schollmeyer PJ. Continuous arteriovenous haemoperfusion (CAVHP) for treatment of paraquat poisoning. *Nephrology, dialysis, transplantation: Official publication of the European Dialysis and Transplant Association. Euro Renal Association.* 1992;7:875-8.
11. Lin JL, Leu ML, Liu YC, Chen GH. A prospective clinical trial of pulse therapy with glucocorticoid and cyclophosphamide in moderate to severe paraquat-poisoned patients. *Am J Respir Crit Care Med.* 1999;159:357-60.

**Cite this article as:** Kuotsu MM, Singh NB, Konyak N, Khruomo VO, Kath S, Dhakal D et al. Survival from paraquat induced renal impairment in a 17 years old male. *Int J Adv Med* 2021;8:300-2.