International Journal of Advances in Medicine
Karamoy EA et al. Int J Adv Med. 2021 Feb;8(2):270-275
http://www.ijmedicine.com
pISSN 2349-3925 | eISSN 2349-3933
DOI: https://dx.doi.org/10.18203/2349-3933.ijam20210274

Case Report

Systemic sclerosis: a rare presentation

Elvi Aprillia Karamoy[1]*, Jason Raymond Hotama[1], Ketut Suryana[1], Novitasari[2]

[1]Department of Internal Medicine, [2]Department of Anatomical Pathology, Wangaya Regional General Hospital, Denpasar, Bali, Indonesia

Received: 30 November 2020
Accepted: 30 December 2020

***Correspondence:**
Dr. Elvi Aprillia Karamoy,
E-mail: elvi.aprillia@gmail.com

Copyright: © the author(s), publisher and licensee Medip Academy. This is an open-access article distributed under the terms of the Creative Commons Attribution Non-Commercial License, which permits unrestricted non-commercial use, distribution, and reproduction in any medium, provided the original work is properly cited.

ABSTRACT

Systemic sclerosis or so called scleroderma is an uncommon autoimmune inflammatory and fibrotic connective tissue disease involving multiple organs. The etiology of systemic sclerosis is currently unknown and its pathogenesis is only partially understood. Skin thickening and Raynaud's phenomenon are the most common symptoms. Although systemic sclerosis is uncommon, it is associated with high morbidity and mortality. In this report, we present a case of a-43-year-old man with the complaint of weakness, tightening of the skin over the fingers, tingling in the soles of feet, nausea and significant weight loss. Laboratory examinations revealed positive ANA test, but negative anti topoisomerase I (anti-Scl-70), and anticentromere antibody.

Keywords: Systemic sclerosis, Scleroderma, Sclerodactyly, Skin thickening, Autoimmune

INTRODUCTION

Systemic sclerosis (SSc) or so called Scleroderma is an uncommon systemic autoimmune disease that causes inflammatory and fibrotic connective tissue, with multiorgan system involvement.[1,3,4,5,9] The term "scleroderma" comes from the Greek words. "Scleros" (hard or indurated) and "derma" (skin).[2]

The prevalence has been reported to be 240 per million and the incidence rate is 20 per million per year.[9] The peak age of onset is between 20 and 50 years.[5] Women are more commonly affected than men (4.5 fold higher than men).[1,5,9] But male gender has been associated with severe disease course and higher mortality.[1,5]

The pathophysiology of systemic sclerosis is complex, and not completely understood.[3,8] It is characterized by widespread tissue fibrosis of the skin and internal organs, vascular abnormalities, and autoimmunity.[3,4]

Based on skin thickening distribution, there are two subtypes of systemic sclerosis (SSc): limited cutaneous systemic sclerosis (lcSSc) and diffuse cutaneous systemic sclerosis (dcSSc).[1-9]

Clinical signs of systemic sclerosis can be varied. It can affect the skin and internal organs such as the lungs, heart, kidneys, gastrointestinal tract, and musculoskeletal system.[1,4,8]

Skin involvement usually develops at the early stage of the disease and is preceded by Raynaud's phenomenon. Skin becomes puffy, the swollen finger that is followed by the thickening of the skin leading to sclerodactyly.[4,9]

There is no gold standard test to diagnosis SSc. The diagnosis usually based on clinical feature and physician judgment.[1,5,7] The 2013 American College of Rheumatology (ACR)/ European League Against Rheumatism (EULAR) classification criteria for systemic sclerosis are a useful aid for clinicians. However, it must be remembered that these are not diagnostic criteria, but are intended to facilitate clinical research.[1,5]

Treatment of autoimmune diseases is a challenge for doctors and new therapeutic options are constantly being sought. Since the pathogenesis of SSc remains unclear, treatment is solely based on complications that occur in each organ.[5,8] Therefore it is important to manage SSc with close supervision of multidisciplinary team. Immunosuppression is usually prescribed in patients with early diffuse systemic skin sclerosis to slow the disease progression. Other treatment regiments are including proton-pump inhibitors (PPIs) for gastrointestinal, calcium channel blocker for raynaud's phenomenom, non-steroidal anti-inflammatory drugs (NSAIDs) for the pain, and angiotensin-converting enzyme (ACE) inhibitors for hypertension.[2,4,5]

CASE REPORT

A 43-year old man came to the emergency room (ER) at Wangaya Hospital with the chief complaint of progressive weakness since a month before the hospital admission.

He also complaints skin tightening over the fingers, tingling in the soles of feet, musculoskeletal pain, nausea, and 10 kg weight loss over the past one month. There were no history of dyspnea, dysphagia, and Raynaud's phenomenon.

During the admission, the patient was conscious with normal vital signs (blood pressure of 110/70 mmHg, heart rate of 78 bpm, respiratory rate of 21×/minutes, and axillar temperature of 36,8^{0}C.



Figure 1: Skin thickening.

Physical examination revealed skin thickening, sclerodactyly, and puffy fingers (sausage fingers) on both patient's hand. The patient also displayed limb weakness with difficulty to clench fists, especially on the left hand. Other symptoms related to SSc such as telangiectasis, microstomia, raynaud's phenomenon, fingertip lesions were not present.



Figure 2: The patient has difficulty to clench his fists, especially his left hand.

Laboratory results showed microcytic hypochromic anemia (hemoglobin 10,6 g/dL, mean corpuscular volume 65,6 fL, mean corpuscular haemoglobin 22,9 pg), thrombocyte count 434.000/uL, leukocyte count of 12.260/uL, blood glucose 150 mg/dL, ALT 38 U/L, AST 55 U/L, urea 24 mg/dL, creatinine serum of 0,6 mg/dL, Albumin 2,9 g/dL, sodium of 127 mmol/L, potassium 3,8 mmol/L, Chloride 88 mmol/L, TSHs 0,63 uIU/mL, FT4 1,8 ng/dL, rapid covid non-reactive, HIV is non-reactive.

Chest and pulmonary X-rays were within normal limits. CT scan at this time showed no signs of bleeding, infarction, and/or intracranial space occupying lesions. AP/Lateral lumbosacral radiograph shows neither compression fractures nor listhesis. No lumbar spondylosis was seen. Ultrasound examination revealed mild splenomegaly.

Examination of ANA (IF) speckled pattern, positive titer>1:1000. ANA profile [RNP/Sm +++, Sm o, SS-A native (SSA) +++, Ro-52 recombinant (52) +++, SS-B +, Scl-70 (Scl) o, centromere B (CB) o, dsDNA (DNA) o]

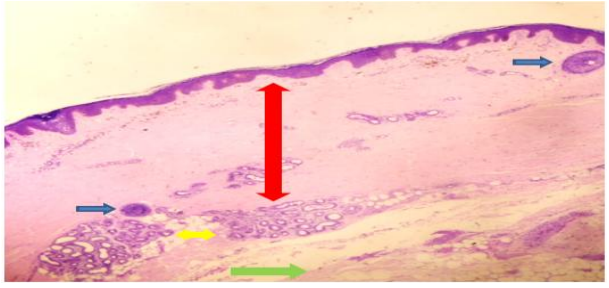

Figure 3: The dermis appears to show a clear sclerohyaline form, creating a relatively large gap (red line) between the epidermis and the skin adnexa. The eccrine glands (yellow line) can still be observed in the deep dermis near the subcutaneous fat. (green line). The hair follicle (blue line) can be found at a greatly decreased number.

Histological analysis of a skin biopsy showed conventional morphology showing generalized melanosis, extensive sclerohyaline in the dermis, decreased to the absence of skin adnexa, and fibrosis of small blood vessels walls. (Figure 3-6)

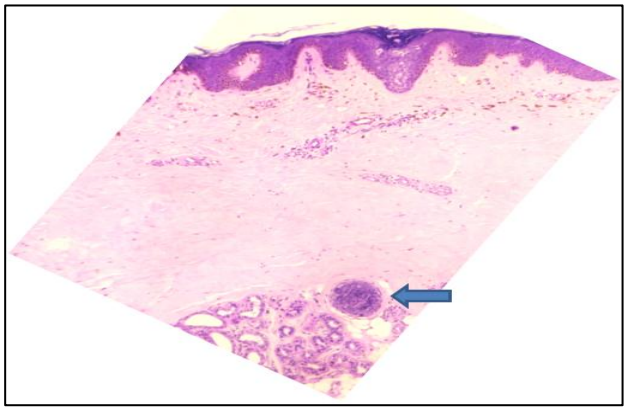

Figure 4: The hair follicle (blue line) can be found at a greatly decreased number and largely separated one with another.

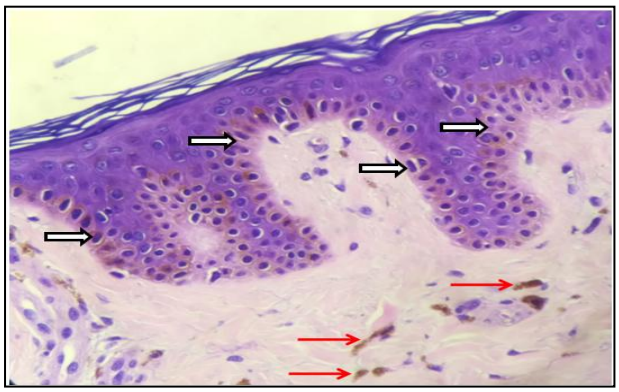

Figure 5: Epidermis with a thin keratin layer, partly with an atrophic epidermal focus. Melanocytes in the basal layer (white line) are visible, but without atypia. Melanin pigment shows an increase (red line).

Patient was diagnosed SSc because of tightening skin, sclerodactyly, positive ANA test, and the findings in histopathologic examination.

The patient was admitted to the hospital and treated by internist and neurologist with sodium chloride 0,9% 1500 mL per 24 hours, esomeprazole 40 mg injection every 24 hours, ondansetron 4 mg injection every 8 hours, methylprednisolone 62,5 mg injection every 12 hours, mecobalamin 1 tablet every 12 hours per oral, gabapentin 1 tablet every 12 hours per oral.

After 10-day treatment in our hospital, the patient still has been feeling weakness and unable to walk. We referred the patient to central public hospital for sub-specialistic treatment.

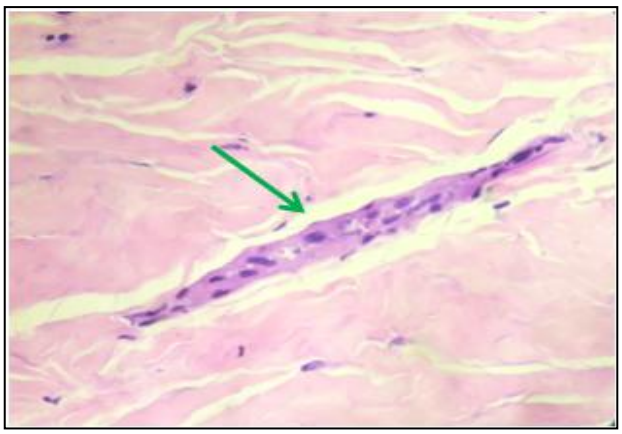

Figure 6: Small blood vessels with the fibrotic appearance of the tunica intima (green line).

DISCUSSION

Systemic sclerosis (Scleroderma) is an autoimmune disease, in which antibodies invade blood vessels and connective tissue, which is characterized by fibrosis of the skin and internal organs and vascular abnormalities.[3,4]

There are 2 major subtypes in Systemic Sclerosis, based on the extend of skin involvement:

Limited systemic sclerosis (lcSSc) which usually affects only the skin, although it can spread to muscles, joints and bones. It has slow progression, and Raynaud's phenomenon starts long before the occurrence of other symptoms.[1,6,8] CREST syndrome (calcinosis, raynaud's phenomenon, esophageal dysmotility, sclerodactyly, telangiectasia) is a term used to describe this subset of scleroderma.[5]

Diffuse systemic sclerosis (dcSSc), the most serious form of this disease. It has rapid progression, high morbidity and poor prognosis due to early and more severe multiorgan involvement.[1,2] Its affects the skin, muscles, joints, blood vessels, lungs, kidneys, heart and other organs.[1,3] Raynaud's phenomenon may appear after other symptoms have already occurred.[1,6,8]

CREST (calcinosis, raynaud's phenomenon, esophageal dysfunction, Sclerodactyly and Telangiectasia).[10-16]

Calcinosis is a pathological calcification of soft tissue. Deposits of calcium hydroxyapatite crystals in skin, soft tissue, or muscle may be subclinical. When symptomatic, there will be aches and pains. Calcinosis can form ulcers, secrete pale white compounds and develop secondary infections. There is an intermittent inflammatory reaction at the site of calcinosis.[11]

Raynaud's phenomenon is characterized by periodic blood loss to various parts of the body, especially the fingers, toes, nose and / or ears after exposure to cold and causes a tingling sensation of numbness and / or pain. This can lead

to ulceration and necrosis of the fingertips and in some severe cases, amputation of the affected finger.[12,13]

Esophageal dysmotility. Dysmotility is a common occurrence, especially hypomotility in 75-86% of patients with CREST syndrome. Lower esophageal dysmotility causing heartburn and dysphagia can occur in patients with erosive esophagitis.[14] Complications of gastroesophageal reflux, namely Barrett's esophagitis, malignant transformation of esophageal adenocarcinoma due to Barrett's esophagitis, have also been documented in scleroderma patients.[15]

Sclerodactyly means thickening of the skin of the fingers and toes. Three phases of skin changes appear in scleroderma: the edematous phase, the indurative phase and the atrophic phase. Early in scleroderma puffy edema appears on the fingers and there may be morning stiffness or arthralgia. The edematous phase is usually short. Indurative phase, the skin becomes thick, looks shiny, skin folds disappear and tighten, there may be erythema and itching. At the end of the course of scleroderma, the skin becomes brittle and saggy, often entering an atrophic phase. In patients with limited scleroderma, skin changes occur slowly, over years, usually distal to the elbows and knees, although they can involve the face and neck.[16]

Telangiectasia is a lesion formed by a cluster of dilated blood vessels. In scleroderma patients, telangiectasia occurs on the face, upper body and hands. It may also occur on mucosal surfaces (lips) and along the gastrointestinal tract (recurrent gastrointestinal bleeding) and may be asymptomatic.[10]

Although cutaneous manifestation, such as Raynaud's Phenomenon and skin thickening (cutaneous sclerosis) are the cardinal manifestations, it is not uncommon for patients came with a variety of symptoms. In some patients, organ- based manifestations of the disease are observed, which might include lung fibrosis, pulmonary arterial hypertension, renal failure, cardiac impairment (usually with accelerated- phase hypertension and a thrombotic microangiopathy clinical picture), or gastrointestinal complications.[1,4,8,10,11]

There is no gold standard test to diagnosis SSc. The diagnosis usually based on clinical feature, and physician judgment.[1,5,7] The 2013 American College of Rheumatology (ACR)/ European League Against Rheumatism (EULAR) classification criteria for systemic sclerosis are a useful aid for clinicians. However, it must be remembered that these are not diagnostic criteria, but are intended to facilitate clinical research.[1,5] This involves meeting a number of criteria for clinical features, antibodies and nailfold capillaroscopy.[7] In this case, there is skin thickening of the fingers of both hands with a score of 9, and this met the criteria for systemic sclerosis.[3] Patient difficult to close hand into a fist, especially his left hand.

In addition, the patient also feels weakness, nausea, and tingling in the soles of the feet, as well as weight loss. About 75% to 90% of patients have gastrointestinal involvement, such as heartburn, nausea, vomiting, bloating, difficulty swallowing, diarrhea, and / or constipation. Weight loss can occur and is often associated with reduced appetite or food intake.[8]

Table 1: Current classification of SSc.

Item	Sub-items	Score
Skin thickening of the fingers of both hands extending proximal to the metacarpophalangeal joints (sufficient criterion)	-	9
Skin thickening of the fingers (only count the higher score)	Puffy fingers	2
	Sclerodactyly of the fingers	4
Fingertip lesions (only count the higher score)	Digital tip ulcers	2
	Fingertip pitting scars	3
Telangiectasis	-	2
Abnormal nailfold capillaries	-	2
Pulmonary artery hypertension and/ or interstitial lung disease (maximum score is 2)	Pulmonary artery hypertension	2
	Interstitial lung disease	2
Raynaud's phenomenon	-	3
Systemic sclerosis-related autoantibodies (maximum score is 3)*	Anticentromere	3
	Anti-topoisomerase I (anti-Scl-70)	
	Anti-RNA polymerase III	

The criteria are not applicable to patients with skin thickening sparing the fingers or to patient who have scleroderma-like disorder that better explains their manifestations (such as nephrogenic sclerosing fibrosis, generalized morphea, eosinophilic fascitis, scleredema diabeticorum, scleromyxedema, erythromyalgia, porphyria, lichen sclerosis, graft-versus-host disease, diabetic chierarthropaty. A total score of ≥9 points is required for patients to be classified as having Systemic Sclerosis.*Any antibody = 3 points but can not have more than 3 points (very rare to have two antibodies)

Regional sensory symptoms may appear, such as neuropathy, trigeminal or glossopharyngeal neuralgia. Stiffness in the morning, joint pain, muscle weakness or fatigue can be reported, especially in the early stage diffuse systemic skin sclerosis.[4,8] Estimate of skeletal myopathy frequency vary approximately from 5 to 96%.[8]

In this patient, ANA test is positive (Titer >1:1000) with speckled pattern, but Anticentromere Antibody (ACA), anti-topoisomerase I [anti Scl-70] was not found (negative).

ANA (anti-nuclear antibody) is frequently found in autoimmune disease.[6] Approximately 90 to 95% of people with systemic sclerosis have a positive antinuclear Antibody (ANA) test.[5,6,8]

SSc-specific auto-antibodies is a good predictor to systemic sclerosis, include Anti-centromere antibodies (ACA), Anti-Scl-70 (target: DNA Topoisomerase I), and Anti-RNA-Polymerase III (ARA).[6,8] Anti-centromere antibody (ACA), found in about 50-90% of scleroderma patients, and 82-96% of patients with CREST syndrome, the specificity is 95%. The Scl-70 antibody (anti-topoisomerase I) is associated with diffuse scleroderma, early internal organ involvement, and a poor prognostic marker.[17] But 40% of people with systemic sclerosis don't have any Scleroderma specific antibodies.

The results of skin biopsy support the clinical diagnosis of scleroderma with conventional morphology showing generalized melanosis, extensive sclerohyaline in the dermis, decreased to the absence of skin adnexa, and fibrosis in the walls of small blood vessels.

Treatments for this patient are symptomatic. We gave him esomeprazole and ondansetron for his esophageal reflux, the patient was also prescribed methylprednisolone to inflammatory components. Mecobalamin and gabapentin are the therapy for this patient to treat nerve disorders.

Comprehensive approach was given to this patient, including supportive treatment and organ specific medications, aimed at preventing complications of the disease.[18]

For patients with Raynaud's phenomenon, non-pharmacologic treatments include keeping the body and especially the hands and feet warm during cold weather by wearing gloves, gloves, stockings, and other protective clothing; tobacco smoking cessation. Pharmacologic interventions are indicated after nonpharmacological interventions have failed to reduce the frequency and severity of attacks. Slow-releasing calcium dihydropyridines or long-acting channel blockers such as nifedipine (10 to 30 mg orally three times daily) or amlodipine (2.5 to 10 mg orally per day) are first-line treatment options.[19]

Esophageal reflux can be treated with proton pump inhibitors such as omeprazole (20 mg orally per day) or esomeprazole (40 mg intravenous per day). Immunomodulatory agents may be used depending on the specific organ or system involved.[18]

Renal crisis is characterized by severe hypertension, renal failure and macroangiopathic hemolytic anemia. High doses of glucocorticoids are associated with an increased risk of kidney crisis. If a patient with systemic sclerosis requires steroids, low doses such as prednisone 15 mg / day or less (or its equivalent) are recommended to avoid this renal crisis. Angiotensin converting enzyme (ACE) inhibitors are used earlier to prevent progression of kidney disease once a patient has signs of kidney crisis. ACE inhibitors have not been shown to reduce the incidence of kidney crises.[18]

Table 2: Treatment options for SSc.[4,5]

Organ system	Clinical manifestation	Examples of treatments
Skin	Scleroderma	Immunosuppressive therapy (e.g. methotrexate and mycophenolate mofetil) for progressive skin thickening in the context of early diffuse cutaneous disease
Musculoskeletal	Inflammatory arthritis	Systematic and intensive physiotherapy or occupational therapy, non-steroidal anti-inflammatory drugs and low-dose daily prednisolone
Cardiovascular	Heart failure	Usual drug therapies (e.g. angiotensin-converting enzyme inhibitors and diuretics)
	Inflammatory cardiac disease	Immunosuppressive therapy (e.g. corticosteroid and/or cyclophosphamide)
Respiratory	Pulmonary artery hypertension	Endothelin receptor antagonists, phosphodiesterase type 5 inhibitors, prostacyclin analogues
	Intertitial lung disease	Soluble guanylate cyclase agonists, immunosuppressive therapy (e.g. cyclophosphamide and mycophenolate mofetil), HSCT (Autologous Hematopoietic Stem Cell Transplantation)
Gastrointestinal	Gastroesophageal reflux disease	Lifestyle advice, proton-pump inhibitors

Continued.

Organ system	Clinical manifestation	Examples of treatments
Peripheral Vascular	Raynaud's phenomenon, digital ulcers and critical ischaemia	Calcium-channel blockers, phosphodiesterase type 5 inhibitors, angiotensin II receptor blockers, endothelin receptor antagonists, prostacyclin analogues (e.g. intravenous iloprost), wound care for digital ulcers, antibiotic therapy for infected ulcers, surgical debridement or amputation
Renal	Scleroderma renal crisis	Angiotensin-converting enzyme inhibitors

The prognosis of SSc depends on the severity of internal organs involved. lcSSc has a better prognosis because internal organ involvement is late and slow. lcSSc has a 10-year survival over 90%. Meanwhile, dcSSc patients have a poor prognosis due to fast progression and internal organs involvement.[8]

CONCLUSION

Systemic sclerosis (also called scleroderma) is an uncommon autoimmune inflammatory and fibrotic connective tissue disease that can involve multiple organs. The involvement of multiple organs makes systemic sclerosis a multidisciplinary disease and require a holistic approach, so many hospital-based specialists are involved in patient care. SSc significantly can reduce the quality of life, has high morbidity and mortality. Although there is no known cure, there are a number of effective treatments for many of the organ-based complications. Immunosuppressants is usually prescribed in patients with early diffuse cutaneous systemic sclerosis.

ACKNOWLEDGEMENTS

The authors acknowledge and thankful for the patient and family, doctors, nurses, and our hospital superintendent.

Funding: No funding sources
Conflict of interest: None declared
Ethical approval: Not required

REFERENCES

1. Ingegnoli F, Ughi N, Mihai C. Update on the epidemiology, risk factors, and disease outcomes of systemic sclerosis. Best Pract Res Clin Rheumatol. 2018;32(2):223–40.
2. Sticherling M. Systemic sclerosis – the dermatological perspective. J Ger Soc Dermatol. 2019;17(7):716–28.
3. Kucharz EJ, Kopeć-Mędrek M. Systemic sclerosis sine scleroderma. Adv Clin Exp Med. 2017;26(5):875–80.
4. Denton CP, Khanna D. Systemic sclerosis. Lancet [Internet]. 2017;390(10103):1685–99.
5. Schinke S, Riemekasten G. Systemic sclerosis. Internist. 2019;60(12):1251–69.
6. Van den Hombergh WMT, Carreira PE, Knaapen-Hans HKA, van den Hoogen FHJ, Fransen J, Vonk MC. An easy prediction rule for diffuse cutaneous systemic sclerosis using only the timing and type of first symptoms and auto-antibodies: Derivation and validation. Rheumatol. 2016;55(11):2023–32.
7. Johnson SR. New ACR EULAR guidelines for systemic sclerosis classification. Curr Rheumatol Rep. 2015;17(5):1–8.
8. Sobolewski P, Maślińska M, Wieczorek M, Łagun Z, Malewska A, Roszkiewicz M, et al. Systemic sclerosis - Multidisciplinary disease: Clinical features and treatment. Reumatologia. 2019;57(4):221–33.
9. Pearson DR, Werth VP, Pappas-Taffer L. Systemic sclerosis: Current concepts of skin and systemic manifestations. Clin Dermatol. 2018;36(4):459–74.
10. Horner KL, Raugi GJ, Wemple MA. CREST syndrome. eMedicine Dermatology. 2008; Available at: http://www.emedicine.medscape. com. Accessed on 20 March 2020.
11. Tangri N, Young BM. Soft-tissue infection and underlying calcinosis of CREST syndrome. Canad Medic Assoc J. 2006;175(9):1060–1.
12. Herrick AL. Review: Pathogenesis of Raynaud's phenomenon. Rheumatology. 2005;44:587–96.
13. Sunderkotter C, Riemekasten G. Pathophysiology and clinical consequences of Raynaud's phenomenon related to systemic sclerosis. Rheumatology. 2006;45:iii33.
14. Sheehan NJ. Dysphagia and other manifestations of oesophageal involvement in the musculoskeletal diseases. Rheumatology. 2008;47(6):746–52.
15. Pitrez EH, Bredemeier M, Xavier RM, Capobianco KG, Restelli VG, Vieira MV, et al. Oesophageal dysmotility in systemic sclerosis: comparison of HRCT and scintigraphy. Br J Radiol. 2006;79:719–24.
16. Jones J, Brenner C, Chinn R, Bunjer CB. Pictorial review: Radiological associations with dermatological disease. Br J Radiol. 2005;78:662–71.
17. Hu PQ, Fertig N, Medsger TA, Wright TM. Molecular Recognition Patterns of Serum Anti-DNA Topoisomerase I Antibody in Systemic Sclerosis. J Immunol. 2004;173(4):2834–41.
18. Lt. John Scott Donoughe, DO, MPAS, PA-C. Scleroderma: Quick Recertification Series. 2018;(10):53-4.
19. Wigley FM, Korn JH, Csuka ME, et al. Oral iloprost treatment in patients with Raynaud's phenomenon secondary to systemic sclerosis: a multicenter, placebo-controlled, double-blind study. Arthritis Rheum. 1998;41(4):670-7.

Cite this article as: Karamoy EA, Hotama JR, Suryana K, Novitasari. Systemic sclerosis: a rare presentation. Int J Adv Med 2021;8:270-5.