

## Case Report

# Ascites et causa hepatic cirrhosis

Jason Raymond Hotama\*, Ketut Suryana

Internal Medicine Department in Wangaya Regional General Hospital, Denpasar, Bali, Indonesia

**Received:** 07 January 2021

**Accepted:** 10 February 2021

**\*Correspondence:**

Dr. Jason Raymond Hotama,

E-mail: Jasonhotama@yahoo.com

**Copyright:** © the author(s), publisher and licensee Medip Academy. This is an open-access article distributed under the terms of the Creative Commons Attribution Non-Commercial License, which permits unrestricted non-commercial use, distribution, and reproduction in any medium, provided the original work is properly cited.

### ABSTRACT

Cirrhosis of the liver is the end result of irreversible hepatocellular injury causing fibrosis and nodular regeneration of the liver. One of the complications of hepatic cirrhosis is ascites. The most common causes of ascites in liver cirrhosis are portal hypertension, hypoalbuminemia and kidney dysfunction which will result in the accumulation of the fluid in the peritoneum. Ascites in cirrhosis is truly important as it is highly associated with mortality, and significantly requires liver transplantation as a therapeutic option. This article reports an SIA woman, 68 years old, diagnosed with ascites e.c hepatic cirrhosis who was treated due to an enlarged abdomen. The patient received diuretic therapy but there were no significant changes. The patient also received an ascitic fluid puncture procedure. Cirrhosis of the liver is a condition where the extracellular matrix or scar tissue accumulates as a response to acute or chronic liver injury. Ascites is the most likely complication occurred in cirrhosis patients. The occurrence of ascites in cirrhosis is very important which is correlated to the patient's mortality. Adequate ascites therapy will levitate the quality of life for cirrhosis patients and prevent complications.

**Keywords:** Ascites, Hepatic cirrhosis, Complications

### INTRODUCTION

Cirrhosis of the liver is a chronic liver disease that triggers a diffuse process of nodule formation and fibrosis in the liver. Throughout the world, hepatic cirrhosis ranks seventh as the cause of death, with a peak around the age of 40 - 49 years. The cause of hepatic cirrhosis in Western countries is often due to alcoholic liver disease, while in Indonesia, it is mostly originated from hepatitis B or hepatitis C.

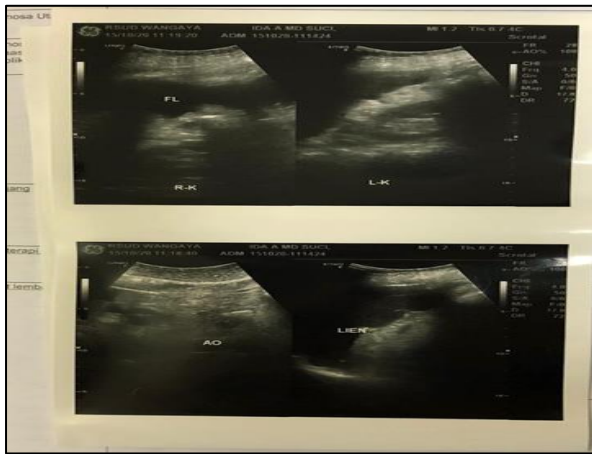
Ascites occurs in as much as 60% at 10 years after the patient suffered from compensated hepatic cirrhosis. The main factors that play a role in the formation of ascites in cirrhotic patients are sodium and water retention, as well as portal hypertension. Successful therapy will improve prognosis and symptoms. Ascites therapy using drugs and interventions to maintain normal body volume, prevent multi-organ dysfunction, and inhibit infection.

### CASE REPORT

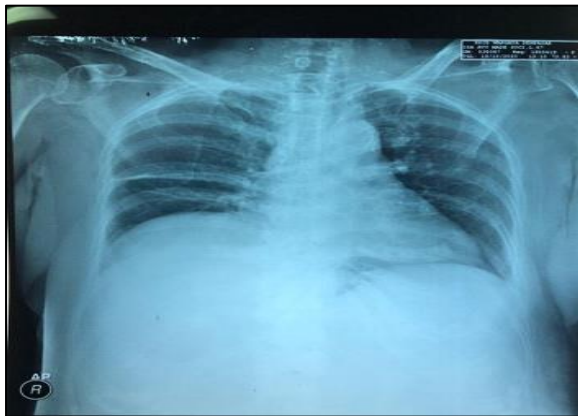
A female patient, 68 years of age, came to the Emergency Unit on October 13, 2020 with complaints of an enlarged stomach since 1 week ago. Complaints were accompanied with shortness of breath and swollen legs from last week. Complaints of vomiting blood or blackened stools are thoroughly denied. In August 2020 the patient was hospitalized with a diagnosis of ascites et causa hepatic cirrhosis. During this time, the patient routinely consumes several drugs, which are furosemide, spironolactone, vipalbumin, bisoprolol, and clopidogrel. The patient also had one puncture when she was treated in August 2020.

Physical examination revealed compost mental consciousness, blood pressure 130/80 mmHg, pulse of 90 beats per minute, respiration 22 times per minute, axillary temperature 36.6oC, and oxygen saturation 97%. Both conjunctivas appeared to be anemic. On examination of the ears, nose, throat and neck were all within normal

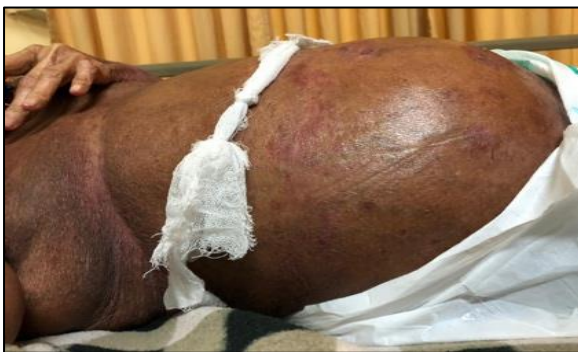limits. Physical examination of the lungs and heart were also within normal limits. There were massive ascites, distension and spotting bleeding on abdominal observation, as well as edema on both lower extremities.



**Figure 1: Patient's abdomen ultrasound result.**



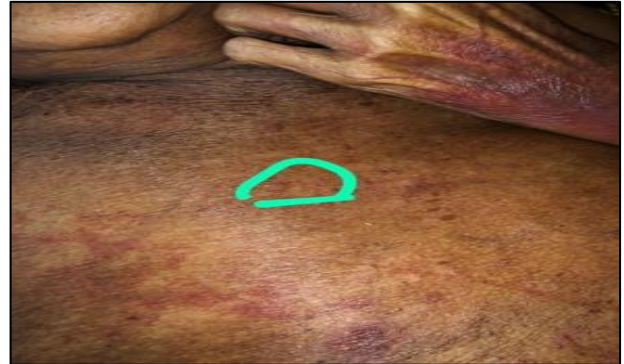**Figure 2: Thorax x-ray of the patient.**



**Figure 3: Ascites in patient.**

In the laboratory's complete blood results of the patient, it was found: leukocytes  $6.26 \times 10^3/\mu\text{l}$ ; erythrocytes  $3.62 \times 10^6/\mu\text{l}$ ; hemoglobin 10.2 g / dl; hematocrit 31.9%; platelets  $156 \times 10^3/\mu\text{l}$ . Blood chemistry examination showed: albumin 2.1 g/dl; SGOT 15 U/L; SGPT 45 U/L; urea 11 mg/dl; blood creatinine 0.6 mg / dl; sodium 134

mmol/l; potassium 4.9 mmol/l; chloride 96 mmol/l. Thorax X-ray examination results emphasized on aortosclerosis, minor fissure thickening dd. Pocketed right pleural effusion and high location of the right diaphragm. Abdomen ultrasound examination showed the results of hepatic cirrhosis, cholelithiasis with chronic cholecystitis and ascites.



**Figure 4: Spider nevi in patient.**

The therapy addressed to this patient was an infusion of 0.9% NaCl 12 drops per minute, 2 liters of O<sub>2</sub> per minute, 1 ampoule of Furosemide per day, 1×40 mg of Esomeprazole, 3×CI Lactulax, 2×1 g of Ceftriaxone, 1×100 mg of Spironolactone. In addition, the patient was also given a porridge diet with high calories, low protein and low salt. On day 14 of the treatment, the patient was treated with ascites puncture and a withdrawal of 1500 ml was acquired.

## DISCUSSION

Cirrhosis of the liver is defined as the final stage of a progressive diffuse hepatic fibrosis process characterized by the distortion of the liver architecture and the development of regenerative nodules.<sup>1</sup> Cirrhosis of the liver is the most frequent consequence of a long clinical course from all chronic liver diseases marked by liver parenchymal damage. Hepatic cirrhosis happened as a result of chronic irreversible injury to the liver parenchyma accompanied by the emergence of diffuse connective tissue (due to fibrosis injury), the construction of micronodule to macronodule size of degenerative nodules. This is in consequence of hepatocyte necrosis, the collapse of the reticulin supporting tissue, enhanced by connective tissue deposits, distortion of the vascular tissue resulting in intra-hepatic vascular formation between afferent liver vessels (portal vein and hepatic artery) and efferent (hepatic vein), also the remaining liver nodular parenchyma regeneration.<sup>1,2</sup>

There are variety of causes which lead to the hepatic cirrhosis. The most common causes are alcoholic liver disease, chronic hepatitis C, and chronic hepatitis B. Some other causes include parasitic infestations (schistosomiasis), autoimmune diseases that attack the hepatocytes or biliary epithelium, congenital liver disease,

metabolic diseases such as Wilson's disease, chronic inflammatory conditions (sarcoidosis), drug toxicity effects (methotrexate and hypervitaminosis A), and vascular disorders, either separately acquired or congenital.<sup>1,2</sup> Clinically or functionally, hepatic cirrhosis is classified into compensated liver cirrhosis, known as cirrhosis of the liver that has not displayed clinical symptoms, and decompensated cirrhosis of the liver complemented by signs of hepatocellular failure and portal hypertension.

The course of hepatic cirrhosis is slow, asymptomatic, and often not discovered until complications of liver disease are identified. Clinical features of hepatic cirrhosis are fatigue, anorexia, weight loss, muscle atrophy, jaundice, spider nevi, splenomegaly, ascites, caput medusae, palmar erythema, white nails, gynecomastia, loss of pubic hair, and armpit in women, asterixis (flapping tremor), foetor hepaticus, dupuytren's contracture (alcohol-induced cirrhosis). Currently, the diagnosis of liver cirrhosis consists of physical, laboratory, and ultrasound examination. The minimum standard for the diagnosis of hepatic cirrhosis is liver biopsy. A biopsy is not necessary if clinical, laboratory and radiological examinations show a tendency of hepatic cirrhosis.<sup>1,4</sup>

Laboratory tests for hepatic cirrhosis include normal or slightly increased AST, SGPT slightly boosted, ALP moderately increased, GGT massively grew due to alcohol, bilirubin levitates in advanced hepatic cirrhosis, depleted albumin in advanced hepatic cirrhosis, improved globulin, depressed blood sodium due to increased ADH and aldosterone, reduced platelets and leukocytes, anemia. Ultrasound examination in detecting hepatic cirrhosis is less sensitive but specific enough if the cause is clearly identified. Conventional MRI and CT examinations can be used to determine the severity of hepatic cirrhosis. Endoscopy is performed to check for esophageal varices. Despite of being used for diagnostics, it can also be used for the prevention and therapy of varicose bleeding. The main complications of hepatic cirrhosis are portal hypertension, ascites, spontaneous bacterial peritonitis, esophageal variceal bleeding, hepatorenal syndrome, hepatic encephalopathy, and liver cancer.<sup>1-3</sup>

In this patient, ascites occurs, which is likely due to the hypoalbuminemia experienced by the patient. The most common causes of ascites in hepatic cirrhosis are portal hypertension and hypoalbuminemia which will result in fluid accumulation in the peritoneum. Ascites is a result from buildup of fluid in the peritoneal cavity.<sup>4</sup> The occurrence of ascites in cirrhotic patients generally indicates a decline in clinical status and poor prognosis, hence may develop into refractory ascites, namely ascites that is recurrent and cannot be optimally prevented by sodium restriction and diuretic administration.<sup>5-9</sup> Ascites in hepatic cirrhosis mainly establishes due to impaired kidney sodium excretion which disrupts the sodium balance and as a consequence fluid retention arises, leading to the expansion of extracellular fluid volume. The

decreased excretion of sodium is due primarily to arterial vasodilation, which triggers neurohormonal responses such as the renin-angiotensin-aldosterone system (RAAS) and the sympathetic nervous system; responses that cause kidney vasoconstriction and sodium retention, resulting in the development of ascites and edema.<sup>8,10</sup>

Portal hypertension emerges due to changes in the structure of the liver in cirrhosis and improved blood flow to the splanchnic. The progressive build-up of collagen and formation of nodules alters the normal state of the hepatic vessels therefore boosts resistance towards portal flow. Sinusoids becoming less flexible due to the formation of collagen, which will cause pressure on the static portal system. Recent studies have shown that active liver stellate cells will be able to dynamically regulate sinusoidal behavior and portal pressure. Portal hypertension levitates the hydrostatic pressure in the sinusoids of the liver and causes transudation of fluid into the peritoneal.<sup>8,11</sup>

Treatment for ascites is bed rest, low salt diet, if remained unsuccessful, spironolactone and furosemide can be given. Ascites can cause complications such as spontaneous bacterial peritonitis, hyponatremia, and hepatorenal syndrome.<sup>1,12-14</sup> The initial examination of ascites includes history, physical examination, abdominal ultrasound, liver function, kidney function, serum and urine electrolytes, as well as analysis of ascites fluid.<sup>11,14</sup>

## CONCLUSION

Cirrhosis of the liver is a pathological condition that describes the final stage fibrosis of the liver parenchyma tissue, which is characterized by the formation of regenerative nodules that might interfere with liver function and liver blood flow. Liver failure will be detected due to changes in the liver parenchyma tissue to fibrotic tissue and declined perfusion of liver tissue, leading to the necrosis of the liver. Ascites is one of the most likely complications of hepatic cirrhosis. The principle of handling the patient is to shorten the disease progression, avoid further liver damage, prevention and management of complications. Good management will significantly enhance the quality of life and survival ability.

*Funding: No funding sources*

*Conflict of interest: None declared*

*Ethical approval: Not required*

## REFERENCES

1. Nurdjanah S, Hati S. Buku ajar ilmu penyakit dalam jilid 2. Edisi ke-6. Jakarta: Balai Penerbit FKUI. 2014;1978.
2. Stasi C, Silvestri C, Voller F, Cipriani F. Epidemiology of liver cirrhosis. *J Clin Exper Hep.* 2015;5:272.

3. D'amico G, Morabito A, D'amico M, Malizia G, Rebora P, Valsecchi MG. Clinical states of cirrhosis and. Competing risks. *J Hep*. 2017.
4. Hsu S, Huang H. Management of ascites in patients with liver cirrhosis : recent evidence and controversies. *Journal of Chinese Med*. 2013;123-30.
5. Caesario K, Choure A, Carey W. Cirrhotic ascites. *Cleveland Clin. Med*. Ed. 2017.
6. Adebayo D, Neong S, Wong F. Refractory ascites in liver cirrhosis. *Am J Gastroenterol*. 2018.
7. Pose E, Cardenas A. Translating our current understanding of ascites management into new therapies for patients with cirrhosis and fluid retention. *Dig Dis*. 2017;35:402-10.
8. Amer M, Elsiey H. Ascites: causes, diagnosis, and treatment. *Intech*. 2017.
9. Tan HK, James PD, Wong F. Albumin may prevent the morbidity of paracentesis-induced circulatory dysfunction in cirrhosis and refractory ascites: a pilot study. *Dig Dis Sci*. 2016;61:3084-92.
10. Pendersen J, Bendtsen F, Moller S. Management of cirrhotic ascites. *Ther Adv Chronic Dis*. 2015;6(3):124-37.
11. Maghfirah D, Abubakar A, Yusuf F. Penatalaksanaan asites pada sirosis hepatitis. *J Ked Med*. 2018.
12. Aithal G, Palaniyappan N, China L, Harmala S, Macken L, Ryan J, et al. Guidelines on the management of ascites in cirrhosis. *Gut Journal*. 2020;70:9-29.
13. Morando F, Rosi S, Gola E. Adherence to a moderate sodium restriction diet in outpatients with cirrhosis and ascites: a real-life cross-sectional study. *Liver Int*. 2015;35:1508-15.
14. Bernardi M, Caraceni P, Navickis RJ. Does the evidence support a survival benefit of albumin infusion in patients with cirrhosis undergoing large volume paracentesis?. *Expert Rev Gastroenterol Hepatol*. 2017;11:191-2.

**Cite this article as:** Hotama JR, Suryana K. Ascites *et causa* hepatic cirrhosis. *Int J Adv Med* 2021;8:455-8.