

Case Report

Recurrent hepatic encephalopathy precipitated by urinary tract infection in patient with liver cirrhosis: a case report

Desak Putu Gayatri Saraswati Seputra*, Luh Putu Dea Sasmita Pralambari, Ketut Suryana

Department of Internal Medicine, Wangaya Regional Hospital, Denpasar, Bali, Indonesia

Received: 12 March 2021

Accepted: 15 April 2021

*Correspondence:

Dr. Desak Putu Gayatri Saraswati Seputra,
E-mail: gayatri_saraswati@yahoo.com

Copyright: © the author(s), publisher and licensee Medip Academy. This is an open-access article distributed under the terms of the Creative Commons Attribution Non-Commercial License, which permits unrestricted non-commercial use, distribution, and reproduction in any medium, provided the original work is properly cited.

ABSTRACT

Liver cirrhosis is a chronic liver injury marked by necro-inflammation and fibrogenesis. It is associated with several life-threatening complications. Hepatic encephalopathy remains to be one of the most debilitating complication of liver cirrhosis. The occurrence of hepatic encephalopathy may be directly related to endogenous worsening of liver function or occurs in the presence of specific precipitating factor. Infection such as urinary tract infection is a common precipitant of hepatic encephalopathy. We present a case of 66 year old female with recurrent hepatic encephalopathy in hepatitis B-related liver cirrhosis precipitated by urinary tract infection. Rapid and precise recognition of precipitating factor in hepatic encephalopathy is very substantial for implementation of preventive measures and optimal treatment plan in order to achieve better outcomes in liver cirrhosis patient.

Keywords: Hepatic encephalopathy, Liver cirrhosis, Infection

INTRODUCTION

Liver cirrhosis is a chronic liver injury characterized by necroinflammation and fibrogenesis which arises from numerous mechanisms. Various causes of chronic liver injury such as autoimmune destruction of hepatocyte, alcohol consumption, metabolic diseases, drugs, and viral hepatitis may precede liver cirrhosis.¹ Liver cirrhosis histologically appeared as formation of diffuse regenerative nodule separated by fibrous septae and distortion of vascular architecture with parenchymal extinction and liver structure collapse.^{1,2} Liver cirrhosis was stated to be responsible for more than 1.32 million deaths per year worldwide, contributing to 2.4% of total deaths globally in 2017.³

Liver cirrhosis is associated with several life-threatening complications. Hepatic encephalopathy remains to be one of the most severe and debilitating complication of liver

cirrhosis. Hepatic encephalopathy is a brain dysfunction manifesting as neurological and psychiatric abnormalities which develops as a result of liver failure and/or portal-systemic shunting.⁴ Hepatic encephalopathy occurs in 2-20% patients with liver cirrhosis annually. This condition is associated with higher morbidity and mortality in patient with liver cirrhosis as well as significant utilization of health care resources.^{4,5}

Hepatic encephalopathy may be directly related to endogenous worsening of liver function or occurs in the presence of specific precipitating factor. Those precipitating factors may include excessive protein intake, constipation, drug ingestion (sedative, opioid), azotemia, hyponatremia, hypokalemia, alkalosis, hypovolemia, gastrointestinal bleeding, shock, hypoxia and infection.⁵⁻⁷

Bacterial infections are frequently encountered in patients with liver cirrhosis. More than 50% of hospitalized liver

cirrhosis patients present with bacterial infection either at admission or develop later on during hospitalization. Infections in patient with liver cirrhosis are detrimental to hepatic functions and may lead to increased mortality. Spontaneous bacterial peritonitis, urinary tract infection, pneumonia, skin and soft tissue infection, and bacteremia are the most frequent infections found among liver cirrhosis patients.^{5,8}

We present a case of recurrent hepatic encephalopathy precipitated by urinary tract infection in patient with hepatitis B-related liver cirrhosis admitted at Wangaya regional hospital Denpasar. Current case presentation is substantial as a reminder regarding the importance of endogenous and exogenous risk factors identification in hepatic encephalopathy, as this complication is highly possible to be encountered especially by primary care provider in their practices. Recognition of precipitating factors in hepatic encephalopathy would be paramount for preventive measures implementation to improve overall outcomes of liver cirrhosis patients.

CASE REPORT

A 66 year old female was admitted due to altered mental status several hours prior to hospitalization. The patient was diagnosed with liver cirrhosis related to chronic hepatitis B infection since 4 months. The patient was confused and presented with disorientation. She was previously hospitalized due to hepatic encephalopathy a week before current admission. She was discharge with medications including oral third-generation cephalosporin antibiotic, furosemide, spironolactone, ursodeoxycholic acid, L-ornithin-L-aspartate, lactulose, proton pump inhibitor (PPI) and antacid. The patient presented with distended abdomen due to gross ascites. She had no symptom of vomiting, diarrhea, constipation, hematemesis and melena or symptom suggestive of other sources of bleeding pre-hospitalization. The patient didn't have any history of fever or symptom regarding urination. Patient denied high protein content foods consumption.

On examination, the patient was difficult to communicate with and slow to answer questions. The patient was disoriented about time. Vital was within normal limit. Other physical examination findings showed stigmata of chronic liver disease. Icteric sclera was found in the patient. Abdominal examination showed grade III ascites with collateral vein formation. Liver and spleen were hard to evaluate due to marked abdominal distention. No significant skin, hair and nail changes were found. Peripheral edema was not found. Asterixis was found to be positive.

Laboratory examination revealed leukocytosis ($10.56 \times 10^3/\mu\text{l}$) with neutrophil predominance (70.1%) and low lymphocyte (15.1%), mild normochromic normocytic anemia (Hb=9.2 g/dl; MCV=92.1 fl; MCH: 33 pg) and thrombocytopenia ($123 \times 10^3/\mu\text{l}$).

Neutrophil/lymphocyte ratio was found to be high (NLR ratio=4.66). Liver enzyme test showed no marked elevation (SGOT=49; SGPT=18). Protein analysis showed low albumin level (2.4 g/dl) and low albumin/globulin ratio (A/G ratio=2.1). Hyperbilirubinemia (6.8 mg/dl) with direct bilirubin dominance (4.4 mg/dl) was also found in the patient. Prothrombin time was 6 seconds prolonged from upper normal limit. Urinalysis examination showed elevated leukocyte esterase (250/ μl), elevated leukocyte sediment (8/hpf) and bacteriuria. Urine culture test was positive for *Enterococcus faecalis* with colony count of 60.000 CFU/ml. Electrolyte, serum ureum and creatinin level, alkaline phosphatase and gamma-glutamyl transferase (GGT) examination were in normal limit. Chest X-ray revealed no abnormality (Figure 1).

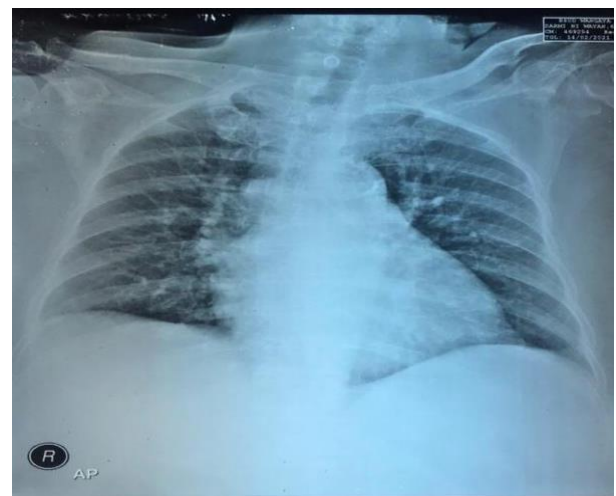


Figure 1: Chest X-ray of the patient shows no abnormality.

Based on the clinical and laboratory findings, her altered mental status was attributed to hepatic encephalopathy precipitated by urinary tract infection. The patient was started on branched-chain amino acid infusion, L-ornithin-L-aspartate, lactulose and third-generation cephalosporin antibiotic intravenously. Ursodeoxycholic acid for hyperbilirunemia and diuretic to reduce water retention were also given. All features of encephalopathy completely reversed and she was discharged on the seventh hospital day.

DISCUSSION

Current case illustrates liver cirrhosis with child-turcotte-pugh (CTP) class C complicated by hepatic encephalopathy. The reported patient showed signs suggestive of hepatic encephalopathy in severe liver insufficiency as she did not have obvious alternative causes of brain dysfunction. The patient experienced recurrent hepatic encephalopathy as she had more than one episode of hepatic encephalopathy within a time interval of 6 months.⁶ The patient was classified as type C hepatic encephalopathy in which the underlying cause is

liver cirrhosis and porto-systemic bypass. According to West-Haven criteria, the patient fell on the second grade of hepatic encephalopathy with symptoms of lethargy or apathy, disorientation for time, obvious personality change, inappropriate behaviour and asterixis.⁷

Several pathomechanism including the role of neurotoxin and impairment in neurotransmission, changes in metabolism of the brain, response to systemic inflammation and alteration of the blood brain barrier are said to underlie the occurrence of hepatic encephalopathy.^{6,8} Type C hepatic encephalopathy episode in majority of cases developed as a response to specific precipitating factors. In this patient the precipitating factor was highly likely to be urinary tract infection. The patient blood examination revealed leukocytosis with neutrophil predominance. Neutrophil/lymphocyte ratio (NLR) was also found to be high. Urinalysis examination showed elevated leukocyte esterase, elevated leukocyte sediment and bacteriuria. Fever and classic symptom of urinary tract infection were not found, probably due to immune-compromised state of the patient which can be seen by the low lymphocyte count.

Infection is a common precipitant of hepatic encephalopathy. The most common infections encountered in liver cirrhosis patient including urinary tract infection, spontaneous bacterial peritonitis, pneumonia, soft tissue and skin infections, and bacteremia.⁹ Patients with liver cirrhosis are oftentimes experience an immune-suppressed state and are more prone to infection. It is still unclear whether the infection themselves or the response to inflammation that leads to an episode of hepatic encephalopathy in patient with cirrhosis.⁶

Higher risk of developing bacterial infection in liver cirrhosis is associated to bacterial overgrowth and increased translocation of bacteria. The possibility of bacterial translocation from the intestine rises as the immune weakens. Bacterial translocation is the migration of microorganisms and their products including endotoxin, bacterial DNA, peptidoglycans, and lipoteichoic acid across the intestinal barrier to the mesenteric lymph nodes and to other extra intestinal organs. This condition happens due to lowered intestinal motility and increased permeability. Bacterial translocation causes a pro-inflammatory state that may lead to decompensation of liver cirrhosis. Hyperactivation of immune system or cytokine storm eventually will cause immune dysfunction and additionally increased the susceptibility to other infections.⁹

Positive cultures from blood, urine or ascitic fluid sample are the ideal laboratory tests to support bacterial infection diagnosis as well as to confirm the pathogen species. However, there is a possibility of failure in isolation of pathogen. It may be caused by culture media which does

not promote the colony formation or due to the presence of non-dividing bacterial cells commonly after antibiotic administration which blocks the process of bacterial division. Lack of bacteria may also results in negative culture, although the presence of bacterial product may still stimulate a host response.⁹ In this case the patient had positive culture from urine sample, however the colony count was less than 10^5 CFU/ml, the threshold for diagnosis of urinary tract infection.¹⁰ Patient had history of third generation cephalosporin administration in previous hospitalization which to some extent may affect the presence of bacteria in the body, making it difficult to objectively evaluate the urine culture result. The urine culture was positive for *Enterococcus faecalis*, a commensal bacterium which normally resides in gastrointestinal tract, supporting the bacterial translocation mechanism in liver cirrhosis.¹¹

Other precipitating factor such as excessive protein intake, constipation, hypovolemia due to excessive water loss from vomiting, diarrhoea or blood loss, gastrointestinal bleeding, and other electrolyte abnormality were not found. One of the exogenous factors that may induce hepatic encephalopathy is hepatotoxic drugs consumption or known as drug-induced liver injury. It is caused by medications, herbal, or dietary supplements and generally occurs within 5-90 days after drug ingestion.¹² None of the regular medications prescribed for the patient are classified as hepato-toxic. Endogenous worsening of liver function as the mechanism which underlies the episode of hepatic encephalopathy in this patient was not in suspicion as there was no marked elevation in liver enzymes.

Liver cirrhosis patients with severe infections should receive early intravenous antibiotics when the diagnosis of infection is confirmed. Delays in treatment are associated with higher mortality. The empirical treatment should cover a wide spectrum of bacteria with minimal adverse events. Third-generation cephalosporins have been considered to be the gold standard for empirical treatment of various infections in cirrhotic patients due to their good tolerance and activity against *Enterobacteriaceae* and non-enterococcal streptococci.⁹ The patient was started on third generation cephalosporin and continued during hospital stay as it was also appropriate according to urine culture and antibiotic sensitivity test result. Lactulose, non-absorbable disaccharides are also recommended for hepatic encephalopathy. Lactulose is a laxative which has notable impact on gut function and microbiota. It works by reducing intestinal transit time, acidification of the bowel milieu and helps to promote the elimination of nitrogenous products in the gut that are responsible for the development of encephalopathy.^{13,14} Branched-chain amino acid and L-ornithin-L-aspartate are also stated to have beneficial effect on hepatic encephalopathy.¹³ Branched-chain amino acid works by correcting the disproportion of branched-chain and aromatic amino acids, thus reducing false neurotransmitter synthesis.⁹

Meanwhile, L-ornithin-L-aspartate acts as ammonia-lowering agent by stimulation of urea synthesis by residual periportal hepatocytes and ammonia removal via glutamine synthesis in skeletal muscle.¹⁵

More frequent exposure to infection is a strong predictive factor for mortality in cirrhotic patients. A study found a mortality rate of 51.26% among cirrhotic patients with hepatic encephalopathy, and 76% of them were exposed to infection before hepatic encephalopathy development.⁵ Hence, recognition and preventive measure of infection were crucial in patient with liver cirrhosis to extenuate hepatic encephalopathy-related morbidity and mortality.

CONCLUSION

Liver cirrhosis is an end stage chronic liver disease characterized by liver parenchymal damage. Patients with liver cirrhosis may lead to some complications and hepatic encephalopathy being one of them. In current case, a 66 year old female patient was diagnosed with liver cirrhosis related to chronic hepatitis B infection and was admitted due to recurrent hepatic encephalopathy precipitated by urinary tract infection. Precipitating factor can be found in majority of hepatic encephalopathy episodes and should be actively sought and treated when identified.

Funding: No funding sources

Conflict of interest: None declared

Ethical approval: Not required

REFERENCES

1. Qiao J. Occurrence, diagnosis and management of hepatic fibrosis and cirrhosis: An updated literature review. Arch Hepat Res. 2019;5(1):22-6.
2. Alaqaili HI, Al-Juraysan AI, Hawsawi RMA, Abuzaid FA, Alharbi MA, Mughallis AEA. Review on liver cirrhosis complications and treatment. Egypt J Med. 2017;69(8):3092-103.
3. GBD 2017 cirrhosis collaborators. The global, regional, and national burden of cirrhosis by cause in 195 countries and territories, 1990-2017: a systematic analysis for the Global Burden of Disease Study 2017. Lancet Gastroenterol Hepatol. 2020;5:245-66.
4. Montagnese S, Russo FP, Amodio P, Burra P, Gasbarrini A, Loguercio C, et al. Hepatic encephalopathy 2018: A clinical practice guideline by the Italian association for the study of the liver. Digest Liver Dis. 2019;51:190-205.
5. Yuan L, Chuah S, Yang S, Liang C, Wu C, Tai W, et al. Multiple bacterial infections increase the risk of hepatic encephalopathy in patients with cirrhosis. PLoS ONE. 2018;13(5):1-14.
6. Ferenci P. Hepatic encephalopathy. Gastroenterology Report. 2017;5(2):138-47.
7. Weissenborn K. Hepatic encephalopathy: definition, clinical grading and diagnostic principles. Drugs. 2019;79(1):S5-9.
8. European association for the study of the liver. EASL clinical practice guidelines for the management of patients with decompensated cirrhosis. J Hepatol. 2018;69:406-60.
9. Piotrowski D, Boron-Kaczmarzka A. Bacterial infections and hepatic encephalopathy in liver cirrhosis—prophylaxis and treatment. Adv Med Sci. 2017;62:345-56.
10. Urinary tract infection; catheter associated urinary tract infection (CAUTI) and non-catheter associated urinary tract infection (UTI) and other urinary system infection (USI) events. Available at: <https://www.cdc.gov/nhsn/pdfs/pscmanual/7psccauticurrent.pdf>. Accessed on 4 March 2021.
11. Archambaud C, Derré-Bobillot A, Lapaque N, Rigottier-Gois L, Serron P. Intestinal translocation of enterococci requires a threshold level of enterococcal overgrowth in the lumen. Sci Rep. 2019;9:8926-38.
12. Sandhu N, Navarro V. Drug-induced liver injury in GI practice. Hepatol Comm. 2020;4(5):631-45.
13. Rose CF, Amodio P, Bajaj JS, Dhiman RK, Montagnese S, Taylor-Robinson SD, et al. Hepatic encephalopathy: novel insights into classification, pathophysiology and therapy. J Hepatol. 2020; 73:1526-47.
14. Bacon BR. Cirrhosis and its complication. In: Jameson JL, Kasper DL, Longo DL, Fauci AS, Hauser SL, Loscalzo J, eds. Harrison's principle of internal medicine. 20th ed. New York: McGraw-Hill; 2018:2405-14.
15. Butterworth RF, McPhail MJW. L-Ornithine L-Aspartate (LOLA) for hepatic encephalopathy in cirrhosis: results of randomized controlled trials and meta-analyses. Drugs. 2019;79 (1):S31-7.

Cite this article as: Seputra DPGS, Pralambari LPDS, Suryana K. Recurrent hepatic encephalopathy precipitated by urinary tract infection in patient with liver cirrhosis: a case report. Int J Adv Med 2021;8:712-5.