

## Case Report

# Gastric variceal bleeding related with sinistral portal hypertension occurring secondary to splenic vein thrombosis developed as a complication of acute pancreatitis

Hasan Ergenc<sup>1</sup>, Ahmet Tarık Eminler<sup>2</sup>, Ceyhun Varım<sup>1\*</sup>, Cengiz Karacaer<sup>1</sup>,  
Mustafa İhsan Uslan<sup>2</sup>, Erkan Parlak<sup>2</sup>, Aydın Şeref Köksal<sup>2</sup>

<sup>1</sup>Department of Internal Medicine, Faculty of Medicine, Sakarya University, Sakarya, Turkey

<sup>2</sup>Department of Gastroenterology, Faculty of Medicine, Sakarya University, Sakarya, Turkey

**Received:** 01 September 2015

**Accepted:** 05 October 2015

### \*Correspondence:

Dr. Ceyhun Varım,

E-mail: [ceyhunvarim@sakarya.edu.tr](mailto:ceyhunvarim@sakarya.edu.tr), [ceyhunvarim@yahoo.com](mailto:ceyhunvarim@yahoo.com)

**Copyright:** © the author(s), publisher and licensee Medip Academy. This is an open-access article distributed under the terms of the Creative Commons Attribution Non-Commercial License, which permits unrestricted non-commercial use, distribution, and reproduction in any medium, provided the original work is properly cited.

### ABSTRACT

Rare part of upper gastrointestinal system bleedings, gastric variceal bleeding secondary to sinistral portal hypertension can be observed. Primary pathology is generally Splenic Vein Trombosis (SVT) or occlusion to secondary acute or chronic pancreatitis and pancreatic cancer. In patients, esophageal or gastric varices can be seen as a result of SPH secondary to splenic vein thrombosis. Various kinds of treatments have been carried out in bleedings resulting from these varices. Here we report a patient with massive gastric variceal bleeding caused by SPH, which was induced by splenic vein thrombosis secondary to acute pancreatitis.

**Keywords:** Sinistral portal hypertension, Bleeding, Thrombosis, Pancreatitis

### INTRODUCTION

Rare part of upper gastrointestinal system bleedings, gastric variceal bleeding secondary to sinistral portal hypertension can be observed. Primary pathology is generally Splenic Vein Trombosis (SVT) or occlusion to secondary acute or chronic pancreatitis and pancreatic cancer. In patients, esophageal or gastric varices can be seen as a result of SPH secondary to splenic vein thrombosis. Various kinds of treatments have been carried out in bleedings resulting from these varices.<sup>1</sup> Here we report a patient with massive gastric variceal bleeding caused by SPH, which was induced by splenic vein thrombosis secondary to acute pancreatitis.

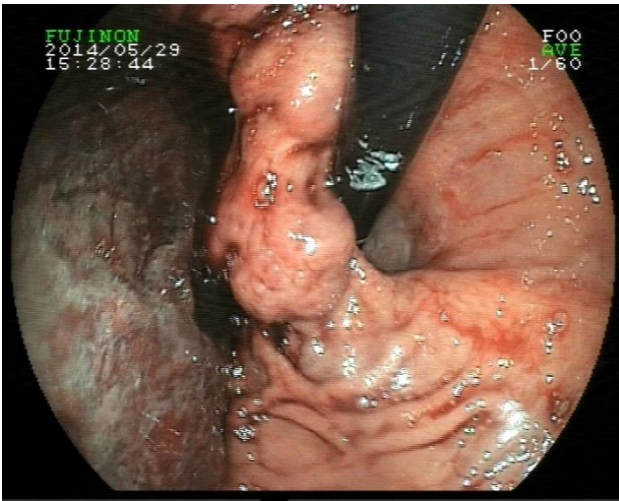
### CASE REPORT

The A 48-years old woman applied to another center with the complaint of hematemesis 2 days ago before referring

to our clinic. When the patient applied us, her melena was in progress. Physical examination was normal except for a pale conjunctiva, pale mucous membranes and abdominal distention. Her blood pressure was 110/70 mm/Hg and pulse rate was 88 /min.

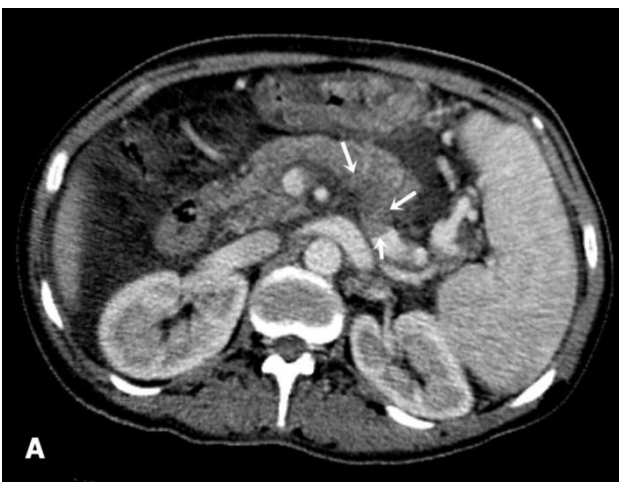
Initial blood results showed a hemoglobin of 9.9 (13-18 g/dL), white cell count of 9.6 (4-11 x 10<sup>9</sup>/L), and platelets of 58 (150-450 x 10<sup>9</sup>/L). Coagulation profile, renal function and liver function tests were within normal limits. In her gastroscopic examination first we saw a proximal esophageal web that caused a narrowing which inhibit the moving of gastroscopie to the distal esophagus. We performed buji dilatation process at the region of web and then we achieved to exceed. An actively bleeding, about 1.5 cm in diameter, fundus settled varices were seen (Figure 1). Active bleeding was taken under control with cyanoacrylate injecton for varices. General condition remained stable during follow-up and then after

the 48 hours control gastroscopy was performed. We detected that the fundal variceal bleeding was stopped and varices had sclerosed as a response to the treatment was observed.

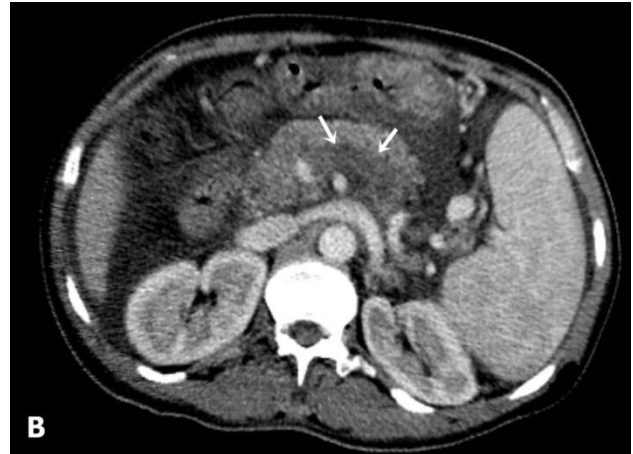


**Figure 1: An actively bleeding, about 1.5 cm in diameter, fundus settled varices.**

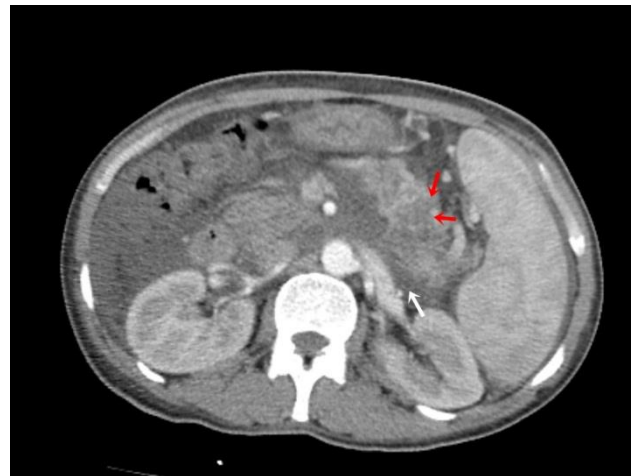In abdomen ultrasonography (USG) examination intended for the reason of the patient's existed isolated gastric varices, no pathology was submitted apart from hepatomegaly, splenomegaly and extensive ascites. Paracentesis with the companion of USG was done to the patient. Serum ascites- albumin gradient was 1.9 g/dl. Cell count in the ascites was normal and the cytology was determined in benign character. In portal vein doppler ultrasonography examination, thrombosis was observed in 5.5 cm segment of the prior region of splenic vein-portal confluence combination. Also in dynamic triphasic upper abdomen tomography examination, splenic vein thrombosis having similar speciality was seen too, and at the same time focal pancreatitis in the caudal region of pancreas was detected. (Figure 2A, 2B and 3).



**Figure 2A: Splenic vein contrast is being cut with thrombosis in the axial plan presentation.**



**Figure 2B: Thrombosis has been ongoing throughout splenic vein.**



**Figure 3: The rate of pancreas caudal part has increased and hipodens areas (red arrows) and peripancreatic fluids (white arrows) have been observed.**

For differential diagnosis, tests were planned for thrombophilic situations. Protein C, S and homocystein levels and anti-thrombin III activity was determined as normal. JAK-2, Factor V leiden, prothrombin and MTHFR gene mutation were submitted negative.

Although the patient didn't have acute pancreatitis clinic and also amylase values were normal, we made interventions about the etiologies of pancreatitis because there was a typical pancreatitis appearance in screening methods. The patient had normal levels of triglyceride and calcium and didn't have obvious medicine using story. The terms of other infectious factors that will cause pancreatitis were determined negative. Upon questioning the patient's anamnesis, it was learned that she had physical violence and stroke many times to her abdomen from her husband. With the light of these symptoms, pancreatitis evolving after blunt and recurrent trauma to abdomen and relating this, isolated gastric variceal bleeding secondary to sinistral portal hypertension

diagnosis that develops as a result of splenic vein thrombosis was observed in the patient and anticoagulant treatment was started.

## DISCUSSION

Sinistral portal hypertension is a pathological situation that defined as gastrosplenic left side localized region splanchnic venous hypertension.<sup>2</sup> As a result of splenic way out obstruction (e.g splenic vein thrombosis or extrinsic impress); venous pressure increases and venous collaterals in gastrosplenic area occur and as a consequence gastric variceal bleeding can happen.<sup>3</sup> The most frequent reason of splenic vein thrombosis or occlusion which cause sinistral portal hypertension is related to pancreatic pathologies.<sup>4-7</sup> Chronic pancreatitis, acute pancreatitis, pseudocysts and pancreatic cancers can be accounted among these reasons. In a recent meta analysis, splenic vein thrombosis incidence correlated with pancreatitis has been given as 14.1%, also acute pancreatitis rate as 22.6 % and chronic pancreatitis as 12.4% has been indicated.<sup>8</sup> Apart from pancreatic pathologies, some rare reasons such as infiltrative colon cancers,<sup>9</sup> perirenal abscess,<sup>10</sup> retroperitoneal fibrosis, splenic artery aneurysm, thrombophilic conditions can be counted.<sup>11</sup>

General clinic symptoms of sinistral portal hypertension are gastroesophageal varices, acid and splenomegaly. While generally being asymptomatic, the presenting clinic existing occurs as ruptured gastric or esophageal varices. In 77% of patients having SPH gastric varices have been determined and bleeding rate has been given as 12.3%.<sup>8</sup> SPH should be considered when the patient presents with gastrointestinal bleeding from gastric varices with normal liver function, splenomegaly and with no signs of cirrhosis.

The treatment must generally be evaluated according to disease that lay under pancreatitis. Splenectomy is seen as the best treatment in long term. Nevertheless, endoscopic injection sclerotherapy by using cyanoacrylate gives useful results in the facts especially with acute severe variceal bleeding.<sup>12</sup> Cyanoacrylate polymerizes quickly when contacting with blood and thus, take bleeding under control by causing hemostasis. Although ulceration and re-bleeding are the risks of that treatment also it includes more serious complications such as lung, brain and portal vein embolisms. From due the low gastric varices rate that develop from splenic vein thrombosis related to the pancreatitis, routine splenectomy is not recommended in these patients.<sup>13</sup> Therefore, in obliteration of active gastric variceal bleeding, cyanoacrylate injection is accepted as the first choice of treatment.<sup>14</sup>

Consequently, in considerable part of gastric variceal bleeding that come across as a rare reason of acute upper gastrointestinal system bleeding, splenic vein thrombosis developing secondary to the sinistral portal hypertension

is determined. In patients determined as splenic vein thrombosis, pathologies that generally concern to pancreas must be thought as the reason. At the present time, endoscopic cyanoacrylate injection is accepted as the most appropriate treatment in terms of the control of gastric variceal bleedings.

*Funding: No funding sources*

*Conflict of interest: None declared*

*Ethical approval: Not required*

## REFERENCES

1. Wang L, Liu GJ, Chen YX, Dong HP, Wang LX. Sinistral portal hypertension: clinical features and surgical treatment of chronic splenic vein occlusion. *Med Princ Pract.* 2012;21(1):20-3.
2. Weber SM, Rikkens LF. Splenic vein thrombosis and gastrointestinal bleeding in chronic pancreatitis. *World J Surg.* 2003;27:1271-4.
3. Liu QD, Zhou NX, Zhang WZ, Wang MQ. Diagnosis and management of regional portal hypertension. *Chin J Dign Dis.* 2005;6:87-92.
4. Evans GR, Yellin AE, Weaver FA, Stain SC. Sinistral (left-sided) portal hypertension. *Am Surg.* 1990 Dec;56(12):758-63.
5. Wani NA, Lone TK, Shah AI, Khan AQ, Malik RA. Malignant solid pseudopapillary tumor of pancreas causing sinistral portal hypertension. *Indian J Pathol Microbiol.* 2011 Jan-Mar;54(1):152-5.
6. Ozaki K, Sanada J, Gabata T, Ogi T, Takamura H, Ohta T, et al. Severe intestinal bleeding due to sinistral portal hypertension after pylorus-preserving pancreatoduodenectomy. *Abdom Imaging.* 2010 Dec;35(6):643-5.
7. Olakowski M, Lampe P, Bołdys H, Słota J, Olakowska E. Neuroendocrine pancreatic carcinoma causing sinistral portal hypertension. *Med Sci Monit.* 2001 Nov-Dec;7(6):1326-8.
8. Butler JR, Eckert GJ, Zyromski NJ, Leonardi MJ, Lillemo KD, Howard TJ. Natural history of pancreatitis-induced splenic vein thrombosis: a systematic review and meta-analysis of its incidence and rate of gastrointestinal bleeding. *HPB (Oxford).* 2011 Dec;13(12):839-45.
9. Seenu V, Goel AK, Shukla NK, Dawar R, Sood S. Hodgkin's lymphoma of colon: an unusual cause of isolated splenic vein obstruction. *Indian J Gastroenterol.* 1994 Apr;13(2):70-1.
10. Köklü S, Köksal A, Yolcu OF, Bayram G, Sakaogullari Z, Arda K, et al. Isolated splenic vein thrombosis: an unusual cause and review of the literature. *Can J Gastroenterol.* 2004 Mar;18(3):173-4.
11. Köklü S, Coban S, Yüksel O, Arhan M. Left-sided portal hypertension. *Dign Dis Sci.* 2007 May;52(5):1141-9.
12. Mosli MH, Aljudaibi B, Almadi M, Marotta P. The safety and efficacy of gastric fundal variceal obliteration using N-butyl-2-cyanoacrylate; the

experience of a single Canadian tertiary care centre. *Saudi J Gastroenterol.* 2013 Jul-Aug;19(4):152-9.

13. Heider TR, Azeem S, Galanko JA, Behrns KE. The natural history of pancreatitis-induced splenic vein thrombosis. *Ann Surg.* 2004 Jun;239(6):876-80.
14. Sato T, Kitagawa S, Kimura M, Ohmura T, Karino Y, Toyota J. Gastric varices secondary to

splenic vein occlusion due to pancreatic diseases. *Pancreatic Dis Ther.* 2013;S3:1-5.

**Cite this article as:** Ergenc H, Eminler AT, Varım C, Karacaer C, Uslan Mİ, Parlak E, Köksal AŞ. Gastric variceal bleeding related with sinistral portal hypertension occurring secondary to splenic vein thrombosis developed as a complication of acute pancreatitis. *Int J Adv Med* 2015;2:419-22.