

Original Research Article

Fracture of the penis in Jos, Nigeria: review of cases in 2020

Chimaobi G. Ofoha^{1,2*}, Ifiok P. Umana¹, Adedeji G. Adewale¹

¹Department of Surgery, Jos University Teaching Hospital, Jos, Nigeria

²Department of Surgery, College of Health Sciences, University of Jos, Nigeria

Received: 07 April 2021

Revised: 15 May 2021

Accepted: 17 May 2021

***Correspondence:**

Dr. Chimaobi G. Ofoha,

E-mail: drchimao@yahoo.com

Copyright: © the author(s), publisher and licensee Medip Academy. This is an open-access article distributed under the terms of the Creative Commons Attribution Non-Commercial License, which permits unrestricted non-commercial use, distribution, and reproduction in any medium, provided the original work is properly cited.

ABSTRACT

Background: Penile fracture is a urological emergency and requires urgent medical attention. There was a relative upsurge in 2020. Diagnosis is usually based on typical history and examination findings suggestive of penile fracture. The objective of this study was to determine the demographics, clinical presentation and management of fracture of the penis.

Methods: All patients who presented at the accident and emergency in 2020 with penile fracture were studied. The patients age, time to presentation, mechanism of injury, clinical features (cracking sound, pain, immediate detumescence, penile swelling, urethral bleeding and acute urinary retention) were recorded. Intraoperative findings (location of corpora rupture, length of tear and urethral rupture) were recorded and analysed.

Results: Twelve patients were studied. The mean age was 34.8 years, range (20 years to 56 years). 58.3% presented within 24 hours of trauma. The commonest mechanism of penile fracture was sexual intercourse with the woman on top position (58%). 75% of the patients heard a popping sound. All patients had pain, detumescence and penile swelling (N=12) 100%. Two patients had urethral bleeding (N=2) 16.7%, with one having associated urethral rupture (N=1) 8.3%. Two patients had acute urinary retention (16.7%). Rupture of the right corpora occurred in 50%, 8.3% had bilateral rupture of the corpora. All the patients had repair of the corporal rupture. Urethral injury was repaired primarily. Erection and voiding post-repair were satisfactory.

Conclusions: Fracture of the penis is a urological emergency. Diagnosis can be made based on typical history and examination findings. Prompt surgical intervention is advised to avoid complications and erectile dysfunction.

Keywords: Fracture, Penis, Sexual intercourse, Penile fracture, Jos

INTRODUCTION

Trauma to the erect penis commonly results in penile fracture. It is described as rupture of the corpus cavernosum or tears in the tunica albuginea following blunt trauma to the erect penis.^{1,2}

In the flaccid state, the tunica is about 2 mm thick. During erection, the thickness decreases to 0.25 mm to 0.5 mm hence predisposing the erect penis to injuries from buckling forces.³ Commonly one corpus cavernosum is

ruptured, however, both corpora may be torn.⁴ Occasionally there may be associated urethral injury.

The epidemiology of penile fracture is difficult to describe because of under-reporting. However, in the U.S.A its incidence is put at 1.02 per 100,000 male subjects per year. In Nigeria, the incidence cannot be readily ascertained due to the dearth of information.^{5,6}

Causes of penile fracture include forceful manipulation of the erect penis, vigorous vaginal intercourse in the reverse

coital position (usually the penis slips out of the vagina and hits the pubic bone during thrust) or anal intercourse or masturbation. Other mechanical trauma that results in forceful bending of an erect penis may also lead to penile fracture.^{7,8}

Penile fracture is a urological emergency and requires urgent medical assessment and repair. Diagnosis is usually clinical, based on typical history and examination findings, usually suggestive of penile fracture. There is a crackling, snapping or popping with sudden detumescence, pain and penile swelling. Examination will reveal a swollen, ecchymosed and deformed penis. There may be urethral bleeding, haematuria, difficulty passing urine and acute urinary retention if associated with urethral injury.^{9,10}

This study aimed to determine the demographics, clinical presentation and management of penile fractures.

METHODS

This was a retrospective study conducted at the Jos university teaching hospital, Jos Nigeria. All patients who presented at the accident and emergency from January 2020 to December 2020 (during the lockdown) with fracture of the penis were recruited into the study. The emergency room team resuscitated all patients. Subsequently, the urology team was invited for further management, which included history, physical examination, relevant investigations and subsequent penile exploration.

Patients age, time to presentation, mechanism of injury, clinical features (cracking sound, pain, immediate detumescence, penile swelling, urethral bleeding and acute urinary retention) were recorded. Penile exploration and intraoperative findings (location of corporal rupture, length of tear and urethral rupture) were recorded in a proforma and analysed.

Surgical procedure

The surgical procedures done were as follows: position was supine; anaesthesia was the saddle block. All patients received preoperative parenteral antibiotics. Surgical site was prepared in the standard manner. A tourniquet was applied at the base of the penis and timed. A circumcoronal incision was made on the penile shaft. The skin, superficial layer and Buck's fascia were incised and the penis degloved. The hematoma was evacuated. The corporal rupture was identified and repaired using vicryl 0 suture. The patient with associated urethral injury had primary urethral reconstruction over a 16F 2-way silicone catheter. The incision was closed by interrupted sutures using 3/0 vicryl suture. A pressure bandage was applied to the penis. All patients had catheterisation (2-way 16F silicone) which was removed after 72 hours following review of the pressure dressing. Postoperative antibiotics were given for seven days. Patients were discharged after review of the

pressure dressing on the third day and were counselled to commence intercourse in four weeks.

Statistical analysis

SPSS version 23 was used for data analysis. Measures of central tendencies, mean, median were done for the different variables. Results were represented in tables and charts.

Ethical considerations

Informed consent was obtained from all the patients. The IRB permits retrospective studies.

RESULTS

Twelve patients were involved in the study. The mean age was 34.8 years with a range of 20 years to 56 years. Most of the patients (58.3%) presented within 24 hours of trauma. This is shown in Figure 1.

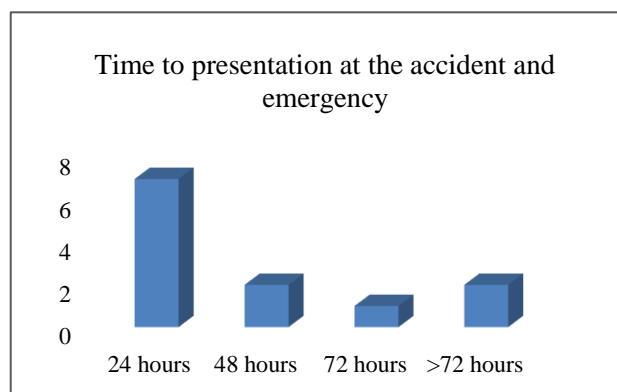


Figure 1: Showing time to presentation at the accident and emergency following penile fracture.

The commonest mechanism of penile fracture was sexual intercourse with the woman on top position (58%) followed by self-manipulation. Figure 2 depicts this.

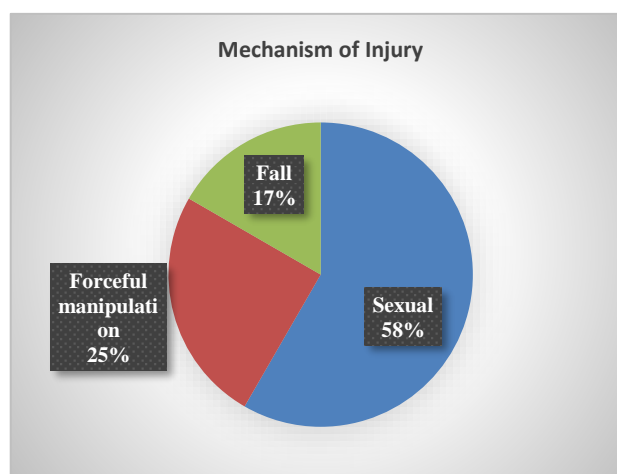


Figure 2: The mechanism of penile fracture.

Nine patients heard a popping sound (N=9) 75%, all patients had pain, detumescence and penile swelling (N=12) 100%. Figure 3 shows swollen deformed penis. Two patients had urethral bleeding (N=2) 16.7%, with one having associated urethral rupture (N=1) 8.3%. Acute urinary retention occurred in two individuals 16.7%.

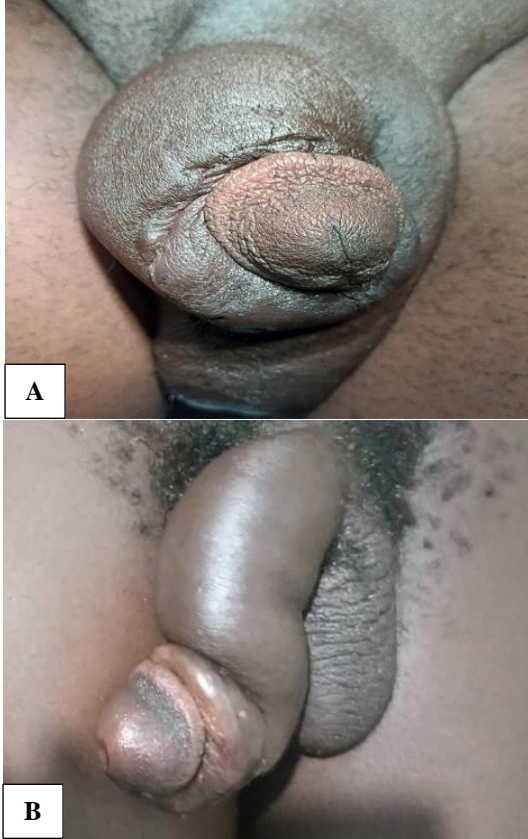

Figure 3 (A and B): Penile fracture with swollen deformed penile shaft (eggplant deformity).

The mean length of corpora rupture was 3.04 cm with a range of 1.5 cm to 4 cm.

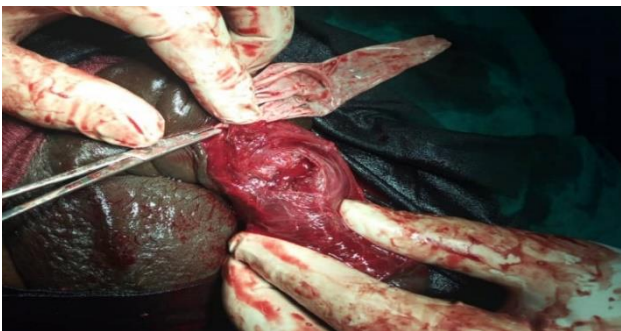

Figure 4: The location of rupture of the corpus cavernosum in penile fracture.

Left lateral penile base was ruptured in 41.7%. Table 1 shows the location of corpora rupture, while Figure 4 shows intraoperative location of corpora rupture. Figure 5

shows bilateral rupture of the corpus cavernosum with transection of urethra following fall on the erect penis.

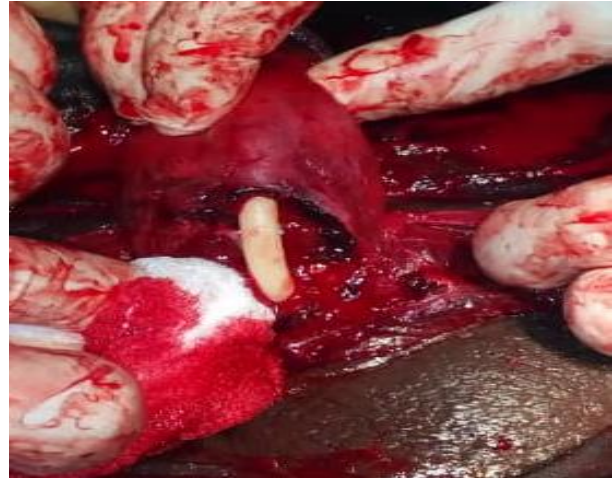

Figure 5: Bilateral rupture of the corpus cavernosum with transection of urethra following fall on the erect penis.

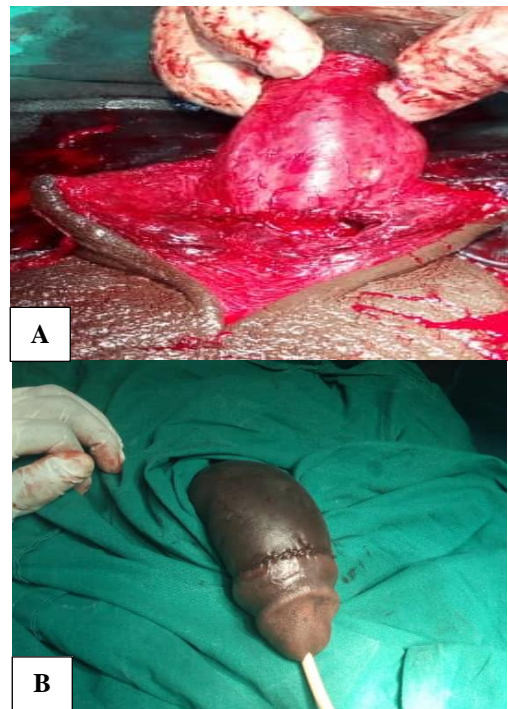


Figure 6: Penile shaft after repair of penile fracture and primary repair of the urethra.

All the patients had repair of the corpora rupture following penile exploration. Circumcoronal incision with degloving was done. The corpora tear was repaired using vicryl sutures. Urethral rupture was repaired primarily. Figure 6 shows penile shaft after repair of penile fracture and primary repair of the urethra. Erection and voiding post-repair were satisfactory.

Table 1: Location of corporal rupture in patients with penile fracture.

Location of injury	Number of patients	Percentage (%)
Left lateral penile base	5	41.7
Right lateral mid shaft	2	16.7
Right lateral penile base	4	33.3
Bilateral ventral rupture	1	8.3
Total	12	100

DISCUSSION

Penile fracture is uncommon in our environment. The only reported incident was by Ugwu et al who reported one case of penile fracture over eleven years in Jos, Nigeria.¹¹ However, there has been a steady rise in reported cases. In Lagos, Nigeria, fifteen cases were reported in five years.⁶ In this study, over twelve months, twelve cases were recorded. This could be explained by the lockdown of 2020 with possible increased intimacy.

The mean age in our study was 34.8 years. This is similar to the report by other authors.^{6,12,13} This is the age when men are sexually active and more likely to experiment.

Early presentation seems to be the norm in patients with fracture of the penis. Most of the patients in this study (75%) presented within 48 hours of trauma. Ekeke et al had 95.2% presentation within 24 hours.¹³ In an environment where patients usually present late, this health-seeking behaviour when it comes to fracture of the penis can be explained by the fact that the penis represents the path to a fulfilled life in a man.¹⁴ It is central to his sense of wellbeing, desirability and every aspect of his masculinity. Hence, the idea of loss of erection is a frightening prospect. Thus, he strives to seek medical care to preserve his erection.

The commonest cause/mechanism of penile fracture in this series was sexual intercourse in the reverse coital position (58%) followed by forceful manipulation of the erect penis. In the reverse coital position, the erect penis slips out of the vagina, forcefully hits the perineum or pubic symphysis, buckles and the corpora ruptures. In their account, Omisanjo et al had 66.7% of the penile fractures resulting from vigorous coitus, while Eke et al also showed sexual intercourse to be the leading cause of penile fracture.^{6,15} However other aetiological factors have been reported. In a report from Quetta, Pakistan, manipulation of the erect penis was the leading cause of penile fracture (40.87%).⁹ Similarly, Zargooshi et al in a series from Iran, showed forceful manipulation of the erect penis, a practice termed taqaandan to be the primary cause of penile fracture (76.4%).¹⁶ Other causes of penile fracture include non-intercourse trauma, masturbation, entrapment of erect penis in bamboo bed and fall onto the erect penis.^{8,17} From the foregoing, cultural variations may play a role in the aetiology of penile fracture. However, sex related trauma remains a significant cause worldwide.

The triad of local pain, detumescence and penile swelling remained constant in all the patients. This is unsurprising as these features underline the entire process of penile fracture. Acute angulation of the penis and subsequent rupture results in pain, with cavernosal blood leaking into the surrounding tissue resulting in penile swelling. The swelling or haematoma is usually confined to the penile shaft if the Buck's fascia remains intact however, it may involve the perineum and anterior abdominal wall if the fascia is breeched.¹⁸ These characteristic features were also reported by Nawaz et al.⁹ All the patients in their study presented with the characteristic sound at the time of injury, pain, detumescence and hematoma. Seventy-five per cent of our patient heard the popping sound. This typical presentation obviates the need for extensive investigations that may not give additional information for diagnosis. Acute urinary retention, haematuria and urethral bleeding are indicative of urethral injury. These symptoms were found in two of the patients. One had bilateral corporal rupture and complete transection of the urethra following a fall. Bilateral corporal rupture is commonly associated with urethral injury.¹⁷

The corporal rupture was unilateral in 91.7%, with the right corpora the most injured, 50% in the index study. Other studies have shown that the right corpora are more commonly fractured.^{6,13,19} The reason why the right corpora are more prone to rupture cannot be readily ascertained. A closer look at the ultra-structure of the corpora may help in unravelling the answer.

All the patients had immediate exploration and repair of the ruptured corpora. The mode of analgesia was saddle block and the preferred incision was circumcoronal with degloving of the penis. This gives good exposure, allows for haematoma evacuation, easy identification of the rupture site and access to accompanying urethral injury where present. The torn edges were freshened, irrigated and repaired using synthetic absorbable (vicryl). Urethral rupture in one of the patients was repaired primarily over a stent (urethral catheter). Surgical management is associated with a good outcome. As demonstrated by various authors, it has become the treatment of choice.^{6,8,20} All our patients had good erection within seven days of repair. Though there may be room for conservative management, especially where the diagnosis is equivocal, this is fraught with complications such as infection of the haematoma, abscess formation, arteriovenous fistula, chordee and erectile dysfunction.²¹

The limitation of this study was the small sample size and the fact that it was a retrospective study.

CONCLUSION

Fracture of the penis is a urological emergency. Clinical diagnosis can be made based on typical history and examination findings. Prompt surgical intervention is advised to avoid complications and erectile dysfunction.

Funding: No funding sources

Conflict of interest: None declared

Ethical approval: The study was approved by the Institutional Ethics Committee

REFERENCES

1. Gulmi FA. Penile Fracture. *Rev Urol.* 2018;20(1):41-2
2. El-Taher AM, Aboul-Ella HA, Sayed MA, Gaafar AA. Management of penile fracture. *J Trauma.* 2004;56(5):1138-40.
3. Lee SH, Bak CW, Choi MH, Lee HS, Lee MS, Yoon SJ. Trauma to male genital organs: a 10-year review of 156 patients, including 118 treated by surgery. *BJU Int.* 2008;101(2):211-5.
4. Shariat M, Sufian M. Role of ultrasound in diagnostic aid of a case of penile fracture. *Shiraz E Med J.* 2008;9(3):158-62.
5. Rodriguez D, Li K, Apoj M, Munarriz R. Epidemiology of penile fractures in United States emergency departments: Access to care disparities may lead to suboptimal outcomes. *J Sex Med.* 2019;16(2):248-56.
6. Omisano OA, Bioku MJ, Ikuerowo SO, Sule GA, Esho JO. A prospective analysis of the presentation and management of penile fracture at the Lagos State university teaching hospital (LASUTH), Ikeja, Lagos, Nigeria. *Afr J Urol.* 2015;21(1):52-6.
7. McDougal WS, Wein AJ, Kavoussi LR, Partin AW, Peters CA. *Campbell-Walsh Urology.* 10th ed. New York: Elsevier Health Sciences; 2016.
8. Mirzazadeh M, Fallahkarkan M, Hosseini J. Penile fracture epidemiology, diagnosis and management in Iran: a narrative review. *Transl Androl Urol.* 2017;6(2):158-66.
9. Nawaz H, Khan M, Tareen FM, Khan S. Penile fracture: presentation and management. *J Coll Physicians Surg Pak.* 2010;20(5):331-4.
10. Koifman L, Cavalcanti AG, Manes CH, Filho DR, Favorito LA. Penile fracture: experience in 56 cases. *International Braz J Urol.* 2003;29(1):35-9.
11. Ugwu BT, Yiltok SJ, Uba AF, Abdulmajid UF. Fracture of the penis-a rare injury on the Jos Plateau, Nigeria. *Central Afr J Med.* 1998;44(4):107-8.
12. El-Taher AM, Aboul-Ella HA, Sayed MA, Gaafar AA. Management of penile fracture. *J Trauma Acute Care Surg.* 2004;56(5):1138-40.
13. Ekeke ON, Eke N. Fracture of the penis in the Niger Delta region of Nigeria. *J West Afr Coll Surg.* 2014;4(3):1-19.
14. Ofoha CG, Magnus FE. Presentation, characteristics and co-morbidities of men with prostate cancer in Nigeria. *J Adv Medicine Med Res.* 2019;31(5):1-7.
15. Eke N. Fracture of the penis. *Br J Surg.* 2002;89(5):555-65.
16. Zargooshi J. Sexual function and tunica albuginea wound healing following penile fracture: an 18-year follow-up study of 352 patients from Kermanshah, Iran *J Sex Med.* 2009;6(4):1141-50.
17. Anselm O, Okechuhwu O. Penile fracture from entrapment of an erect penis in the African Bamboo bed: a case report. *African J Urol.* 2010;16(1):24-6.
18. Kamdar C, Mooppan UM, Kim H, Gulmi FA. Penile fracture: preoperative evaluation and surgical technique for optimal patient outcome. *BJU Int.* 2008;102(11):1640-4.
19. Mbonu OO, Aghaji AE. Fracture of the penis in Enugu, Nigeria. *J R Coll Surg Edinb.* 1992;37:309-10.
20. Al-Shaiji TF, Amann J, Brock GB. Fractured penis: diagnosis and management (CME). *J Sex Med.* 2009;6(12):3231-40.
21. Nicolaisen GS, Melamud A, Williams RD, McAninch JW. Rupture of the corpus cavernosum: surgical management. *J Urol.* 1983;130(5):917-9.

Cite this article as: Ofoha CG, Umana IP, Adewale AG. Fracture of the penis in Jos, Nigeria: review of cases in 2020. *Int J Adv Med* 2021;8:804-8.