

Case Report

Stevens-Johnson syndrome induced by gabapentin and cilostazol in diabetic patient co-infected with COVID-19

I. Kadek Aditya Nugraha^{1*}, Ketut Suryana²,
Dewi Catur Wulandari¹, Tjokorda Dalem Pemayun³

¹Department of Internal Medicine, Wangaya Regional Hospital, Denpasar, Bali, Indonesia

²Department of Pulmonology and Respiratory Medicine Wangaya Regional Hospital, Denpasar, Bali, Indonesia

³Department of Dermatology and Venereology, Wangaya Regional Hospital, Denpasar, Bali, Indonesia

Received: 19 May 2021

Accepted: 17 June 2021

*Correspondence:

Dr. I. Kadek Aditya Nugraha,
E-mail: kadek_adityanugraha@yahoo.com

Copyright: © the author(s), publisher and licensee Medip Academy. This is an open-access article distributed under the terms of the Creative Commons Attribution Non-Commercial License, which permits unrestricted non-commercial use, distribution, and reproduction in any medium, provided the original work is properly cited.

ABSTRACT

Coronavirus disease 2019 (COVID-19) has been declared as an emergent pandemic. COVID-19 mainly present with fever and respiratory symptoms. Its severity ranges from asymptomatic infection, mild, moderate, severe to critical degrees which is related to the degree of dysregulated inflammatory response and systemic inflammation. Stevens-Johnson syndrome (SJS), on the other hand is a rare, severe, type IV hypersensitivity presenting with epithelial destruction of skin and mucous membranes. This condition also associated with systemic proinflammatory state. We report a case of a 73-years-old woman with dry cough and fever, who recently started treatment with cilostazol and gabapentin, then followed by redness and blistering on her lips, trunk, and genital which subsequently diagnosed with COVID-19 and SJS.

Keywords: SJS, COVID-19, Gabapentin, Cilostazol

INTRODUCTION

In late 2019, the coronavirus disease 2019 (COVID-19) first emerged in Wuhan, China. Until March 11, 2021, the infection has been confirmed in 117,332,262 cases including 2,605,356 cases of death.¹ Infection severity varies from asymptomatic to mild and moderate, even severe to critical infection. The degree of immune system dysfunction in response to viral infection determines the seriousness of COVID-19 infection. The dysregulated inflammatory response causes massive increases in levels of pro-inflammatory cytokines, known as cytokine storms. This condition can lead to multiple tissue and organ damage.²

Stevens-Johnson syndrome (SJS) is type of hypersensitivity reaction of the mucous membrane and the skin due to type IV hypersensitivity. It belongs to severe cutaneous adverse drug reactions (SCARs) if the

immunological reactions are provoked by drugs. SJS characterized by epidermal necrosis which cause mucous membranes erosion and widespread epidermal detachment, and severe constitutional symptoms.³ Mortality rate of SJS depends on the extent of skin lesions and organ involvement, with mortality rate around 5%. Involvement of mucous membranes in eye, nasal, oral, genital, gastrointestinal, and lower respiratory tract may develop and contributing to severe morbidity even death.⁴ Here we reported a case of diabetic patient who develop SJS after taking gabapentin and cilostazol and coinfecting with COVID-19 and its management.

CASE REPORT

A 73-years-old woman presented with redness and blistering on her lips, trunk, and genital, which started to developed 2 days before admission. At the time of admission, the patient recently had a history of starting

gabapentin and cilostazol due to diabetic neuropathy for 3 days. The patient also complained dry cough, congested nose, and malaise for 6 days prior to admission, accompanied with fever on the same day she began starting gabapentin and cilostazol. There was no history of anosmia, ageusia, sore throat, and shortness of breath. This patient had history of diabetes mellitus for 10 years, and heart failure due to hypertensive heart disease. She was taking glulisine and glargine for diabetes mellitus, furosemide, spironolactone, bisoprolol and valsartan for heart failure. There was no history of allergy to drugs before the patient was admitted.

Her blood pressure was 158/80 mmHg and temperature were 38.3° C and another vital sign was normal. On physical examination, erythematous rash, vesicles, and skin detachment was found involving lips, trunk and genital region with body surface area involved <10% (Figure 1). Chest X-ray was taken and shown bilateral pulmonary infiltrates (Figure 2). Laboratory test revealed lymphopenia [0.70 x 10³ μl (1.00-4.00)], elevated random blood glucose [(444 mg/dl (80-200)), urea [91 mg/dl (10-50)], creatinine [2.7 mg/dl (0.3-1.2)], C-reactive protein level [100 mg/dl (<2.5)], D-dimer [910.5 ng/dl (<500)], and reactive serology test for IgM Anti SARS-CoV-2.

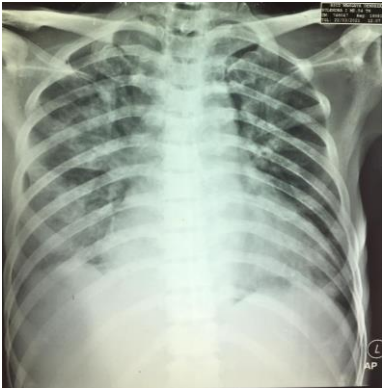


Figure 2: Bilateral pulmonary infiltrates shown by chest X-ray of the patient.

Nasopharyngeal swab test was done and COVID-19 was confirmed by nucleic acid amplification test (NAAT). A clinical diagnosis of SJS established, accompanied with COVID-19, diabetes mellitus, hypertension and heart failure. Gabapentin and cilostazol were discontinued due to the possibility of a drug reaction. Methylprednisolone 62.5 mg/day as intravenous bolus was given for 5 days, subsequently intravenous dose was tapered and oral methylprednisolone was started in 10th day of care followed by tapering dose. Skin and mucosal lesions was cared with topical therapy. Multidrug regiment with levofloxacin, azithromycin, remdesivir, and n-acetylcysteine for COVID-19; basal-bolus insulin regiment with glulisine and glargine for diabetes mellitus; furosemide, valsartan, spironolactone, and bisoprolol for hypertension and heart failure were started to treat following comorbidities. All medications given were tolerated during admission. Marked improvement in the skin and mucous membranes was observed progressively during treatment. Progressive clinical and laboratory improvement related to COVID-19 and comorbidities also observed. Patients was discharged after 16 days of hospitalization with hyperpigmented, scalded skin on lips, trunk, and genital; without residual symptom due to COVID-19.

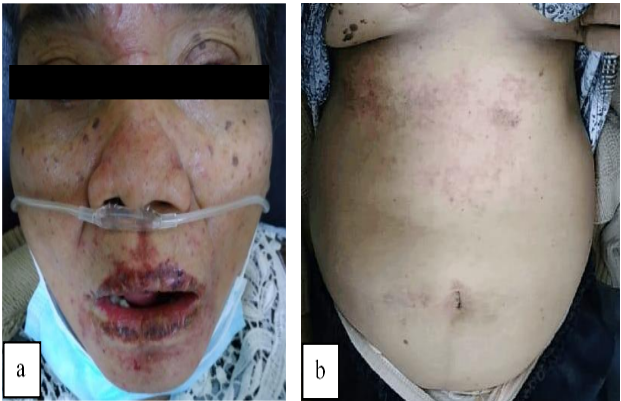


Figure 1: Erythematous rash, vesicles, and skin and mucosal detachment is showed in (a) lips; (b) trunk- and at day 1 of admission.

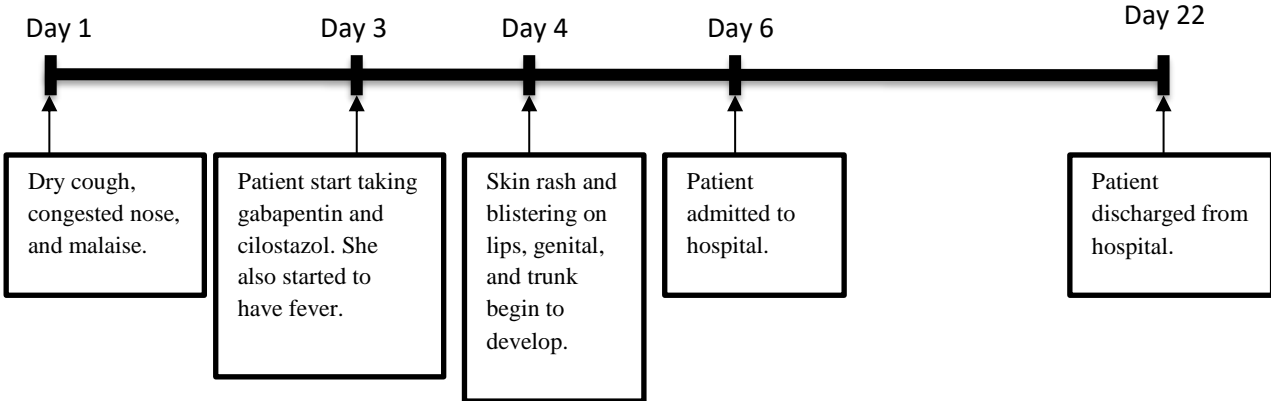


Figure 3: Timeline of case report.

DISCUSSION

In this study, we reported a case of patient with COVID-19 accompanied with SJS. The manifestations of COVID-19 can be asymptomatic or can cause a wide spectrum of symptoms in the form of mild upper respiratory tract infections, pneumonia of varying severity, and even sepsis with multiorgan failure. The pathogenesis of COVID-19 largely results from abnormal and overreaction of immune system, especially in severe and rapidly progressing case. This condition produces high level of inflammatory cytokines, chemokines, and oxidative stress that can damage locally to the lungs or systematically to other organs. Inflammatory cytokines found to be elevated in COVID-19 were TNF- α , TGF β , IFN- α , γ , IL-1 β , IL-2, IL-6, IL-12, IL-18, and IL-33; as well as chemokines such as CCL2, CCL3, CCL5, CXCL8, CXCL9, and CXCL10.⁵ COVID-19 has been related to lymphocyte damage in several studies, especially T lymphocytes, which also contributed to impaired immune response during the period of disease. In COVID-19 patients, total T lymphocytes and their subsets, such as cytotoxic and helper T lymphocytes, were found to be lower than in healthy people and lower T lymphocytes counts associated with its severity.⁶ Despite decreasing numbers of T lymphocytes and its subsets, some studies have found that the T lymphocytes in COVID-19 show signs of T lymphocytes overactivation and exhaustion.^{7,8}

SJS is hypersensitivity reaction that cause epithelial destruction of skin and mucous membrane. SJS involves epidermal detachment of less than 10%, the most severe form is toxic epidermal necrolysis (TEN) TEN with $\geq 30\%$ involvement of total body surface area, and between them which involves 10-29% is SJS-TEN overlap.⁹

Since SJS and TEN have identical clinical characteristics, histopathologic findings, etiology, risk factors, and mechanisms, with only difference is the body surface area involved, they are considered as one disease entity termed as epidermal necrolysis.¹⁰ Most common reported cause of SJS are medications, with several infections such as cytomegalovirus, herpes simplex virus, and mycoplasma pneumonia reported can elicit this condition. In this case, the patient had recent history of taking gabapentin and cilostazol. Gabapentin belongs to antiepileptic drug which also been used for treating neuropathic pain. Antiepileptic drugs are one class of medicine that has been linked to SJS/TEN. When compared to non-AEDs, antiepileptic drugs had a 9-fold increased risk of SJS/TEN.¹¹ Cilostazol, on the other hand, is phosphodiesterase III inhibitor mainly used to treat intermittent claudication caused by peripheral vascular disease. A case of systemic cutaneous hypersensitivity reaction due to the use of cilostazol and antiepileptic drug, in this case was carbamazepine, has previously been reported.¹²

Offending drugs or infections can activate inflammatory cascade in SJS, resulting to keratinocyte apoptosis, blistering, detachment, and systemic inflammation.

Mucocutaneous lesions of SJS is mainly due to overactivation of cytotoxic T lymphocytes and natural killer (NK) cells. Cytotoxic T lymphocytes and natural killer (NK) cells activation will induce downstream signals and mediator to develop extensive keratinocyte apoptosis. Fas and Fas Ligan (FasL), Granulysin, granzyme B/perforin are three major cytotoxic proteins that have been linked to keratinocyte apoptosis.³ Several cytokines and chemokines concentration also increased not only in cutaneous lesions and blister fluid, but also in the plasma of SJS patient. Cytokines such as IL-2, IL-5, IL-6, IL-10, IL-12, IL-13, IL-15, IL-18, IFN- γ , TNF- α and chemokines such as CCR3, CCR10, CXCR3, and CXCR4 are among these cytokines and chemokines.¹³ All of the evidence indicates that T lymphocytes and inflammatory cytokines have a role in COVID-19 and SJS pathogenesis. The increased activity of T lymphocytes and levels of proinflammatory cytokines that occur simultaneously in the pathogenesis of COVID-19 and SJS has the potential to increase morbidity and even mortality in patients.

Here we reported a case of diabetic patient who develop SJS after taking gabapentin and cilostazol and coinfecting with COVID-19. COVID-19 was associated with systemic and dysregulated inflammatory state indicated by increased proinflammatory cytokines/chemokines, and oxidative stress. SJS, on the other hand, causes cytotoxic T and NK cells to become activated, resulting in an increase in the levels of many cytotoxic proteins and proinflammatory cytokines/chemokines, which also indicates systemic inflammatory state. In our case, systemic inflammatory state was shown by marked elevation of CRP. Here we treated the patient with remdesivir and steroid combination, in this case was methylprednisolone. Methylprednisolone dose given was 62.5 mg/day for 5 days then followed by tapering the dose. The steroid dose given is based on consideration of the concurring presence of SJS. The steroid dose given is greater than the recommended steroid dose for treatment of COVID-19, which is dexamethasone 6 mg or its equivalent.¹⁴ Total length of stay of our case was 16 days. It showed longer length of stay compared to mean usual care of SJS, which is 9.8 ± 0.3 days.⁴ The occurrence of COVID-19 and SJS together in these patients showed a significant impact on the length of hospitalization compared to SJS patients without COVID-19.

Another condition that resulted in limitation to the management of these patients was related to the constraints in managing hyperglycemia. As these patients also had diabetes as a comorbid and received steroid at the same time, the setting of the isolation ward made strict blood sugar regulation was impossible due to limitations in regular monitoring blood sugar. This condition also possibly contributed to the outcome of this patient.

Despite all of aforementioned condition, our case showed a progressive improvement and successful treatment. It is possible that the prompt diagnosis of COVID-19 and SJS, elimination of suspected drugs (in our case was gabapentin

and cilostazol were suspected), and administration of steroid targeting the systemic inflammatory state caused by both infection of SARS-CoV-2 and hypersensitivity reaction might contribute to a better outcome of treatment.

CONCLUSION

COVID-19 and SJS are two diseases that both can result in systemic inflammatory state. Prompt diagnosis and treatment to mitigate infection and inflammation can lead to favorable outcome and survival. Despite conflicting result, treatment with higher steroid dose can be considered along with antiviral and other supportive treatments.

Funding: No funding sources

Conflict of interest: None declared

Ethical approval: Not required

REFERENCES

1. WHO. WHO Coronavirus (COVID-19) Dashboard, 2021. Available at: <https://covid19.who.int/>. Accessed on 11 March 2021.
2. Li G, Fan Y, Lai Y, Han T, Li Z, Zhou P, et al. Coronavirus infections and immune responses. *J Med Virol.* 2020;92(4):424-32.
3. Chung WH, Hung SI. Recent advances in the genetics and immunology of Stevens-Johnson syndrome and toxic epidermal necrosis. *J Dermatol Sci.* 2012;66(3):190-6.
4. Hsu DY, Brieva J, Silverberg NB, Silverberg JI. Morbidity and Mortality of Stevens-Johnson Syndrome and Toxic Epidermal Necrolysis in United States Adults. *J Invest Dermatol.* 2016;136(7):1387-97.
5. Mortaz E, Tabarsi P, Varahram M, Folkerts G, Adcock IM. The Immune Response and Immunopathology of COVID-19. *Front Immunol.* 2020;11:2037.
6. Feng X, Li S, Sun Q, Zhu J, Chen B, Xiong M, Cao G. Immune-Inflammatory Parameters in COVID-19 Cases: A Systematic Review and Meta-Analysis. *Front Med.* 2020;7:301.
7. Biasi S, Meschiari M, Gibellini L, Bellinazzi C, Borella R, Fidanza L, et al. Marked T cell activation, senescence, exhaustion and skewing towards TH17 in patients with COVID-19 pneumonia. *Nat Commun.* 2020;11(1):3434.
8. Chen Z, John Wherry E. T cell responses in patients with COVID-19. *Nat Rev Immunol.* 2020;20(9):529-36.
9. Roujeau JC. The spectrum of Stevens-Johnson syndrome and toxic epidermal necrolysis: a clinical classification. *J Invest Dermatol.* 1994;102(6):28-30.
10. Mockenhaupt M. Epidermal Necrolysis (Stevens-Johnson Syndrome and Toxic Epidermal Necrolysis). In: Kang S, Bruckner AL, Enk AH, Margolis DJ, Orringer JS, eds *Fitzpatrick's Dermatology.* 9th ed. New York, NY: McGraw-Hill; 2019: 733-748.
11. Borrelli EP, Lee EY, Descoteaux AM, Kogut SJ, Caffrey AR. Stevens-Johnson syndrome and toxic epidermal necrolysis with antiepileptic drugs: An analysis of the US Food and Drug Administration Adverse Event Reporting System. *Epilepsia.* 2018;59(12):2318-24.
12. Kang SY, Kim JY, Kim MY, Lee SY, Kim MH, Kim TW, et al. Drug-induced hypersensitivity syndrome/drug reaction with eosinophilia and systemic symptoms syndrome induced by cilostazol and carbamazepine. *J Dermatol.* 2012;39(8):723-4.
13. Su SC, Chung WH. Update on pathobiology in Stevens-Johnson syndrome and toxic epidermal necrolysis. *Dermatologica Sin.* 2013;31(4):175-80.
14. Recovery Collaborative Group, Horby P, Lim WS, Emberson JR, Mafham M, Bell JL, et al. Dexamethasone in Hospitalized Patients with Covid-19. *N Engl J Med.* 2021;384(8):693-704.

Cite this article as: Nugraha IKA, Suryana K, Wulandari DC, Pemayun TD. Stevens-Johnson syndrome induced by gabapentin and cilostazol in diabetic patient co-infected with COVID-19. *Int J Adv Med* 2021;8:1235-8.