

Review Article

Fulminant hepatic failure in pregnancy: challenges, management strategies, prognosis and outcomes

Anant Parasher^{1*}, Vandana Mohan²

¹Department of Medicine, Guru Teg Bahadur Hospital, New Delhi, India

²Department of Obstetrics and Gynaecology, Guru Teg Bahadur Hospital, New Delhi, India

Received: 19 May 2021

Accepted: 18 June 2021

Revised: 21 June 2021

***Correspondence:**

Dr. Anant Parasher,

E-mail: anant02jan@gmail.com

Copyright: © the author(s), publisher and licensee Medip Academy. This is an open-access article distributed under the terms of the Creative Commons Attribution Non-Commercial License, which permits unrestricted non-commercial use, distribution, and reproduction in any medium, provided the original work is properly cited.

ABSTRACT

Fulminant hepatic failure is defined as a sudden, severe impairment of hepatic function leading to an encephalopathy, which occurs within eight weeks of appearance of first symptoms in the absence of pre-existing liver disease. The spectrum of liver disease in pregnancy may range from mild asymptomatic transaminitis to fatal and irreversible deterioration in liver function leading to significant morbidity and even mortality. Hepatic dysfunction in pregnancy may be categorized into Pre-eclampsia-associated liver diseases such as pre-eclampsia/eclampsia, the HELLP syndrome and Acute fatty liver of pregnancy (AFLP), and other causes of hepatic dysfunction namely Hyperemesis gravidarum (HG) and Intrahepatic cholestasis of pregnancy (IHCP). For this review, a search was conducted for published articles, case reports and clinical trials in MEDLINE/Pubmed from 1970 to 2020 with the keyword's fulminant hepatic failure, acute liver failure in pregnancy, pre-eclampsia, HELLP and AFLP. We concluded that fulminant hepatic failure is one of the most dreaded complications in pregnancy in obstetrical units worldwide. Mandatory screening for etiology, early diagnosis and initiation of supportive management as soon as possible are absolutely essential to ensure better maternal and fetal outcomes. Effective communication with the obstetrician regarding timely delivery/termination of pregnancy ensures a favourable prognosis in the majority of cases. Liver transplant is a definitive life-saving option for cases of severe fulminant hepatic failure in pregnancy, and management has to be suited to each patient individually, keeping in mind the well-being of both the mother, and the child.

Keywords: Acute fatty liver of pregnancy, Hepatic failure, Pre-eclampsia, Transplantation

INTRODUCTION

Fulminant hepatic failure is defined as a sudden, severe impairment of hepatic function leading to an encephalopathy, which occurs within eight weeks of appearance of first symptoms in the absence of pre-existing liver disease.^{1,2} It is associated with massive necrosis of the hepatocytes and can be lethal when associated with pregnancy.

The spectrum of liver disease in pregnancy may range from mild asymptomatic transaminitis, to irreversible deterioration in liver function leading to significant morbidity and even mortality. About 3-5% of pregnancies

have an accompanying hepatic derangement, with causes including co-incidental liver pathology (most commonly viral hepatitis or gallstones) or an underlying chronic liver disease.³

Hepatic dysfunction in pregnancy is most commonly pregnancy related (Table 1) and may be categorized into pre-eclampsia-associated liver diseases such as pre-eclampsia/eclampsia, the HELLP syndrome and Acute fatty liver of pregnancy (AFLP), and other causes of hepatic dysfunction namely Hyperemesis gravidarum (HG) and Intrahepatic cholestasis of pregnancy (IHCP).^{4,5} The conditions leading to fulminant hepatic failure in pregnancy have also been described (Table 2).

Table 1: Liver diseases unique to pregnancy- an overview.⁵

Pregnancy associated hepatic dysfunction	Features
Pre-eclampsia/ eclampsia	<ul style="list-style-type: none"> ➤ Common in multifetal and multiparous pregnancies. ➤ Present after 20 weeks of gestation with oedema, seizures, hypertension and renal failure with proteinuria. ➤ Treatment is with early delivery along with beta blockers, methyldopa, and magnesium sulphate. ➤ High risk of maternal mortality, prematurity and foetal death.
Hemolysis, elevated liver enzymes and low platelets (HELLP) syndrome	<ul style="list-style-type: none"> ➤ Presents mostly beyond 22 weeks gestation and sometimes post-partum, with abdominal pain, seizures, pulmonary edema and renal failure. ➤ Associated with hemolysis and high LDH levels, elevated liver enzymes (AST, ALT 70-6000 IU/l), thrombocytopenia and raised d-dimer levels. ➤ Prompt delivery is the only definitive treatment. ➤ Liver rupture can occur with high foetal and maternal mortality.
Acute fatty liver of pregnancy (AFLP)	<ul style="list-style-type: none"> ➤ Common with primiparous and multifetal gestations. ➤ Mostly presents in the third trimester or post-partum period with hypoglycemia, encephalopathy and rapid progression to hepatic failure. ➤ Associated with thrombocytopenia, elevated AST and ALT, bilirubin, prothrombin and d-dimer levels. ➤ Treatment is via prompt delivery; liver transplantation for refractory cases. ➤ High maternal mortality with fetal mortality up to 45%.
Hyperemesis gravidarum (HG)	<ul style="list-style-type: none"> ➤ Seen more commonly in primiparous females. ➤ Presents in the first trimester with intractable nausea, vomiting and dehydration. ➤ Usually self-resolving and treatment is supportive with intravenous fluids and thiamine supplementation.
Intrahepatic cholestasis of pregnancy (IHCP)	<ul style="list-style-type: none"> ➤ Common in multifetal gestations. ➤ Presents in the second trimester with pruritus and high bile acid levels. ➤ Treatment is with Urso-deoxycholic acid, and delivery recommended at 37-38 weeks.

Table 2: Causes of fulminant hepatic failure in pregnancy.³

Category	Condition leading to fulminant hepatic failure
Conditions associated with pregnancy	<ul style="list-style-type: none"> ➤ Pre-eclampsia/eclampsia ➤ Syndrome of hemolysis, elevated liver enzymes and low platelets (HELLP syndrome) ➤ Acute fatty liver of pregnancy (AFLP) ➤ Hyperemesis gravidarum (HG) and intrahepatic cholestasis of pregnancy (IHCP)- Both usually benign and rarely progressing to fulminant hepatic failure.
Conditions decompensated by pregnancy	<ul style="list-style-type: none"> ➤ Viral hepatitis ➤ Budd-Chiari syndrome (BCS) with portal vein thrombosis
Conditions unrelated to pregnancy	<ul style="list-style-type: none"> ➤ Drugs/toxins/mushroom poisoning ➤ Shock/trauma ➤ Decompensation of pre-existent liver disease

Pre-eclampsia/eclampsia

Pregnancy can be complicated by certain hypertension associated disorders such as pre-eclampsia, eclampsia, HELLP syndrome, hepatic infarction and in severe cases, liver rupture.^{3,6} Pre-eclampsia is a multisystem disorder defined by elevated blood pressure and proteinuria that occurs after 20 weeks of gestation.⁷

It involves endothelial dysfunction and fibrin deposition, and is seen in the third trimester of 5-10% pregnancies. It is the most common cause of hepatic tenderness and dysfunction in pregnancy; hepatic involvement always indicating severe pre-eclampsia.

Nulliparity, extremes of maternal age, insulin resistance and obesity are the risk factors predisposing to this disease.⁸ Diagnostic criteria for pre-eclampsia include a blood pressure of 140 mmHg or higher systolic or 90 mmHg or higher diastolic pressure on two occasions at least 4 hrs apart after 20 weeks of gestation in a woman with previously normal blood pressure, along with proteinuria of 0.3 gm or more in a 24 hrs urine sample.

Severe pre-eclampsia is diagnosed when the systolic blood pressure rises to greater than 160 mmHg and diastolic pressure greater than 110 mmHg on two occasions at least 4 hours apart, along with the presence of thrombocytopenia, impaired liver function, progressive renal insufficiency, pulmonary edema and new-onset cerebral or visual disturbances.⁹

The clinical presentation may vary from being asymptomatic with hypertension and proteinuria, to presenting with symptoms of severe pre-eclampsia, such as upper abdominal pain, severe headache and visual disturbances. Most patients present with abdominal pain, nausea, vomiting and weight gain due to edema. Eclampsia involves all the features of pre-eclampsia along with neurologic symptoms such as headaches, visual disturbances, seizures or coma. Complications associated with pre-eclampsia/eclampsia include Intra-uterine growth retardation, cerebrovascular events, pulmonary edema, renal or hepatic failure and HELLP syndrome.¹⁰

HELLP syndrome (hemolysis, elevated liver enzymes, and low platelets)

The syndrome presents most frequently in the third trimester of pregnancy and is characterized by microangiopathic hemolytic anemia, hepatic dysfunction and thrombocytopenia.⁸

It is seen in approximately 10-20% women with severe pre-eclampsia. Most patients present with upper abdominal pain and tenderness, nausea and vomiting, malaise, headache, edema and weight gain, hypertension, and proteinuria; although jaundice is uncommon. HELLP is more common in multiparous females but can occur with any parity and age.⁴ The diagnosis requires the presence of

all three laboratory criteria: hemolysis, elevated aminotransferases and thrombocytopenia; the ongoing hemolysis suggested by the presence of fragmented red blood cells on peripheral smear, bilirubin concentration of ≥ 1.2 mg/dl and low serum haptoglobin.^{4,11} Aminotransferase elevation ranges from 10-fold to 20-fold, and bilirubin is usually less than 5 mg/dl.

Imaging studies such as computed tomography scan (CT) of the liver may show sub-capsular hematomas, intra-parenchymal hemorrhage, peri-hepatic effusions or hepatic rupture in the background of severely decreased platelet counts.

Complications include disseminated intravascular coagulation (DIC), abruptio placentae, acute renal failure, pulmonary edema, intra-cerebral hemorrhage, liver hematoma/rupture and fulminant liver failure. Acute respiratory distress syndrome may be seen in the newborn infant, along with severe growth retardation.^{3,4}

Acute fatty liver of pregnancy (AFLP)

Acute fatty liver of pregnancy (AFLP) is a sudden catastrophic illness occurring almost exclusively in the third trimester, where micro-vesicular fatty infiltration of the liver results in encephalopathy and hepatic failure.^{12,13} The pathogenesis is due to an abnormality in the metabolism of long chain fatty acids in the fetus, due to a deficiency in the enzyme Long-chain 3-Hydroxyacyl-CoA dehydrogenase (LCHAD).

The maternal circulation is flooded with the fetal long chain fatty acids, overwhelming the capacity of the maternal liver to metabolize them adequately. There is excessive deposition of these fatty acids in the maternal liver, causing micro-vesicular infiltration and ultimately culminating in hepatic failure.^{14,15}

The increase in the serum bilirubin levels is due to the severely impaired metabolic activity of the liver. It usually occurs around the 36th week of gestation; the risk factors including primiparity, pregnancy with a male fetus, multiple gestations, advanced maternal age, and low body mass index of the mother.¹⁶ The condition is neither infectious nor inherited, but has been reported to recur in subsequent pregnancies.¹⁷

The typical patient presents with anorexia, nausea and vomiting for a couple of weeks, headache and right upper quadrant pain, along with an elevated blood pressure. Severe jaundice, coagulopathy, hepatic encephalopathy, ascites and hypoglycemia in presence of a normal erythrocyte morphology and haptoglobin levels are pathognomonic of AFLP.

About 50% of patients with AFLP have pre-eclampsia, and some patients also show features of HELLP syndrome. Intra-uterine complications in AFLP including fetal death are not uncommon. Typical laboratory findings are

elevation of aminotransferases i.e.; Aspartate transferase (AST) elevation greater than Alanine transferase (ALT), hyperbilirubinemia, hyperuricemia, high white blood cell (WBC) count (above 15,000 cells/ μ l), hypoglycemia, high ammonia levels and coagulopathy with or without DIC.

Liver biopsy is the gold standard but is not required for diagnosis.

The important differential diagnoses to be considered are fulminant viral hepatitis and severe HELLP syndrome, the latter usually being encountered in the background of severe pre-eclampsia.

Viral hepatitis

Nearly 35-40% cases of jaundice in pregnancy are due to viral hepatitis i.e., hepatitis A, B, C, D, E, herpes simplex, cytomegalovirus and Epstein-Barr viruses. Among these, hepatitis E virus (HEV) infection has the potential to take a fulminant course with high mortality in the third trimester, probably influenced by malnutrition.

HEV shows hyper-endemicity in India with a prevalence of almost 50% and it is also the most important acute etiology leading to acute-on-chronic liver failure (ACLF).^{18,19} Mortality is high among the HEV positive pregnant females due to the diminished cellular immunity and a high level of endogenous steroid hormones. Both these factors influence viral replication/expression during pregnancy and are responsible for the increased severity of the disease.²⁰ The incubation period ranges from 15-60 days, with the course of infection consisting of the prodromal phase and the icteric phase.

The prodromal phase is usually short and presents with myalgia, arthralgia, fever, anorexia, nausea/vomiting, weight loss (typically 2-4 kg), dehydration and a right upper quadrant pain that increases with physical activity. Icteric-phase symptoms may last days to several weeks and include jaundice, dark urine, light-colored stools and pruritus in most cases.²¹

Neurological and renal sequelae may occur in severe disease. There is also an increased incidence of fetal malformations, pre-term labour, abortion, intra-uterine death and stillbirth.²² The elevation of transaminases is higher in viral hepatitis, seen to be almost ten times the baseline values.

Herpes simplex virus (HSV) hepatitis is seen in about 2% of pregnant women, most probably caused due to restricted T cell function that occurs in the third trimester in order to prevent rejection of the fetus. There is absence of jaundice, and a marked elevation of AST and ALT with a very high AST/ALT ratio.²³ Patients infected primarily during

pregnancy may face a higher risk for fulminant liver failure.

Budd Chiari syndrome

Budd-Chiari syndrome is a syndrome characterized by occlusion of the hepatic veins, with subsequent obstruction to the hepatic venous outflow.

It is associated with sinusoidal congestion and necrosis of hepatocytes around the central vein. Most cases occur during the post-partum period, and have an underlying predisposing condition, such as factor V Leiden, anti-thrombin III, protein C or S deficiency, or the presence of anti-phospholipid antibodies.⁷

The most common causes of Budd-Chiari syndrome include myeloproliferative disorders, and the associated hypercoagulability as well as the pregnancy itself also pose as risk factors for the development of this disease.^{3,24} Clinical manifestations include abdominal pain and distension due to ascites.

On physical examination, findings include hepatomegaly with absence of the hepato-jugular reflux. Although doppler ultrasonography of the right upper quadrant of the abdomen and abdominal CT scans are helpful, venography still remains the gold standard for diagnosis as it demonstrates the site of occlusion.^{24,25}

Autoimmune hepatitis

Autoimmune hepatitis (AIH) is an autoimmune disease of the liver which is more common in women than in men, with a pathology characterized by progressive hepatocellular inflammation that cannot be explained by alcohol consumption, viral infection, hepatotoxic drugs, or genetic disorders.²⁶

Pregnancy in these patients is associated with a higher than normal rate of miscarriage, stillbirth, and premature delivery, and the presence of portal hypertension with esophageal varices increases the risk of bleeding during the latter half of pregnancy.²⁷

Flares are commonly seen in the post-partum period due to the augmentation of a previously suppressed immune system during pregnancy, causing an amplification of disease activity.²⁸

Fetal outcomes have been found to be favorable if the disease activity is well controlled.^{27,29} A diagnostic algorithm has been described below in Figure 1 as a general approach to a pregnant patient presenting with fulminant hepatic failure.³⁰

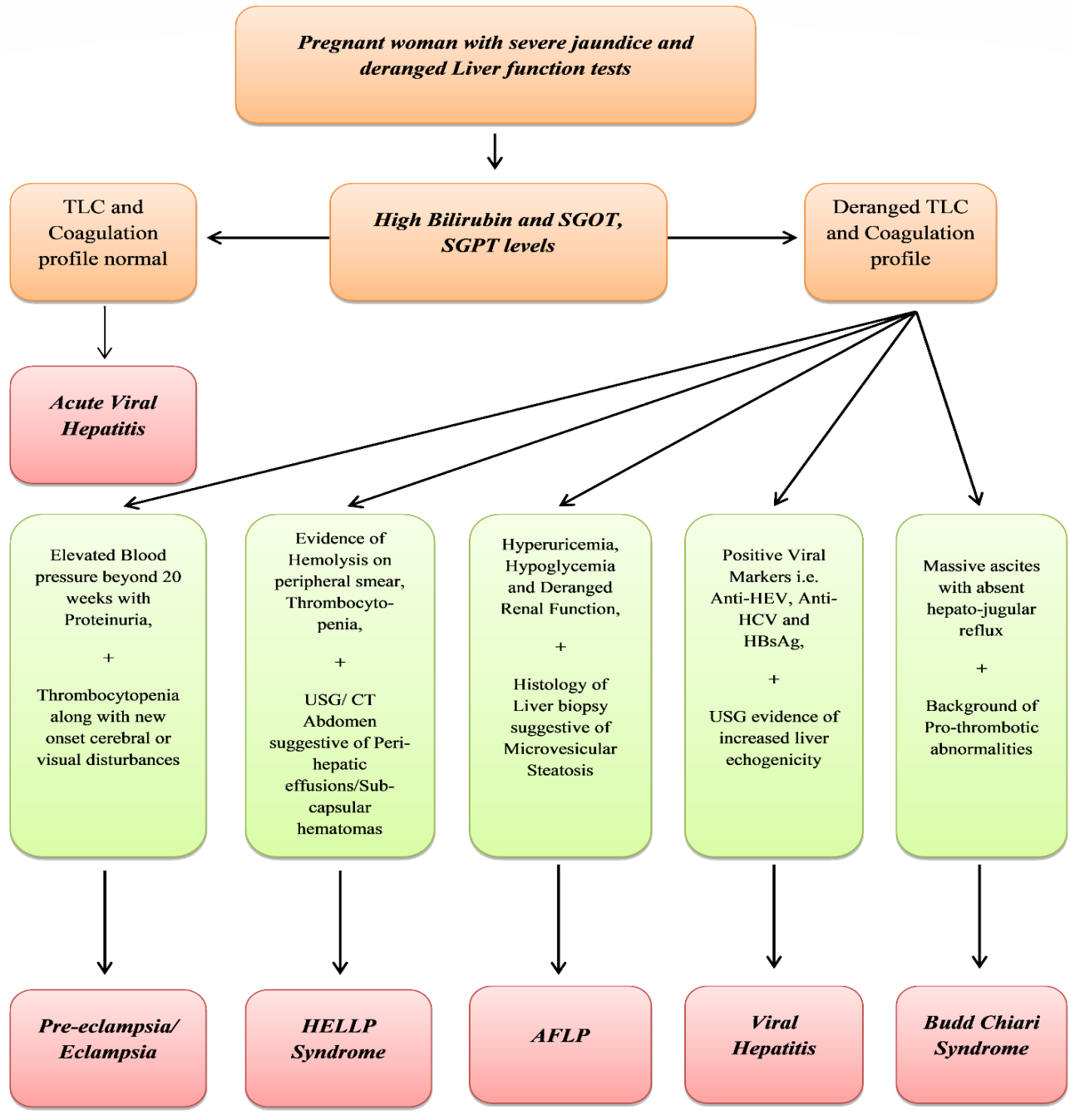


Figure 1: Diagnostic approach to fulminant hepatic failure in pregnancy.³⁰

MANAGEMENT OF FULMINANT HEPATIC FAILURE IN PREGNANCY

(A) General management

It includes- (a) Management of cerebral edema and prompt initiation of antibiotic prophylaxis; (b) Correction of coagulopathy with fresh frozen plasma; (c) Volume replacement and vasopressor support as required; (d) Correction of metabolic derangements such as hypoglycemia, metabolic acidosis and dyselectrolytemia,

as well as maintaining nutritional supplementation; and (e) Etiology specific treatment i.e.; N- acetylcysteine for paracetamol poisoning, acyclovir for herpes simplex/varicella zoster and corticosteroids/azathioprine for autoimmune hepatitis.³

(B) Specific management

A general scheme of the medical and obstetric management has been shown below in Figure 2 and 3 respectively.

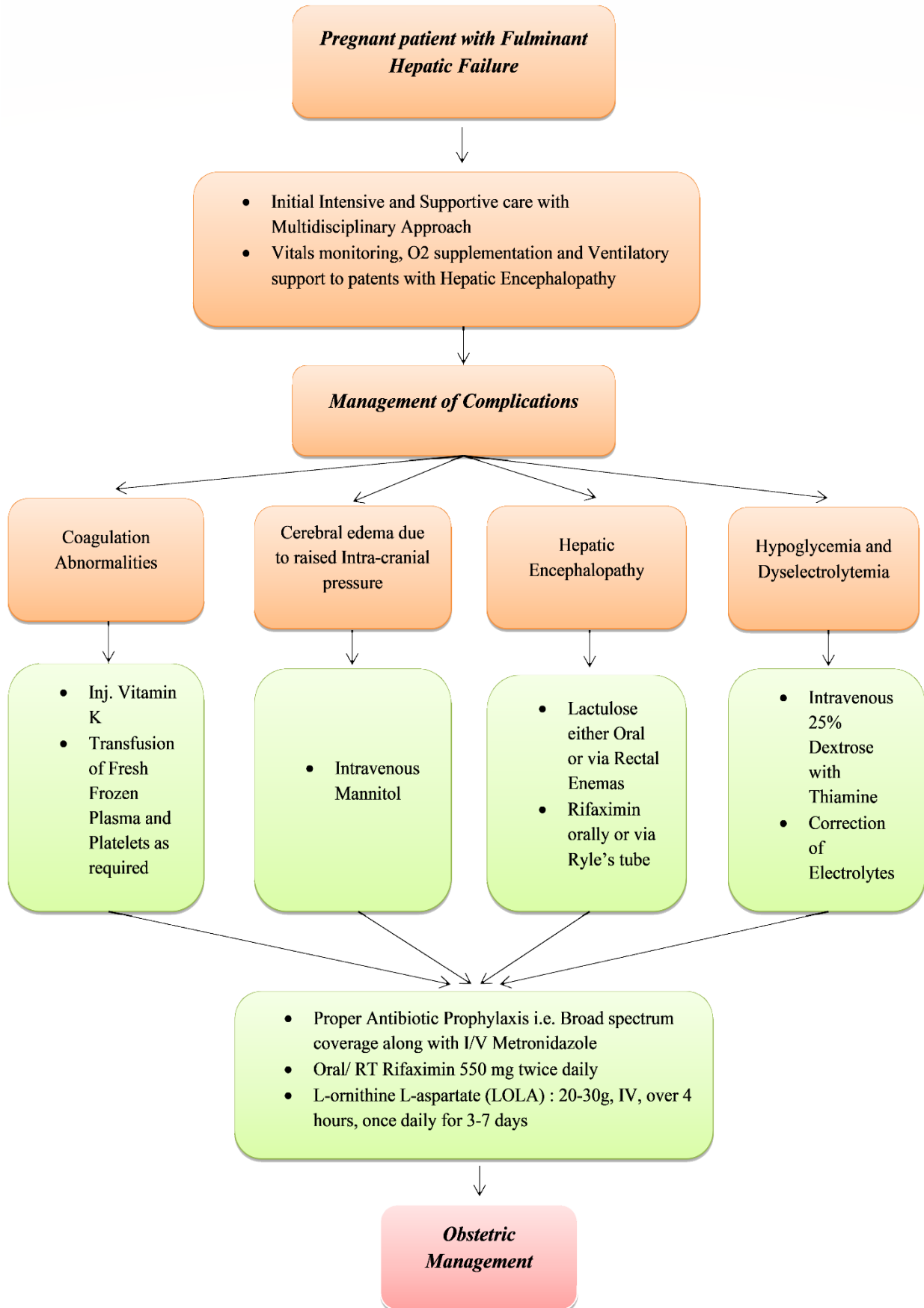


Figure 2: Medical management of fulminant hepatic failure in pregnancy.³⁰

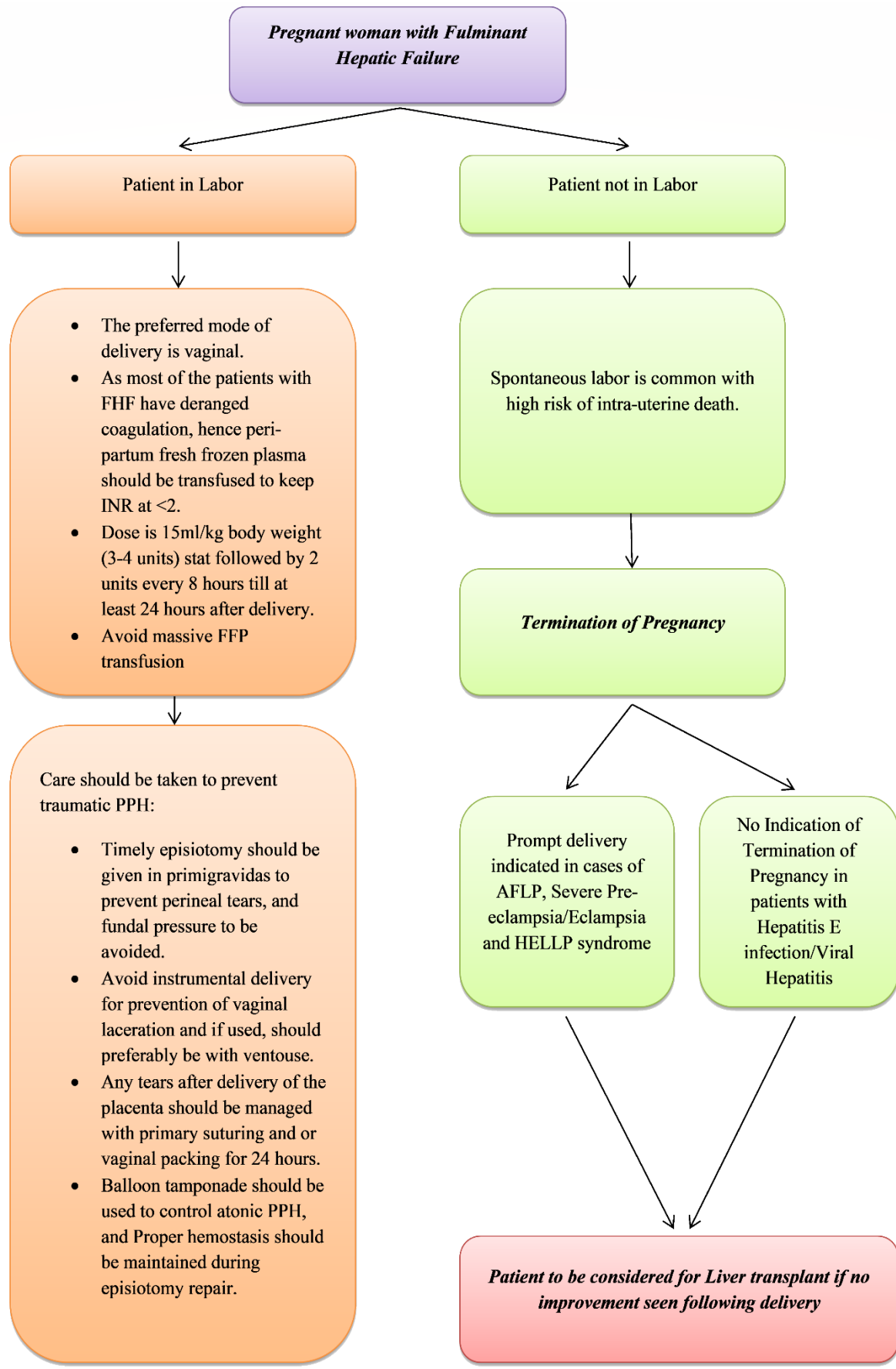


Figure 3: Obstetric management of fulminant hepatic failure in pregnancy.³⁰

Pre-eclampsia and eclampsia

Timely delivery remains the definitive treatment for pre-eclampsia, with clear indications for inducing labor being gestational age of 38 weeks or more, severe intrauterine growth retardation, oligohydramnios and thrombocytopenia.⁹ Other complications which necessitate delivery are hepato-renal failure, suspected placental abruption, persistent severe headache or visual changes, and eclampsia.³¹ Unless the pregnancy is complicated by coagulopathy, vaginal delivery is preferable to avoid the added physiological stressors of cesarean delivery.

During labor, the management goals are to prevent seizures and control hypertension.⁹ Magnesium sulfate has been shown to be superior to phenytoin and diazepam, and is the medication of choice for the prophylaxis and treatment of women with eclamptic seizures.^{10,32} Labetalol and methyldopa are the anti-hypertensive drugs most commonly used in women with severe pre-eclampsia; although labetalol therapy should not be used in women with asthma or congestive heart failure. Angiotensin-converting enzyme (ACE) inhibitors are contraindicated in pregnant women owing to their teratogenicity.⁷

HELLP syndrome

Immediate hospitalization is required for antepartum stabilization of hypertension, seizure prophylaxis and for fetal monitoring. Delivery is the only definitive therapy, as there always exists a strong possibility of progressive and often sudden maternal deterioration.¹¹ Immediate delivery should be affected at greater than 34 weeks gestation or at any evidence of multi-organ dysfunction, disseminated intravascular coagulation, renal failure, abruptio placentae or fetal distress.

Many complicated cases require a cesarean section, especially a primigravida remote from term. Hypovolemia, anemia and coagulopathy if present, need to be corrected with blood products, along with prophylactic antibiotics for cover against sepsis.⁴ At less than 34 weeks gestation, perinatal outcome is better when corticosteroids are used for 24 to 48 hours with delivery and thereafter, for augmentation of fetal lung maturity. Plasmapheresis and plasma exchange with fresh-frozen plasma or dialysis may be needed in cases which do not resolve, have persistent thrombocytopenia/hemolysis for more than 72 hours, or show significant hepatic or renal failure.

Hepatic hemorrhage without rupture is managed with close hemodynamic monitoring in an intensive care unit, correction of coagulopathy, immediate large-volume transfusion of blood products with surgical intervention for rupture or rapid expansion of hematoma as required. Liver rupture is a rare, life-threatening complication of HELLP, usually seen after an intra-parenchymal hemorrhage/sub-capsular hematoma in the right lobe in patients with severe thrombocytopenia. The best surgical

management is immediate laparotomy and evacuation of the hematoma, with pressure packing and drainage. Hepatic artery embolization/ligation and partial hepatectomy are some of the options that may be considered in complicated cases.⁴ Liver transplantation should be considered in cases with liver failure from extensive necrosis, persisting bleeding from a hematoma or an unresolved hepatic rupture in spite of active intervention.³³

Acute fatty liver of pregnancy

Early recognition and diagnosis of AFLP with immediate termination of pregnancy is essential, as there are no reports of recovery before delivery. Immediate hospital admission allows maternal stabilization, fetal monitoring, and confirmation of diagnosis. Delivery is usually by caesarean section, but the type of delivery should be based on an obstetric assessment of the likelihood of rapid controlled vaginal delivery in less than 24 hrs.

Vaginal delivery will reduce the incidence of major intra-abdominal bleeding, and prophylactic antibiotics are recommended to prevent uterine infections.^{4,13} As with HELLP syndrome, maternal stabilization includes airway management and correction of hypoglycemia, electrolyte and coagulation abnormalities. Careful maintenance of intravascular volume with necessary fluids and blood products, frequent assessment of maternal vital signs and evaluation of changes in mental status are crucial. Supportive care and management of complications should be instituted along with the management of hepatic failure.³

Improvement is seen in most patients by one to four weeks post-partum, although a cholestatic phase with rising bilirubin and alkaline phosphatase may persist. Recovery can occur in days or be delayed for months but is complete with no signs of chronic liver disease.⁴ Orthotopic liver transplantation should be considered for those women who manifest signs of irreversible liver failure despite delivery and aggressive supportive care.^{3,34} Successful use of Molecular adsorbent recirculating system (MARS) has been reported in a 31 years old woman presenting with severe AFLP at 32 weeks of gestation.³⁵

Viral hepatitis

Acute viral hepatitis A and E

Management should be predominantly preventive for hepatitis A and E, relying on clean drinking water, good sanitation, and proper personal hygiene. Acute hepatitis A virus (HAV) infection is usually self-limited during pregnancy, and the treatment is mainly supportive.⁴ Acute hepatitis E in immuno-competent patients usually only requires symptomatic treatment, as almost all of them are able to clear the virus spontaneously. As the acute illness may result in repeated vomiting and dehydration, the patients should attempt to ingest frequent small meals

along with adequate oral rehydration. Hospitalization should be considered for patients with immunosuppression or severe dehydration and systemic symptoms, which should be treated promptly with necessary fluid support and electrolyte replacement.³⁶

Hepatitis E is preventable by vaccination, as shown by the high efficacy of a recombinant genotype 1 HEV vaccine (Hecolin) in preventing infection and clinical disease.^{37,38}

Although some trials have shown improved hepatic function on treatment with ribavirin for severe acute hepatitis E infection in non-pregnant patients, it is absolutely contraindicated in pregnancy owing to severe fetal toxicity.³⁹

Viral hepatitis B

Acute hepatitis B is managed conservatively with proper nutritional and fluid support, as in non-pregnant patients. Acute flare of pre-existing chronic hepatitis B may be treated with lamivudine or tenofovir. Antiviral therapy by these nucleoside/nucleotide analogues in the third trimester may reduce vertical transmission in patients with HBeAg positive status and a high viral load, who are most at risk of vertical transmission to their babies.^{4,40} All pregnant women need to be tested for hepatitis B on first antenatal visit, and high-risk cases for HBV infection should be vaccinated promptly. The approach to a pregnant patient with hepatitis B has been depicted below in Figure 4.⁴¹

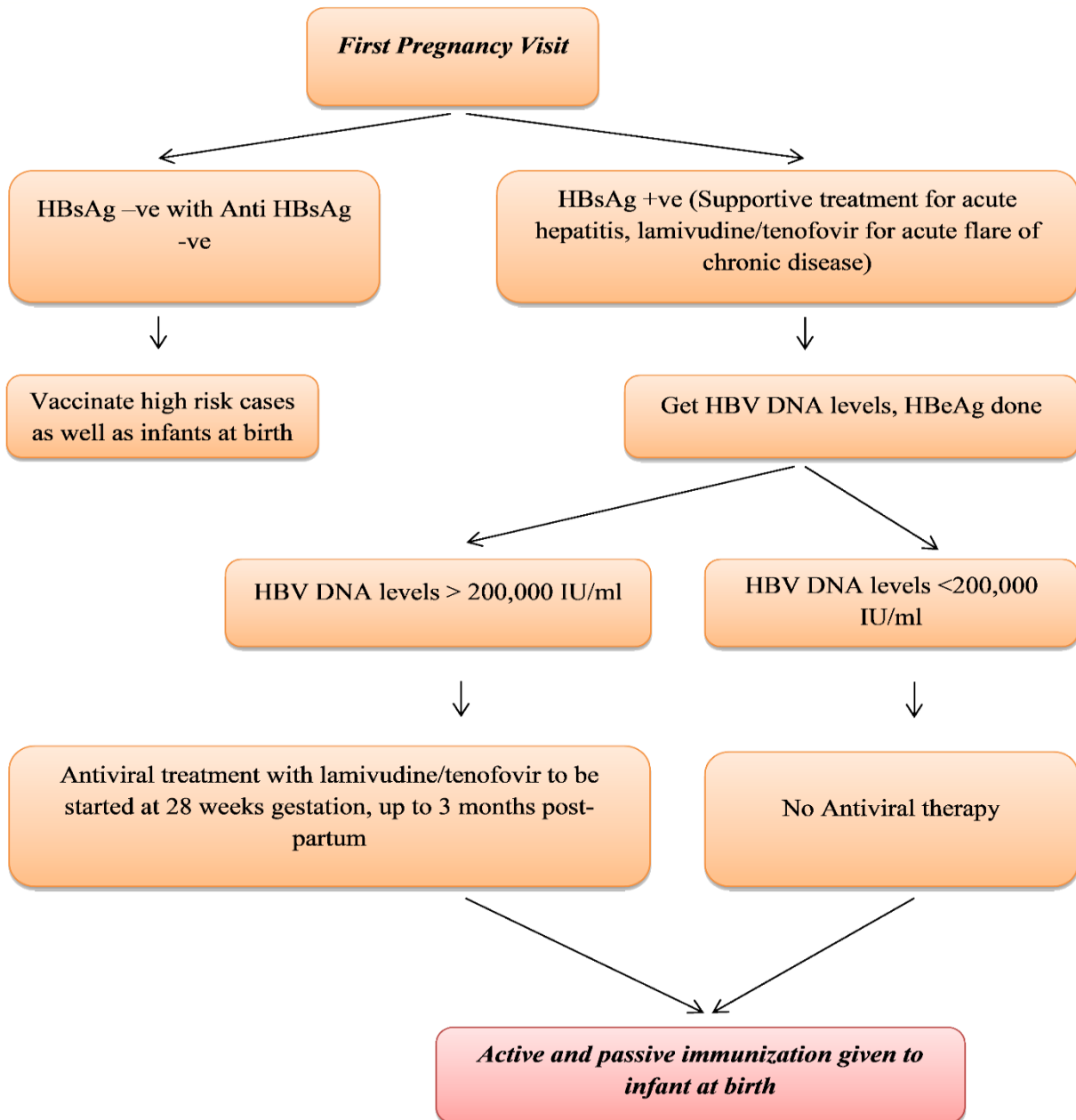


Figure 4: Approach to a pregnant patient with hepatitis B.

Viral hepatitis C

Treatment of HCV infection is contraindicated in pregnancy because of the teratogenicity of the drugs used. The indication for cesarean section should be based on obstetrical reasons, and breast-feeding should not be discouraged. Mother to infant transmission of hepatitis C is 1% to 5%, with maternal risk factors being Human immunodeficiency virus (HIV) co-infection, history of intravenous drug abuse, and high maternal viremia.

Herpes simplex hepatitis and cytomegalovirus hepatitis

For Herpes simplex (HSV), oral acyclovir 400 mg three times daily for 7 to 10 days should be given as a standard protocol. Intravenous administration of acyclovir may be beneficial for pregnant women with severe genital HSV infection or disseminated herpetic infections. Cesarean section is strongly advisable if the mother presents with muco-cutaneous lesions at delivery.⁵ Infection with Cytomegalovirus (CMV) in pregnancy is common and can manifest as a mononucleosis-like illness, with a high risk of transmission to the fetus if the infection is acquired before 22 weeks of gestation. The infection can cause mental retardation and congenital malformations, and there is presently no effective and safe therapy during pregnancy.⁵

Therapeutic termination of pregnancy has not been found beneficial in cases of viral hepatitis.^{3,42}

Chronic liver disease

In pregnant women with chronic liver disease, an uncomplicated pregnancy without disease flare is expected in those with mild or inactive disease. In chronic viral hepatitis, aminotransferases may fall and viral RNA may increase during pregnancy, with normalization in the post-partum period. The course of autoimmune hepatitis in pregnancy is highly variable, and stable immunosuppression should be continued throughout pregnancy. Patients with Wilson's disease must be adequately treated before pregnancy and continued on therapy throughout to prevent the risk of fulminant disease.⁴³ The safety profile of drugs used for the treatment of chronic liver disease has been shown in Table 3.⁴⁴

Successful pregnancy may be completed in those with well-compensated cirrhosis and only mild portal hypertension. However, many cases conclude with increased fetal loss; the main risk to the mother being variceal bleeding and rupture of splenic aneurysms. Beta blocker therapy is introduced for patients with large varices, despite occasional fetal side effects (Table 3). Acute variceal bleeding is managed endoscopically or by shunt surgery as in non-pregnant cases. Vaginal deliveries with short second stage are preferable, but caesarean section is recommended in patients with known large varices. This recommendation has been done to avoid increase in the portal pressure and risk of variceal bleeding due to labor.⁴

Table 3: Drugs indicated for chronic liver disease in pregnancy.⁴⁴

FDA category	Drugs	Remarks
B (Relatively safe)	Ursodeoxycholic acid (UDCA) Octreotide	<ul style="list-style-type: none"> • UDCA safe to use • Limited data on octreotide
C (Mild toxicity)	Prednisone Cyclosporine Tacrolimus Mycophenolate mofetil Lamivudine Entecavir Interferon Beta blockers (1 st trimester) Trientine	<ul style="list-style-type: none"> • Use of mycophenolate mofetil, entecavir and Interferons is not recommended. • Risk of IUGR with beta blockers.
D (Use if benefits outweigh risks)	Beta blockers (2 nd or 3 rd trimester) Penicillamine	Risk of fetal bradycardia with beta blockers
X (Absolutely contraindicated)	Ribavirin Vasopressin	Absolutely contraindicated

Budd Chiari syndrome

Treatment for Budd Chiari syndrome in pregnancy is anticoagulation and prevention of further thrombosis by heparin, unless contraindicated by bleeding disorders. Surgical intervention to decompress the liver, or Trans-jugular intrahepatic porto-systemic shunt (TIPSS) placement are less feasible options in the presence of a gravid uterus. Liver transplantation has been shown to be

effective in many patients, supplemented with heparin anticoagulation.^{24,25}

Autoimmune hepatitis

Although azathioprine and prednisone use in pregnant women slightly increases the risk of adverse fetal outcomes, these are the only drugs for autoimmune hepatitis that have been shown to suppress symptoms,

prolong life and suppress liver inflammation. Well-controlled AIH for at least a year before pregnancy leads to the best fetal and maternal outcomes.²⁸ Flares during pregnancy should be managed with higher doses of prednisone and/or the addition of azathioprine, and these drugs should be continued during breastfeeding as their

levels have been shown to be very low in breast milk samples.²⁹ Mycophenolate mofetil is contraindicated in pregnancy owing to the high risk of congenital malformations. A brief summary of all management protocols has been described in Table 4.

Table 4: Recommended statements.¹⁵

Diseases and disorders	Statements
Initial evaluation of pregnant patient	➤ A pregnant patient presenting with abnormal liver tests should undergo standard workup as with any non-pregnant individual.
Imaging in pregnancy	<ul style="list-style-type: none"> ➤ Ultrasound is safe and the preferred imaging modality used in assessment of abnormal liver tests suggestive of biliary tract disease. ➤ Magnetic resonance imaging without gadolinium can be used in the second and third trimester. ➤ Computed tomography scans may be used judiciously with minimized radiation protocols (2-5 rads) due to risk of teratogenicity and malignancy. ➤ Endoscopy is safe in pregnancy but should be deferred until the second trimester if possible.
Hyperemesis gravidarum	➤ The treatment is supportive and may occasionally require hospitalization.
Intrahepatic cholestasis of pregnancy	<ul style="list-style-type: none"> ➤ Owing to increased risk of fetal complications with IHCP, early delivery at 37 weeks is recommended. ➤ Ursodeoxycholic acid should be given at 10-15 mg/kg for symptomatic improvement.
Pre-eclampsia/eclampsia	➤ Delivery after 36 weeks is recommended in women with severe preeclampsia, to limit maternal and fetal complications.
HELLP syndrome	<ul style="list-style-type: none"> ➤ HELLP syndrome should be managed by prompt delivery, especially after 34 weeks gestation. ➤ Platelet transfusion to 40,000-50,000 cells/mm³ should be considered before delivery, especially if cesarean section is likely.
Acute fatty liver of pregnancy (AFLP)	<ul style="list-style-type: none"> ➤ Women with AFLP should be delivered promptly; expectant management is not appropriate. ➤ All women with AFLP and their children should have molecular testing done for long-chain 3-hydroxyacyl-CoA dehydrogenase.
Hepatitis A, hepatitis E, herpes simplex virus	<ul style="list-style-type: none"> ➤ Pregnant women presenting with Acute Hepatitis A/E should be managed conservatively. ➤ Hepatitis E cases should be monitored thoroughly in view of risk of fulminant hepatic failure. ➤ Pregnant women with Acute Hepatitis suspected from HSV should be initiated on acyclovir.
Hepatitis B in pregnancy	<ul style="list-style-type: none"> ➤ Acute hepatitis is managed conservatively; acute flare of chronic disease can be treated with lamivudine/tenofovir. ➤ Women chronically infected with HBV and high viral load (>10⁶ log copies/ml (200,000 IU/ml) should be offered antiviral medication with tenofovir or telbivudine in the third trimester to reduce perinatal transmission of HBV. ➤ C-section should not be performed electively in HBV-positive mothers to prevent fetal infection.
Hepatitis C in pregnancy	<ul style="list-style-type: none"> ➤ C-section should not be performed electively in HCV-positive mothers to prevent fetal infection. ➤ Hepatitis C therapy should not be offered to pregnant women to either treat HCV or decrease the risk for vertical transmission.
Other Chronic liver diseases	<ul style="list-style-type: none"> ➤ Pregnant women with AIH should be continued on their treatment with corticosteroids and/or AZA. ➤ Pregnant women with primary biliary cirrhosis should be continued on their treatment with UDCA.

Continued.

Diseases and disorders	Statements
	<ul style="list-style-type: none"> ➤ Pregnant women with Wilson's disease should be continued, with dose reduction if possible, on their treatment with penicillamine, trientine or zinc. ➤ Pregnant women with suspected portal hypertension should undergo screening with Upper G.I Endoscopy for esophageal varices in the second trimester; those found to have large esophageal varices should be treated with beta-blockers and/or band ligation. ➤ Pregnant women with a history of liver transplantation should continue their immunosuppression except for mycophenolic acid.

ROLE OF LIVER TRANSPLANTATION

Orthotopic liver transplantation (OLT) can be a life-saving procedure for the mother and fetus in cases of acute liver failure in pregnancy. The indications for OLT in HELLP syndrome are persistent bleeding despite surgical intervention, extensive liver necrosis or liver failure.³² Liver transplantation for AFLP is sporadic and outcomes appear largely favorable.⁴⁵ Successful outcome of combined OLT and caesarean section at 32 weeks gestation for Budd Chiari Syndrome has been reported.⁴⁶ The timing of delivery with respect to the time of OLT, in cases in which delivery will not likely contribute to improving the patient's condition is controversial.

Common side effects during pregnancy after liver transplantation are pre-eclampsia, hypertension and gestational diabetes mellitus. Other complications which may occur are graft rejection, impaired maternal renal function, increased rates of caesarean and preterm deliveries along with fetal growth restriction, fetal malformations and death, and complications in the newborn.^{47,48} Although graft rejections are a common occurrence, there has hardly been any association found between liver transplantation and increased rates of maternal mortality.^{49,50}

CONCLUSION

Fulminant hepatic failure is one of the most dreaded complications in pregnancy. Mandatory screening for etiology, early diagnosis and initiation of supportive management as soon as possible are absolutely essential to ensure better maternal and fetal outcomes. Effective communication with the Obstetrician regarding timely delivery/termination of pregnancy ensures a favorable prognosis in the majority of cases. Liver transplant is a definitive life-saving option for cases of severe fulminant hepatic failure in pregnancy, although extremely limited availability of transplant centers and delay in transfer or transport to these centers is one of the major causes of high mortality in such cases. Management has to be suited to each patient individually, keeping in mind the well-being of both the mother and the child.

Funding: No funding sources

Conflict of interest: None declared

Ethical approval: Not required

REFERENCES

- Bernau J, Rueff B, Benhamou J. Fulminant and Sub fulminant Liver Failure: Definitions and Causes. *Semin Liver Dis.* 1986;6(2):97-106.
- Trey C, Davidson CS. The management of fulminant hepatic failure. *Prog Liver Dis.* 1970;3:282-98.
- Pandey C, Pandey V, Tandon M, Karna S. Acute liver failure in pregnancy: Challenges and management. *Indian J Anaesth.* 2015;59(3):144.
- Hay J. Liver disease in pregnancy. *Hepatology.* 2008;47(3):1067-76.
- Fleming WJ. Liver Disease in Pregnancy. *Current Clin Med.* 2010;558-63.
- Joshi D, James A, Quaglia A, Westbrook RH, Heneghan MA. Liver disease in pregnancy. *Lancet.* 2010;375(9714):594-605.
- Lana K, Wagner MD. Diagnosis and Management of Preeclampsia. *First Choice Community Healthcare, Albuquerque, New Mexico. Am Fam Physician.* 2004;70(12):2317-24.
- Sibai BM. The HELLP syndrome (hemolysis, elevated liver enzymes, and low platelets): much ado about nothing?. *Am J Obstet Gynecol.* 1990;162(2):311-6.
- ACOG Committee on Practice Bulletins--Obstetrics. ACOG practice bulletin. Diagnosis and management of preeclampsia and eclampsia. Number 33, January 2002. *Obstet Gynecol.* 2002;99(1):159-67.
- MacKay AP, Berg CJ, Atrash HK. Pregnancy-related mortality from preeclampsia and eclampsia. *Obstet Gynecol.* 2001;97(4):533-8.
- Sibai BM. Diagnosis, controversies, and management of the syndrome of hemolysis, elevated liver enzymes, and low platelet count. *Obstet Gynecol.* 2004;103(5):981-91.
- Reyes H. Acute fatty liver of pregnancy. *Clin Liver Dis.* 1999;3:69-81.
- Borwning MF, Levy HL, Wilkins HL, Larson C, Shih VE. Fetal fatty acid oxidation defects and maternal liver disease in pregnancy. *Obstet Gynecol.* 2006;107:115-20.
- Martin S. Fatty Liver of Pregnancy Clinical advisor. *Cancer Therapy Advisor.* 2017.
- Tran TT, Ahn J, Reau NS. ACG Clinical Guideline: Liver Disease and Pregnancy. *Am J Gastroenterol.* 2016;111(2):176-94.

16. Ablett J. Acute fatty liver of pregnancy guideline (GL780). *Maternity Guidelines- Acute Fatty Liver of Pregnancy (GL780)*. 2016;1-5.
17. Brooks RR, Feller CM, Maye JP. Acute fatty liver of pregnancy: A case report. *J Am Assoc Nurse Anesth.* 2002;70(3):215-7.
18. WHO. Hepatitis E, 2018. Available at: <https://www.who.int/newsroom/factsheets/detail/hepatitis-e>. Accessed on 10 May 2021.
19. Singh S, Mohanty A, Joshi YK, Dwivedi SN, Deka D. Outcome of hepatitis E virus infection in Indian pregnant women admitted to a tertiary care hospital. *Indian J Med Res.* 2001;113:35-9.
20. Jilani N, Das BC, Husain SA, Baweja UK, Chattopadhyaya D, Gupta RK, et al. Hepatitis E virus infection and fulminant hepatic failure during pregnancy. *J Gastroenterol Hepatol.* 2007;22:676-82.
21. Remy P, Widjaja D, Anand B. *Hepatitis E Treatment & Management: Medical Management, Diet and Activity.* Medspace. 2019.
22. Kamar N, Bendall RP, Peron JM, Cintas P, Prudhomme L, Mansuy JM, et al. Hepatitis E virus and neurologic disorders. *Emerg Infect Dis.* 2011;17(2):173-9.
23. Norvell JP, Blei AT, Jovanovic BD, Levitsky J. Herpes simplex virus hepatitis: An analysis of the published literature and institutional cases. *Liver Transpl.* 2007;13:1428-34.
24. Darwish MS, Valla DC, Groen PC, Zeitoun G, Hopmans JA, Haagsma EB, et al. Determinants of survival and the effect of portosystemic shunting in patients with Budd-Chiari syndrome. *Hepatology.* 2004;39:500-8.
25. Bogin V, Marcos A, Shaw-Stiffel T. Budd-Chiari syndrome: in evolution. *Eur J Gastroenterol Hepatol.* 2005;17(1):33-5.
26. Hennes EM, Zeniya M, Czaja AJ, Pares A, Dalekos GN, Krawitt EL, et al. Simplified criteria for the diagnosis of autoimmune hepatitis. *Hepatology.* 2008;48:169-76.
27. Terrabuio DR, Abrantes LCP, Carrilho FJ, Cancado EL. Follow-up of pregnant women with autoimmune hepatitis: the disease behavior along with maternal and fetal outcomes. *J Clin Gastroenterol.* 2009;43:350-6.
28. Westbrook RH, Yeoman AD, Kriese S, Heneghan MA. Outcomes of pregnancy in women with autoimmune hepatitis. *J Autoimmun.* 2012;38:239-44.
29. Peters MG. Management of Autoimmune Hepatitis in Pregnant Women. *Gastroenterol hepatol.* 2017;13(8):504-6.
30. Patra S. Management of Fulminant Hepatic Failure due to Hepatitis E in Pregnancy. *AOGD Bulletin.* 2018;18(3).
31. Report of the National High Blood Pressure Education Program Working Group on High Blood Pressure in Pregnancy. *Am J Obstet Gynecol.* 2000;183(1):1-22.
32. Altman D, Carroli G, Duley L, Farrell B, Moodley J, Neilson J, Smith D, et al. Do women with pre-eclampsia, and their babies, benefit from magnesium sulphate? The Magpie Trial: a randomised placebo-controlled trial. *Lancet.* 2002;359(9321):1877-90.
33. Shames BD, Fernandez LA, Sollinger HW, Chin LT, Alessandro AM, Knechtle SJ, et al. Liver transplantation for HELLP syndrome. *Liver Transpl.* 2005;11:224-8.
34. Ockner SA, Brunt EM, Cohn SM, Krul ES, Hanto DW, Peters MG. Fulminant hepatic failure caused by acute fatty liver of pregnancy treated by orthotopic liver transplantation. *Hepatology.* 1990;11:59-64.
35. Naeyer S, Ysebaert D, Utterbeeck M, Francque S, Palit G, Jacquemyn Y. Acute fatty liver of pregnancy and molecular absorbent recirculating system (MARS)-therapy: A case report. *J Matern Fetal Neonatal Med.* 2008;21:587-9.
36. Kamar N, Bendall R, Legrand AF, Xia NS, Ijaz S, Izopet J, et al. Hepatitis E. *Lancet.* 2012;379(9835):2477-88.
37. Shrestha MP, Scott RM, Joshi DM, Mammen MP, Thapa GB, Thapa N, et al. Safety and efficacy of a recombinant hepatitis E vaccine. *N Engl J Med.* 2007;356(9):895-903.
38. Zhu FC, Zhang J, Zhang XF, Zhou C, Wang ZZ, Huang SJ, Wang H, et al. Efficacy and safety of a recombinant hepatitis E vaccine in healthy adults: a large-scale, randomised, double-blind placebo-controlled, phase 3 trial. *Lancet.* 2010;376(9744):895-902.
39. Gerolami R, Borentain P, Raissouni F, Motte A, Solas C, Colson P. Treatment of severe acute hepatitis E by ribavirin. *J Clin Virol.* 2011;52(1):60-2.
40. Keefe EB, Dieterich DT, Han SHB, Jacobson IM, Martin P, Schiff ER, et al. A treatment algorithm for the management of chronic hepatitis B virus infection in the United States: an update. *Clin Gastroenterol Hepatol.* 2006;4:936-62.
41. Terrault NA, Bzowej NH, Chang KM, Hwang JP, Jonas MM, Murad MH. AASLD guidelines for treatment of chronic hepatitis B. *Hepatology.* 2016;63:261-83.
42. Banait VS, Sandur V, Parikh F, Muruges M, Ranka P, Ramesh VS, et al. Outcome of acute liver failure due to acute hepatitis E in pregnant women. *Indian J Gastroenterol.* 2007;26:6-10.
43. Scheinberg IH, Jaffe ME, Sternlieb I. The use of trientine in preventing the effects of interrupting penicillamine therapy in Wilson's disease. *N Engl J Med.* 1987;317:209-13.
44. Mahadevan U. American gastroenterological association institute technical review on the use of gastrointestinal medications in pregnancy. *Gastroenterol.* 2006;131:283-11.
45. Grady JG, Alexander GJ, Hayllar KM, Williams R. Early indicators of prognosis in fulminant hepatic failure. *Gastroenterol.* 1989;97:439-45.

46. Valentine JM, Parkin G, Pollard SG, Bellamy MC. Combined orthotopic liver transplantation and caesarean section for the Budd-Chiari syndrome. *Br J Anaesth.* 1995; 75:105-8.
47. Anders M, Quinonez E, Goldaracena N, Osatnik J, Fernandez JL, Viola L, et al. Liver transplantation during pregnancy in a patient with acute liver failure. *Acta Gastroenterol Latinoam.* 2010;40(3):268-70.
48. Kimmich N, Dutkowski P, Krahenmann F, Mullhaupt B, Zimmermann R, Ochslein KN. Liver Transplantation during Pregnancy for Acute Liver Failure due to HBV Infection: A Case Report. *Case Rep Obstet Gynecol.* 2013; 356560.
49. Parhar KS, Gibson PS, Coffin CS. Pregnancy following liver transplantation: review of outcomes and recommendations for management. *Can J Gastroenterol.* 2012;26(9):621-6.
50. Coscia LA, Constantinescu S, Moritz MJ, Frank A, Ramirez CB, Maley WL, et al. Report from the National Transplantation Pregnancy Registry (NTPR): outcomes of pregnancy after transplantation. *Clin Transpl.* 2009:103-22.

Cite this article as: Parasher A, Mohan V. Fulminant hepatic failure in pregnancy: challenges, management strategies, prognosis and outcomes. *Int J Adv Med* 2021;8:1239-52.