

Case Report

Pontine hemorrhage presenting as Foville's syndrome

Mary Stephen^{1*}, Jayasri¹, Harigaravelu P. J.², Baranitharan³

¹Department of Ophthalmology, JIPMER, Puducherry, India

²Department of Surgery, IGGGH and RI, Puducherry, India

³Department of Radio-diagnosis, Osmania Hospital, Hyderabad, Telangana, India

Received: 26 May 2021

Accepted: 29 June 2021

*Correspondence:

Dr. Mary Stephen,

E-mail: stephen6752@gmail.com

Copyright: © the author(s), publisher and licensee Medip Academy. This is an open-access article distributed under the terms of the Creative Commons Attribution Non-Commercial License, which permits unrestricted non-commercial use, distribution, and reproduction in any medium, provided the original work is properly cited.

ABSTRACT

Foville's syndrome, also known as inferior medial pontine syndrome is one of the rare brainstem stroke syndromes with only few cases reported worldwide occurring due to involvement of the infero-medial aspect of pons. Condition is characterised by various cluster of neurological features as a result of defect in multiple vital areas like cortico spinal tract, medial lemniscus, middle cerebral peduncle, facial nerve and abducens nerve involvement. We reported one such rare case of a patient with no known systemic co-morbidity, who presented with sudden onset diplopia, lagophthalmos and contralateral weakness of limbs. On evaluation with computed tomography imaging, hemorrhage at the level of inferior pons was found. Patient subsequently treated and commenced on physiotherapy for rehabilitation.

Keywords: Foville's syndrome, Pontine hemorrhage, Diplopia, Lagophthalmos, Hemiparesis

INTRODUCTION

Foville's syndrome is one of the rare pontine stroke syndromes which was first described in 1858 by anatomist and psychiatrist Achille Louis Francois Foville.¹ The presentation is due to pontine infarction, however hemorrhage, granulomas and tumors have been reported. Isolated pontine stroke is only 3% and predominantly due to atheromatous small vessel involvement and also affection of basilar artery.² Important nerve nuclei in the region of the pons include the trigeminal nerve sensory and motor nuclei, abducens nucleus, facial nerve nucleus and vestibulocochlear nuclei. Structures affected that are critical to horizontal eye movement and gaze in this region are the paramedian pontine reticular formation (PPRF) and medial longitudinal fasciculus. Finally, a series of tracts, namely, the medial lemniscus, spinothalamic tract and descending pyramidal tracts, traverse this region. Infero medial aspect of pons is affected in Foville's syndrome and typically characterised by contralateral hemiparesis,

ipsilateral sixth and seventh nerve palsy.³ We hereby reported a 28 year old male without any systemic disease presented with features of sixth and seventh nerve involvement and contralateral weakness of limbs. Imaging showed inferior pontine hemorrhage and detailed workup carried out to identify the etiology for the pontine hemorrhage and was inconclusive. Patient managed promptly and started on physiotherapy; patient discharged eventually with improvement in motor function.

CASE REPORT

A young man (28 years) presented to the emergency room with complaints of sudden onset binocular diplopia and inability to close the right eye along with difficulty in walking and lifting left hand for one day. No known systemic co-morbidity for the patient. On further examination, visual acuity of the patient was 6/6 in both eyes with right eye in 30 degrees esotropia by Hirschberg's test and restriction of abduction in right eye noted without

any other abnormality in extraocular movements (Figure 1).

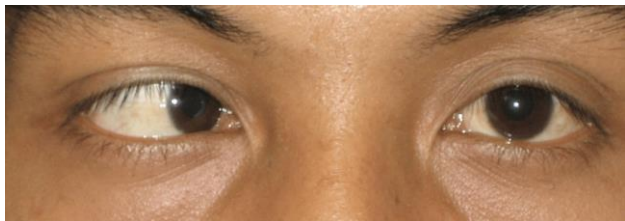

Figure 1: Right eye esotropia of the patient.

Lagophthalmos of right eye present with inadequate Bell's phenomenon and inferior corneal exposure noted with deviation of angle of mouth to left side, dropping of saliva and watering from right eye. Loss of forehead wrinkles, weakness of buccinator muscle also has been found on examination in right side. Other cranial nerves examination was normal. Motor system examination of the patient showed power of 1/5 in left upper and lower limbs. Patient also found to have left side hemisensory loss (fine touch, proprioception) on examination. Diplopia charting carried out for the patient showed uncrossed diplopia with maximum separation towards the right gaze suggestive of right lateral rectus muscle palsy.

Body mass index of the patient was 30. Computed tomography imaging of brain revealed hemorrhage at the level of infero-medial aspect of pons (Figure 2).

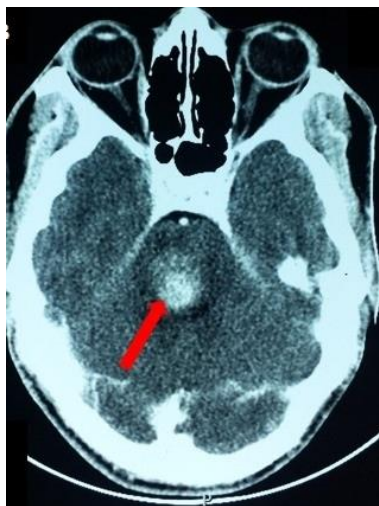


Figure 2: Axial section of computed tomography imaging of brain showing hemorrhage at the level of right infero-medial aspect of pons marked by arrow.

Serial imaging carried out for any worsening and no change in the size of hemorrhage noted. Patient managed conservatively with anxiolytics and strict monitoring of vitals and worsening of general condition. Detailed work-up carried out for the patient to identify the cause of hemorrhage and remind inconclusive. Fresnel prism given to avoid diplopia and taping of right eye done with

lubricant eye drops till lid closure of right eye was adequate. Physiotherapy had been commenced for left hemiparesis and right facial palsy, patient showed signs of improvement and eventually discharged and kept on close follow up.

DISCUSSION

A stroke syndrome is a set of symptoms that helps to identify which part of brain is affected, the earliest clinical syndromes were described in 19th century. Foville syndrome is one of the brainstem stroke syndromes occurring when there is infarction of the medial inferior aspect of the pons due to occlusion of the paramedian branches of the basilar artery.⁴ Various other less common etiologies include tumors, hemorrhage, tuberculoma, granuloma.⁵ Syndrome is characterised by varied clinical features due to involvement of structures like corticospinal tract-contralateral hemiparesis/hemiplegia, medial lemniscus-contralateral loss of proprioception and vibration, middle cerebral peduncle-ipsilateral ataxia, facial nerve nucleus-ipsilateral lower motor neuron type of facial palsy affecting upper and lower half of face, sixth nerve nucleus-restriction of abduction and uncrossed diplopia. Horner syndrome (oculo sympathetic palsy) can also be a manifestation.⁶

In our case report a healthy young male presented with features of sixth and seventh cranial nerve palsy and contralateral weakness of limbs and imaging showed evidence of hemorrhage at the level of inferior pons. Similar case has been reported by Cheng et al and found pontine infarct rather than hemorrhage as the etiology in a young male.⁷

The patient in our case report has been managed conservatively with serial imaging to look for worsening of hemorrhage and with strict monitoring for any clinical signs of worsening. Patient was given anxiolytics and no worsening noted on monitoring. Symptomatic management in the form of Fresnel prism for diplopia, taping of upper eyelid and lubricant eyedrops given. Physiotherapy has been commenced for the patient for limb weakness and facial palsy. On follow up, lid closure of patient improved with improvement in limb muscle power from 1/5 to 4/5 over a period of 40 days. In general pontine hemorrhage is associated with high mortality rate and our patient did not show any further worsening and no new hemorrhages on serial monitoring with magnetic resonance imaging carried out at 3 month and 6 month from discharge.

CONCLUSION

Foville's syndrome which is inferior pontine syndrome is rare and can occur due to spontaneous hemorrhage in pontine region. Conservative management is commonly advocated with strict monitoring to look for signs of worsening are needed. To our knowledge Foville's syndrome as such is rare and due to spontaneous pontine

hemorrhage in healthy young patient is very rare and requires prompt identification and management.

ACKNOWLEDGEMENTS

The authors wish to acknowledge the patient for complete co-operation.

Funding: No funding sources

Conflict of interest: None declared

Ethical approval: Not required

REFERENCES

1. Brogna C, Fiengo L, Türe U. Achille Louis Foville's atlas of brain anatomy and the Defoville syndrome. *Neurosurgery*. 2012;70(5):1265-73.
2. Silverman IE, Liu GT, Volpe NJ, Galetta SL. The crossed paralyses. The original brain-stem syndromes of Millard-Gubler, Foville, Weber and Raymond-Cestan. *Arch Neurol*. 1995;52(6):635-8.
3. Raggio CC, Dasgupta A. Three cases of Spontaneous vertebral artery dissection (SVAD), resulting in two cases of Wallenberg syndrome and one case of

- Foville syndrome in young, healthy men. *BMJ Case Rep*. 2014;2014:2014203945.
4. Khazaal O, Marquez DL, Naqvi IA. Foville Syndrome. Treasure Island (FL): StatPearls Publishing; 2021.
5. Bedi HK, Devpura JC, Bomb BS. Clinical tuberculoma of pons presenting as Foville's syndrome. *J Indian Med Assoc*. 1973;61(4):184-5.
6. Radiopaedia.org. fact sheet: Inferior medial pontine syndrome, 2021. Available at: <https://radiopaedia.org/articles/inferior-medial-pontine-syndrome>. Accessed on 12 May 2021.
7. Cheng HC, Yen MY, Wang AG. Foville's syndrome with ipsilateral internuclear ophthalmoplegia due to spontaneous pontine hemorrhage. *Taiwan J Ophthalmol*. 2013;3(2):75-7.

Cite this article as: Stephen M, Jayasri, Harigaravelu PJ, Baranitharan. Pontine hemorrhage presenting as Foville's syndrome. *Int J Adv Med* 2021;8:1226-8.