

Case Report

A case of Osler-Weber-Rendu syndrome associated with portal hypertension

G. S. Sanjay Surya*, Priya Venugopalan, Gowtham Hanumanram, Deepthi Mithra, Kannan Rajendran, Gowrishankar A.

Department of General Medicine, Saveetha Medical College and Hospital, Tamil Nadu, India

Received: 08 May 2022

Revised: 30 May 2022

Accepted: 04 June 2022

*Correspondence:

Dr. G. S. Sanjay Surya,

E-mail: gs.sanjaysurya@yahoo.in

Copyright: © the author(s), publisher and licensee Medip Academy. This is an open-access article distributed under the terms of the Creative Commons Attribution Non-Commercial License, which permits unrestricted non-commercial use, distribution, and reproduction in any medium, provided the original work is properly cited.

ABSTRACT

Osler-Weber-Rendu syndrome is a rare autosomal dominant vascular disorder, characterised by multiple telangiectases of the skin and mucous membranes with recurrent nasal and gastrointestinal bleedings and arteriovenous malformations of various organ systems. It is also called as hereditary hemorrhagic telangiectasia (HHT). The occurrence of telangiectases in the stomach and small bowel can result in chronic bleeding and anaemia. We report a rare case of 39 year old female with Osler Weber Rendu syndrome associated with portal hypertension. She had recurrent nasal and gastrointestinal bleeding, and presented with complaints of progressive dyspnea NYHA class III. On further evaluation she was found to have portal hypertension, which is a rare association.

Keywords: Osler-Weber-Rendu syndrome, Portal hypertension, Iron deficiency anaemia

INTRODUCTION

Osler Weber Rendu syndrome (OWRS) or hereditary hemorrhagic telangiectasia (HHT) is a rare autosomal dominant disorder with incidence of 1–2 cases per 100,000 populations.¹ Pathologic dilation of post-capillary venules leads to diffuse distribution of arteriovenous malformations in the skin, mucosal surfaces increase as the age increases. Iron deficiency anemia from spontaneous recurrent epistaxis and gastrointestinal bleeding is very common and it was noticed in our patient.^{2,3}

96% of patients with OWRS will have epistaxis, which is the most common and foremost clinical manifestation. It is followed by cutaneous telangiectasias (75%).^{4,5} The vascular malformations may involve lungs, liver, kidney, and brain may also seen. Portal venous hypertension is reported in less than 10% of subjects with OWRS and this account for increased mortality rate.⁶ In this study, we

present a rare case of Osler weber syndrome manifesting with indirect signs of portal hypertension.

CASE REPORT

A 39 year old female presented to outpatient department with complaints of progressive dyspnea NYHA Class III. She had the history of dyspnea for the past one month. Patient also had history of palpitation, abdominal distension, and lower limb swelling for the past one month. She gave history of epistaxis since childhood. There was no history of any melena or any other bleeding manifestations. History of multiple blood transfusions (3 times) done in past two years. Patient's younger sister also had similar complaints of recurrent epistaxis. On general examination pallor and pitting pedal edema was present. Multiple telangiectasia spots were present in the palms (Figure 1) and tongue (Figure 2) on local examination. Abdominal examination revealed distended abdomen and

hepatosplenomegaly. Other systemic examinations were normal.

Laboratory investigations revealed severe anemia with HB 2.4 gm/dl. All the parameters related to RBC were decreased with RBC count- 1.7 million cells/cumm, PCV- 10.9%, MCV- 64.1 fl, MCH- 14.1 pg and MCHC- 22 g/dl. Platelet count was 5.28 lakhs/cumm. Peripheral smear study showed severe microcytic hypochromic anemia and thrombocytosis.

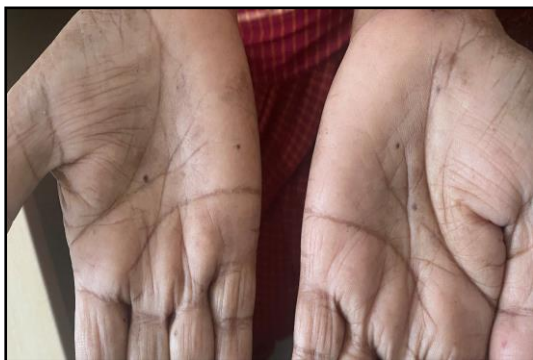

Figure 1: Multiple telangiectatic spots noted over the palm aspect of hands.



Figure 2: Telangiectatic spot noted in the tongue.

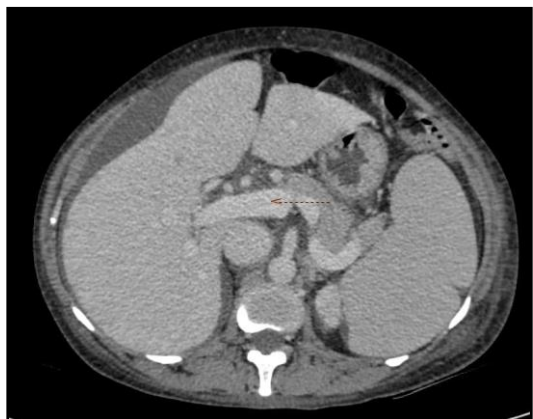


Figure 3: Dilated portal vein- 14 mm, also note the hepatomegaly.

It was noted that Mentzer index was 37, serum ferritin 23.2 ng/ml (normal serum ferritin: 10-120 ng/dl), serum iron- 27 (normal serum iron: 65-176 µg/dl), and transferrin saturation was 9.89% (normal transferrin saturation: 15-50%). Coagulation profile (bleeding time- 4 min, clotting time- 104 sec), PT/ INR/ aPTT/renal function test, liver function tests and urine analysis were all within normal limits.

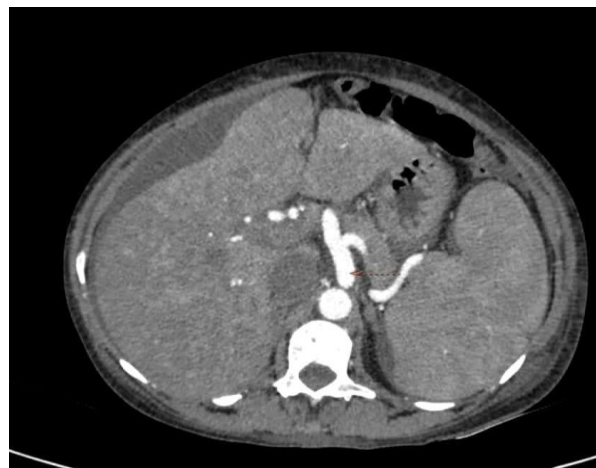

Figure 4: Coeliac artery is dilated.

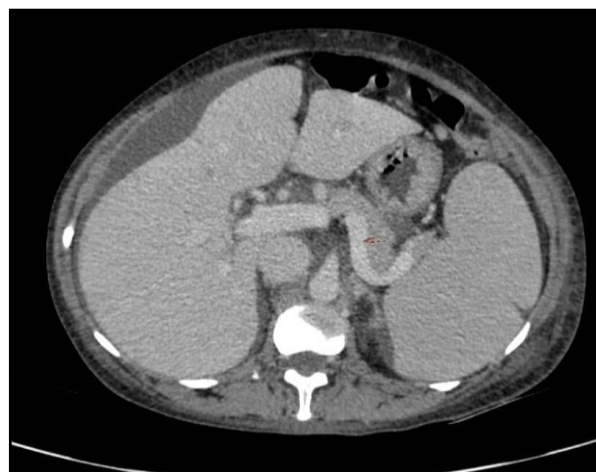


Figure 5: Dilated splenic vein- 9.7 mm along with splenomegaly.

CECT done revealed hepatomegaly with 22.8 cm increased in size, normal in attenuation and outline was noted. Hepatic veins were normal. Portal vein is 14 mm (dilated) (Figure 3). Celiac artery and its branches appears dilated (Figure 3) common hepatic artery was 8 mm in diameter. Splenomegaly (13.8×7.9 cm size) with splenic notch noted with normal attenuation and outline. Splenic vein was 9.7 mm dilated (Figure 4). There was no evidence of collaterals and focal lesions. No AV malformation was noticed in CECT brain and CECT thorax. Multiple hemorrhagic spots in the body of stomach were noted in upper GI endoscopy. Echo Heart revealed LV diastolic dysfunction with ejection fraction of 45%.

Patient received 3 packed red blood cell (PRBC) transfusions and iron replacement was done with iron sucrose injection and oral supplementation. At the time of discharge patient's hemoglobin level was improved from 2.4 to 8.1 g/dl.

DISCUSSION

Iron deficiency anaemia is one of the most frequent complications of OWRs secondary to blood loss. Pahl et al reported that around 11% of the individuals had severe anemia and 40% of them had epistaxis and gastrointestinal bleeding.⁷ In our patient the episodes of recurrent epistaxis and chronic GI bleeding were the cause of life-threatening anaemia. We also noticed the indirect signs of portal hypertension, including hepatomegaly, splenomegaly and increased portal vein diameter.⁸ The prevalence of hepatic involvement in HHT had been estimated at 8-31% in retrospective studies and only less than 10% of them are symptomatic.^{9,10} Splenic involvement is considered a rare manifestation, with only a few case reports describing splenic involvement in patients with HHT.^{11,12} Several case reports of Osler Weber syndrome have mentioned about the hepatic involvement ranging from 74-79% but the isolated involvement of liver is very rare. It is significantly predominant in females (male and female ratio 1:2 to 1:4.5 respectively). Usually arterioportal shunts are rare and it is associated with portal hypertension.^{13,14} In our subject we have noticed both splenomegaly and hepatomegaly which are rare manifestation.

Permanent, effective cure for HHT is not available. We have treated our patients with 3 packed red blood cell transfusions and iron sucrose injection. At the time of discharge patient's haemoglobin level improved. Past studies have shown that thalidomide seems to be the best promising treatment in HHT. It modulates the activation of mural cells and enhances both their proliferation and it can make HHT vessels more firm and less prone to breaking.¹⁵ Hormone treatment (oestrogen, progestagen) has been successfully used in controlling epistaxis and gastrointestinal bleeding in patients with HHT, with few side effects.¹⁶ Since majority of hepatic involvement is asymptomatic, pre-symptomatic treatment is not available. Hepatic involvement is usually associated with substantial impact on quality of life and significant mortality. The prognosis for HHT varies and it depends on the severity of symptoms. Life expectancy in patients with HHT is lower than the general population. Sepsis and cardiac failure are the main causes of death.¹⁷

CONCLUSION

Osler-Weber-Rendu syndrome presenting with asymptomatic portal hypertension and splenomegaly is a very rare phenomenon. Appropriate diagnostic measures and proper medical history should be taken. Care should be taken in the early identification of symptoms and treating it.

Funding: No funding sources

Conflict of interest: None declared

Ethical approval: Not required

REFERENCES

1. Khoja AM, Jalan RK, Jain DL, Kajale OV. OslerWeberRendu disease: A rare cause of recurrent hemoptysis. *Lung India.* 2016;33:3136.
2. Sautter NB, Smith TL. Treatment of Hereditary Hemorrhagic TelangiectasiaRelated Epistaxis. *Otolaryngol Clin N Am.* 2016;49(3):639–654. Lee HE, Sagong C, Yeo KY, Ko JY, Kim JS, Yu HJ. A case of hereditary hemorrhagic telangiectasia. *Ann Dermatol.* 2009;21(2):206-8.
3. Guttmacher AE, Marchuk DA, White RL. Hereditary Haemorrhagic Telangiectasia. *New England J Med.* 1995;333:918-24.
4. Haitjema T, Westermann CJJ, Overtom TTC, Timmer R, Disch F, Mauser H et al. Hereditary Hemorrhagic Telangiectasia (Osler-weber-Rendu Disease). *Arch Intern Med.* 1996;56(8):714-9.
5. Singh A, Suri V, Jain S, Varma S. Rare manifestations in a case of Osler-Weber-Rendu disease. *BMJ Case Rep.* 2015;2015:bcr2014207852.
6. Pahl K, Choudhury A, Kasthuri RS. Causes and severity of anemia in hereditary hemorrhagic telangiectasia. *Blood.* 2016;128:3776.
7. Garcia-Tsao G. Liver involvement in hereditary hemorrhagic telangiectasia (HHT). *Journal of Hepatology.* 2007;46(3):499-507.
8. Jackson SB, Villano NP, Benhammou JN, Lewis M, Pisegna JR, Padua D. Gastrointestinal Manifestations of Hereditary Hemorrhagic Telangiectasia (HHT): A Systematic Review of the Literature. *Dig Dis Sci.* 2017;62(10):2623-30.
9. Bernard G, Mion F, Henry L, Plauchu H, Paliard P. Hepatic involvement in hereditary hemorrhagic telangiectasia: Clinical, radiological and hemodynamic studies of 11 cases. *Gastroenterology.* 1993;105:482-7.
10. Willis J, Mayo MJ, Rogers TE, Chen W. Hereditary haemorrhagic telangiectasia involving the bone marrow and liver. *British Journal of Haematology.* 2009;145(2):150.
11. Folz BJ, Wollstein AC, Alfke H. The value of screening for multiple arterio-venous malformations in hereditary hemorrhagic telangiectasia: a diagnostic study. *European Archives of Oto-Rhino-Laryngology.* 2004 ;261(9):509-16.
12. Macaluso FS, Maida M, Alessi N, Cabibbo G, Cabibi D. Primary biliary cirrhosis and hereditary hemorrhagic telangiectasia: When two rare diseases coexist. *World J Hepatol.* 2013;5(5):288-91.
13. Nishioka Y, Akamatsu N, Sugawara Y, Kaneko J, Arita J, Sakamoto Y et al. Hereditary hemorrhagic telangiectasia with hepatic vascular malformations. *Case Reports in Medicine.* 2015; 2015.
14. Hosman A, Westermann CJ, Snijder R. Follow-up of thalidomide treatment in patients with hereditary

haemorrhagic telangiectasia. *Rhinology.* 2015;53:340-4.

15. Van Cutsem E, Rutgeerts P, Vantrappen G. Treatment of bleeding gastrointestinal vascular malformations with oestrogenprogesterone. *Lancet.* 1990;335(8695):953-5.
16. Droege F, Thangavelu K, Stuck BA, Stang A, Lang S, Geithoff U. Life expectancy and comorbidities in

patients with hereditary hemorrhagic telangiectasia. *Vasc Med.* 2018;23:377-83.

Cite this article as: Sanjay SGS, Venugopalan P, Hanumanram G, Mithra D, Rajendran K, Gowrishankar A. A case of Osler-Weber-Rendu syndrome associated with portal hypertension. *Int J Adv Med* 2022;9:852-5.