

## Case Report

# A rare case of rapid development of bullous lung

Rishab Rampradeep\*, V. Gangadharan, Prasanth Gururaj

Department of Respiratory Medicine, Saveetha Medical College, Chennai, Tamil Nadu, India

**Received:** 18 June 2022

**Revised:** 07 July 2022

**Accepted:** 08 July 2022

### \*Correspondence:

Dr. Rishab Rampradeep,

E-mail: rishab.rp@gmail.com

**Copyright:** © the author(s), publisher and licensee Medip Academy. This is an open-access article distributed under the terms of the Creative Commons Attribution Non-Commercial License, which permits unrestricted non-commercial use, distribution, and reproduction in any medium, provided the original work is properly cited.

### ABSTRACT

Tuberculosis, although an ancient disease, affecting humans for millennia; continues to present in atypical ways. Whilst the development of bullous lung disease in patients suffering from Pulmonary Tuberculosis, has been reported, it remains an extremely rare phenomenon. The underlying mechanisms remain unknown, and potential causes have been hypothesized, including the role of Isoniazid as part of antitubercular therapy. We reported one such case of a rapid development of bullous lung as a complication of Pulmonary Tuberculosis.

**Keywords:** Bullous lung disease, Vanishing lung syndrome, Pulmonary tuberculosis, Post tuberculosis sequelae

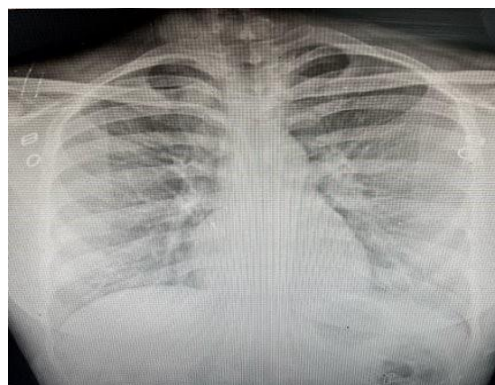
## INTRODUCTION

Bullae may be defined as air spaces in the lungs, measuring at least more than 1 cm in diameter when distended; while giant bullae, occupy at least a third of the entire hemithorax.<sup>1</sup> Bullae may be idiopathic or associated more commonly with chronic obstructive pulmonary disease or even pulmonary infections. Risk factors for the development of bullous lung disease, include smoking, emphysema, use of cocaine or marijuana, sarcoidosis and genetic factors such as alpha-1 antitrypsin deficiency, Marfan's syndrome and Ehlers Danlos syndrome.<sup>2,3</sup> While vanishing lung syndrome and bullous lung disease have been described in patients suffering from Tuberculosis, they're exceedingly infrequent in medical literature and bullous lung disease as a complication of Tuberculosis has seldom been reported.<sup>4</sup> We reported one such case of a rapid development of bullous lung in a 23-year-old female patient suffering from Pulmonary Tuberculosis with no other risk factors.

## CASE REPORT

A 23-year-old female, working as a staff nurse in a tertiary care hospital, a known case of microbiologically

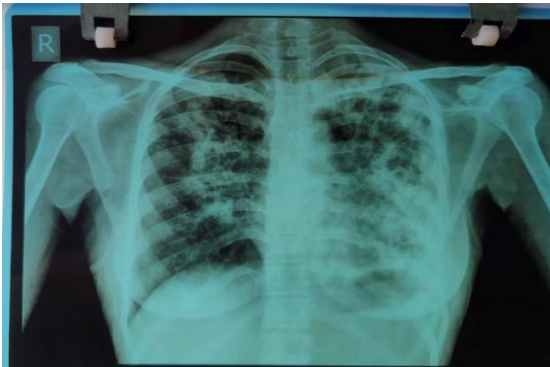
confirmed pulmonary tuberculosis on oral anti-tubercular treatment (ATT) FDC since 16 May 2021, with no comorbidities, or significant past or personal history (Figure 1), presented to the outpatient clinic, of the department of respiratory medicine with complaints of sudden onset worsening of shortness of breath since the previous night on 30 November 2021.



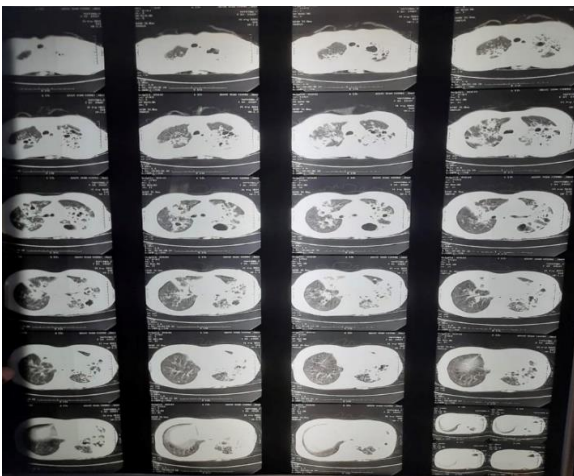
**Figure 1: Normal chest X-ray.**

She was apparently asymptomatic since the second week of March, following which she complained of cough with

expectoration, low grade fever, shortness of breath on exertion and vague unquantified loss of weight, associated with a loss of appetite, lasting for 2 weeks. Patient was treated symptomatically by a private practitioner for a week following which she was referred to a government hospital where a chest X-ray and CT thorax (Figure 2 and 3) was taken which showed consolidation with cavitary changes involving bilateral lung fields with an upper lobe predominance; consistent with active Pulmonary Tuberculosis.



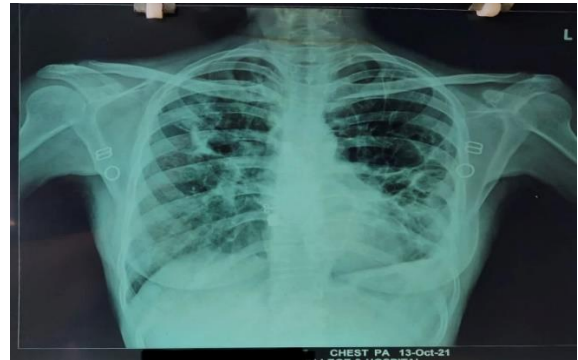**Figures 2: X-ray of thorax showing consolidation with cavitary changes involving bilateral lung fields with an upper lobe predominance.**



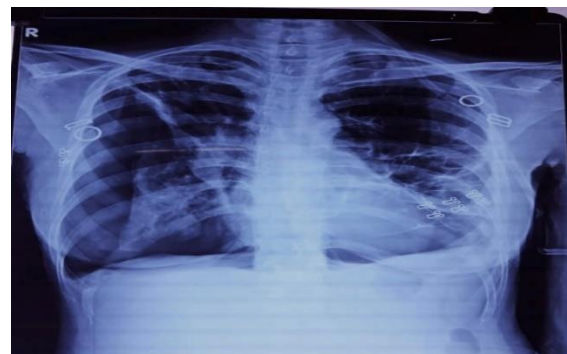**Figures 3: CT of thorax showing consolidation with cavitary changes involving bilateral lung fields with an upper lobe predominance.**

Sputum sent for AFB smear and CBNAAT were found to be positive, with rifampicin resistance not being detected. She was consequently started on oral ATT HRZE FDC as per weight band on 16 May 2021. Patient was compliant and following an initial period of clinical improvement and a negative sputum report after 2 months; patient was switched to continuation phase. In October 2021, patient was reviewed with a repeat chest X-ray (Figure 4) and was asked to resume her duty in the hospital. At presentation, patient maintained a saturation of 96% in room air, with stable vital parameters. Examination revealed reduced breath sounds bilaterally, predominantly over the right

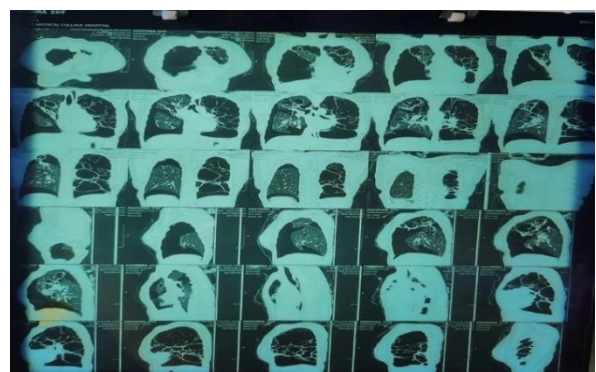
hemithorax; associated with a decreased vocal fremitus and a hyper resonant note on percussion. Chest X-ray and CT thorax was done (Figure 5 and 6) which showed giant bullae almost replacing the entire left lung and multiple bullae of varying sizes in the right upper lobe with right moderate pneumothorax and multiple calcified mediastinal lymph nodes.



**Figure 4: X-ray showing progression to bullous disease.**



**Figures 5: X-ray of thorax showing giant bullae almost replacing the entire left lung and multiple bullae of varying sizes in the right upper lobe with right moderate pneumothorax and multiple calcified mediastinal lymph nodes.**

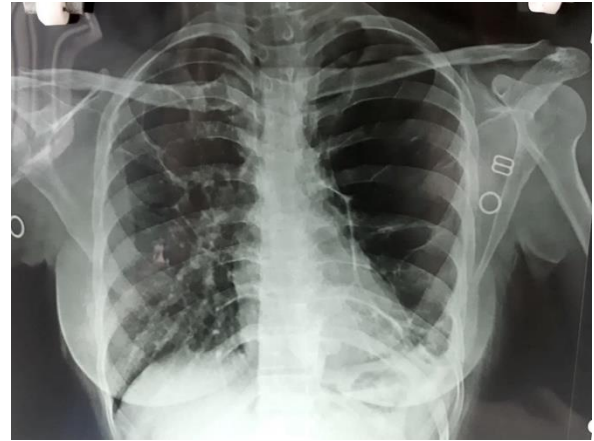


**Figures 6: CT of thorax showing giant bullae almost replacing the entire left lung and multiple bullae of varying sizes in the right upper lobe with right moderate pneumothorax and multiple calcified mediastinal lymph nodes.**

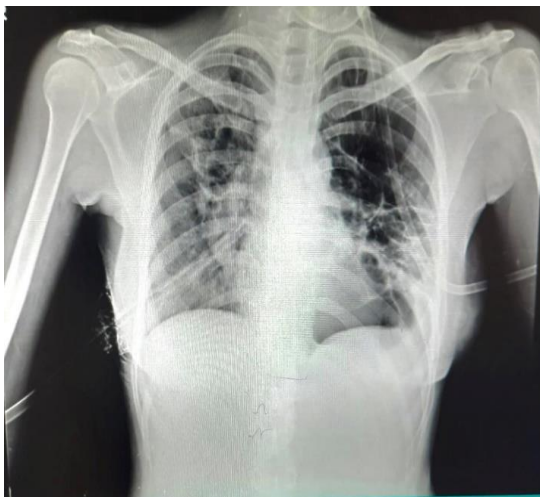An intercostal drain (ICD) was consequently inserted (Figure 7) and patient was managed symptomatically.

She was evaluated for vasculitis, connective tissue disorders and alpha 1 anti-trypsin deficiency which were negative. Serial radiological monitoring was done and following complete resolution of the pneumothorax and lung expansion (Figure 8), ICD was removed. Patient improved clinically and symptomatically and was consequently discharged and asked to continue ATT.

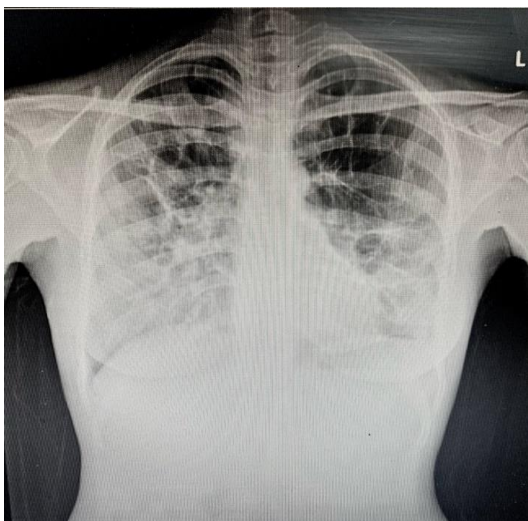
Patient was counselled regarding the need to abstain from strenuous activity, the possibility of recurrence of pneumothorax and the potential need for lung transplant in the future. Patient was reviewed after a period of 9 months; a repeat chest X-ray (Figure 9) taken showed a stable disease. a pulmonary function test along with DLCO done showed a mixed defect. Patient is currently stable and on regular follow-up.



**Figure 9: Repeat chest X-ray taken after 9 months showing stable disease.**



**Figure 7: Chest X-ray following right intercostal drain insertion.**



**Figure 8: Chest X-ray following intercostal drain removal.**

## DISCUSSION

Bullae are defined as air spaces in the lungs, measuring at least more than 1 cm in diameter when distended, while giant bullae, capable of causing vanishing lung syndrome (VLS) occupy at least a third of the hemithorax.<sup>1</sup> Roberts and colleagues, put forth the radiographic diagnostic criteria for vanishing lung syndrome, which include the presence of giant bulla in one or both upper lobes, occupying at least a third of the hemithorax and compressing the surrounding normal lung parenchyma.<sup>5</sup> One major complication of vanishing lung syndrome is pneumothorax, which typically presents with a history of sudden worsening in respiratory function with or without accompanying chest pain. High resolution computerized tomography (HRCT) shows the extent and distribution of the disease and also helps diagnose potential causes and coexisting conditions such as infected cysts, bronchiectasis, pulmonary artery enlargement, and pneumothorax.<sup>6</sup>

While development of bullous lung disease in patients suffering from Tuberculosis has been reported in the past, although exceedingly rare, the exact cause and mechanism is still unknown and may be attributed to multiple factors, including the presence of isoniazid in the antitubercular regimen, destruction of lung tissue, changes in the innervation and/or vasculo-nutrient factors in the lung, and adhesion of both pleurae bringing about a suction towards the defect, favoured by the patency of the bronchi.<sup>4</sup> The rarity of this in clinical practice suggests that the circumstances under which it may develop are complex and multifactorial which seldom co-exist. While a pneumothorax maybe managed by insertion of a chest tube, definitive management is surgical and includes giant bullectomy or lung transplantation.<sup>7,8</sup>

## CONCLUSION

Although tuberculosis is an ancient disease affecting humans for millennia and has been extensively studied and documented, it continues to present in atypical ways. Thus,



the possibility of development of bullous lung and consequent vanishing lung syndrome should be considered in patients suffering from pulmonary tuberculosis, particularly those receiving Isoniazid therapy.

*Funding: No funding sources*

*Conflict of interest: None declared*

*Ethical approval: Not required*

## REFERENCES

1. Sharma N, Justaniah AM, Kanne JP, Gurney JW, Mohammed TL. Vanishing lung syndrome (giant bullous emphysema): CT findings in 7 patients and a literature review. *J Thorac Imaging*. 2009;24:227-30.
2. Kalra SS, Pais F, Harman E, Urbine D. Rapid development of bullous lung disease: a complication of electronic cigarette use. *Thorax*. 2020;75:359.
3. Mireles-Cabodevila E, Sahi H, Farver C, Mohammed TL, Culver DA. A young patient with a minimal smoking history presents with bullous emphysema and recurrent pneumothorax. *Chest*. 2007;132:338-43.
4. Alarcon DG. Regressive Giant Bullous Emphysema in Tuberculosis of Adults. *Diseases of the Chest*. 1955;27(1):31-43.
5. Roberts L, Putman CE. "Vanishing lung syndrome: upper lobe bullous pneumopathy," *Revista Interamericana de Radiología*. 1987;12:249-55.
6. Morgan MDL, Strickland B. "Computed tomography in the assessment of bullous lung disease". *British J Dis Chest*. 1984;78:10-25.
7. Giller DB, Scherbakova GV, Giller BD. Surgical treatment of bilateral vanishing lung syndrome: a case report. *J Cardiothorac Surg*. 2020;15:201.
8. Kuno R, Kanter KR, Torres WE, Lawrence EC. Single lung transplantation followed by contralateral bullectomy for bullous emphysema. *J Heart Lung Transplant*. 1996;15(4):389-94.

**Cite this article as:** Rampradeep R, Gangadharan V, Gururaj P. A rare case of rapid development of bullous lung. *Int J Adv Med* 2022;9:899-902.