

Case Report

A rare case of adolescent tuberculous pericardial effusion: a case report

Dewi Hanifa Primanelza^{1*}, Arvin Pramudita², Riza Mansyoer³

¹Department of Child Health, ²Koja General Hospital, Jakarta, Indonesia

³Department of Child Health, Pediatric Emergency and Intensive Care Division, Koja General Hospital, Jakarta, Indonesia

Received: 30 June 2022

Accepted: 29 July 2022

*Correspondence:

Dr. Dewi Hanifa Primanelza,

E-mail: pdewihanifa@gmail.com

Copyright: © the author(s), publisher and licensee Medip Academy. This is an open-access article distributed under the terms of the Creative Commons Attribution Non-Commercial License, which permits unrestricted non-commercial use, distribution, and reproduction in any medium, provided the original work is properly cited.

ABSTRACT

Tuberculous pericarditis (TBP) is a rare case of extrapulmonary TB (EPTB) especially in the developed countries. This may cause serious and deadly impact if not diagnosed and treated properly. A-15-year-old girl was admitted with tightness of breath, weight loss, a productive cough and fatigue. Severe malnutrition, bronchial rales and anemia are present in patient. Chest x-ray showed pleural effusion with cardiomegaly. On three days later, Thoracic multi-slice spiral (MSCT) confirmed pericardial effusion, following pericardiocentesis on the fifth day. Tuberculous was confirmed by analysis of pericardial fluid. This patient was diagnosed as tuberculosis pericardial effusion showed complete recovery after pericardiocentesis and anti-tuberculosis drugs administration. Tuberculous is an endemic disease and its extrapulmonary forms should be included as a differential diagnosis. Early and adequate treatment decreases the risk of developing into a potentially fatal disease.

Keywords: Adolescent, Pericardial tuberculous, Extrapulmonary tuberculous

INTRODUCTION

Tuberculosis (TB) is one of the major causes of childhood mortality, especially in endemic areas. It is estimated that 239.000 children died from TB worldwide in 2015, with more than 96% of all deaths occurred in children not receiving treatment.¹ Indonesia is part of highly endemic countries with a high burden of TB.² World health organization (WHO) estimates that 8.3% of all TB cases in Indonesia were in children in 2018.³

TBP is a rare manifestation of extrapulmonary TB (EPTB). It presents clinically 3 forms, namely, pericardial effusion, constrictive pericarditis, and a combination of effusion and constriction.⁴ There is very little data to inform the current epidemiology of TBP in children. However, considering that EPTB accounts for up to 25% of all TB in children, it is likely an under-recognized problem.⁵ We report a case of an adolescent with tuberculous pericardial effusion, focusing on challenges in diagnosis and management.

CASR REPORT

A-15-year-old girl presented with a chief complaint of breathlessness for 7 days prior to admission, accompanied by a 10 kg weight loss in a month. A productive cough and fatigue were also present. No history of previous tuberculosis contact. Physical examination showed severe malnutrition (body mass index 12.2 kg/m²) and bronchial rales. No additional sound was found on chest auscultation. Lymph node palpation was normal. Laboratory values showed anemia (haemoglobin 8.8 g/dl), normal leukocyte (5.740/ul) with neutrophilia (85.1%), and increased C-reactive protein (10.3 mg/dl). COVID-19 tests were negative (Figure 1). Chest X-ray showed pleural effusion with marked cardiomegaly. On the second day, ASTO and tuberculin skin test (TST) were negative, whereas echocardiography showed dilated left ventricle with low ejection fraction (Figure 3). Thoracic multi-slice spiral CT (MSCT) performed three days later confirmed bilateral pneumonia with pericardial effusion. Pericardiocentesis was performed on the fifth day with an

aspirate of 850 ml serous fluid (Figure 2) showed chest X-ray after pericardium effusion evacuation. Tuberculosis was confirmed by the cytology analysis of the pericardial fluid. Following the result, anti-tuberculosis regimen was started with separate drug formulation. Adjunctive therapy with corticosteroid was also given. Improvements were clear and the patient got discharged after 9 days of hospitalization.

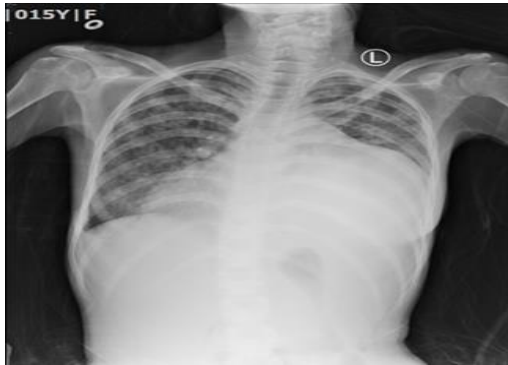


Figure 1: Initial chest X-ray in the ER.

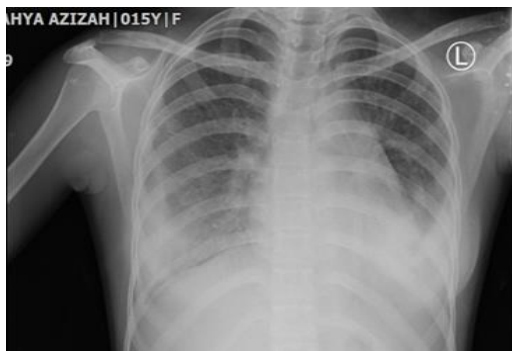

Figure 2: Chest X-ray after pericardium effusion evacuation.

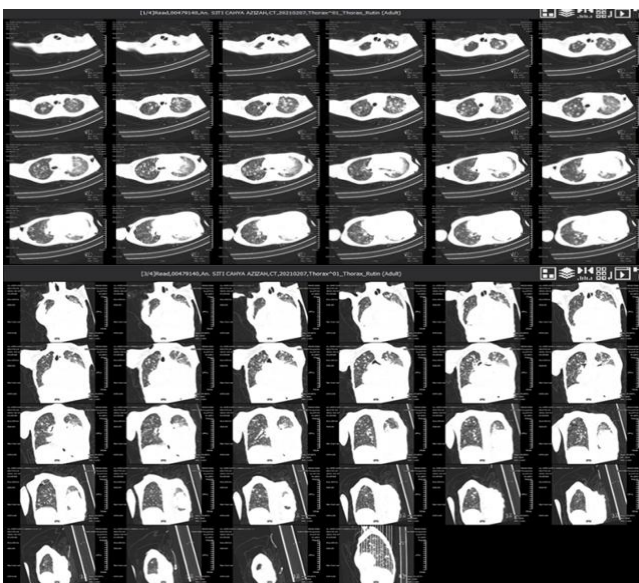


Figure 3: Initial MSCT in the PICU.

DISCUSSION

Pericardial effusion is the most common manifestation of TBP.⁶ *Mycobacterium tuberculosis* (Mtb) bacilli can enter the pericardium by retrograde lymphatic spread, hematogenous dissemination, or, uncommonly, by direct contiguous spread from adjacent infected structures such as the lungs, pleura, and spine.⁴ The ensuing pathological changes in the affected pericardium passes through four stages: fibrinous exudation with an initial polymorphonuclear leucocytosis, serosanguineous effusion with a predominantly lymphocytic exudates, absorption of effusion with organization of granulomatous caseation and pericardial thickening, and finally culminating in constrictive scarring that impedes diastolic filling and causes the classic syndrome of constrictive pericarditis.^{4,7}

TBP is categorized as ‘definite’ when tubercle bacilli are found in stained smear or culture of pericardial fluid and/or tubercle bacilli or caseating granulomata are found on histological examination of pericardium. A diagnosis of ‘probable’ TBP is made when there is evidence of pericarditis in a patient with TB demonstrated elsewhere in the body; and/or lymphocytic pericardial exudate with elevated adenosine deaminase (ADA) activity; and/or good response to antituberculosis drugs.⁴

Confirming a diagnosis of TBP in children is challenging due to practical difficulties in diagnostic sampling, its paucibacillary nature, and limited access to and the non-specific findings of echocardiography. TST was negative in our case and subsequent echocardiography failed to demonstrate signs of pericardial fluid. Although TST has a high sensitivity and specificity for detecting latent TB infection in children (97.2% and 91.9%, respectively), its accuracy in finding active cases remains obscure.⁸ The triad of known contact with an adult index case, positive TST, and suggestive signs on chest radiograph has been recommended by the International Standard for TB Care, but its accuracy is reduced in endemic areas. Since transmission in endemic areas is not restricted to the household, the diagnostic values of both documented household exposure and a positive TST are limited.⁹ On the other hand, CT scan is an extremely sensitive for the detection of pericardial fluid.¹⁰ However, CT scan is not readily available in most health centers, particularly in rural areas in Indonesia. A positive CT result three days after echo in our case suggests an active case of TB infection, thus complicating the difficulty of establishing the diagnosis of TBP.

Management of TBP is aimed toward attaining three goals: control of active infection; alleviation of the cardiac compression and adverse hemodynamic sequelae (tamponade and heart failure); and the prevention of complications such as constrictive pericarditis. Anti-tuberculous drug regimen for a minimum 6 months has been the standard of care for effective killing and control of Mtb infection.^{4,11} Needle pericardiocentesis remains the

treatment of choice to evacuate the pericardium of compressive pericardial fluid and alleviate cardiac tamponade.^{6,12} Open surgical drainage may be associated with less life-threatening re-accumulation requiring repeat pericardiocentesis.¹³ Corticosteroids have been used for the prevention of complications of maladaptive pericardial remodelling and healing, including constrictive pericarditis. Despite low certainty in the evidence, they are conditionally recommended by the WHO for people being treated for TBP.¹⁴ A recent Cochrane review found some evidence that corticosteroids decreased mortality amongst HIV-negative patients but had little association with constriction. Much of the available evidence includes high proportions of people living with HIV who were untreated with antiretroviral therapy making conclusions difficult to generalise.¹³

CONCLUSION

In conclusion, the reporting of this case is important to highlight the significance of timing of diagnosis and initiating appropriate care promptly for children with TBP. Early and appropriate treatment decreases the risk of developing into a potentially fatal disease.

Funding: No funding sources

Conflict of interest: None declared

Ethical approval: Not required

REFERENCES

- Dodd PJ, Yuen CM, Sismanidis C, Seddon JA, Jenkins HE. The global burden of tuberculosis mortality in children: a mathematical modelling study. *Lancet Glob Heal*. 2017;5(9):e898-906.
- World Health Organization. WHO global lists of high burden countries for tuberculosis (TB), TB/HIV and multidrug/rifampicin-resistant TB (MDR/RR-TB), 2021-2025: background document, 2021. Available at: <https://apps.who.int/iris/handle/10665/341980>. Accessed on 17 December 2021.
- World Health Organization. Global Tuberculosis Report 2019, 2019. Available at: <https://apps.who.int/iris/bitstream/handle/10665/329368/9789241565714-eng.pdf?ua=1>. Accessed on 17 December 2021.
- Mayosi BM, Burgess LJ, Doubell AF. Tuberculous pericarditis. *Circulation*. 2005;112(23):3608-16.
- Walls T, Shingadia D. Global epidemiology of paediatric tuberculosis. *J Infect*. 2004;48(1):13-22.
- Isiguzo G, Du Bruyn E, Howlett P, Ntsekhe M. Diagnosis and Management of Tuberculous Pericarditis: What Is New? *Curr Cardiol Rep*. 2020;22(1).
- Ntsekhe M, Mayosi BM. Tuberculous pericarditis with and without HIV. *Heart Fail Rev*. 2013;18(3):367-73.
- Susilawati TN, Larasati R. A recent update of the diagnostic methods for tuberculosis and their applicability in indonesia: A narrative review. *Med J Indones*. 2019;28(3):284-91.
- Marais BJ, Van Zyl S, Schaaf HS, Van Aardt M, Gie RP, Beyers N. Adherence to isoniazid preventive chemotherapy: A prospective community based study. *Arch Dis Child*. 2006;91(9):762-5.
- Kolski BC, Kakimoto W, Levin DL, Blanchard DG. Echocardiographic Assessment of the Accuracy of Computed Tomography in the Diagnosis of Hemodynamically Significant Pericardial Effusions. *J Am Soc Echocardiogr*. 2008;21(4):377-9.
- Nahid P, Dorman SE, Alipanah N, Barry PM, Brozek JL, Cattamanchi A, et al. Official American Thoracic Society/Centers for Disease Control and Prevention/Infectious Diseases Society of America Clinical Practice Guidelines: Treatment of Drug-Susceptible Tuberculosis. *Clin Infect Dis*. 2016;63(7):e147-95.
- Ristić AD, Imazio M, Adler Y, Anastasakis A, Badano LP, Brucato A et al. Triage strategy for urgent management of cardiac tamponade: A position statement of the European Society of Cardiology Working Group on Myocardial and Pericardial Diseases. *Eur Heart J*. 2014;35(34):2279-84.
- Wiysonge CS, Ntsekhe M, Thabane L, Volmink J, Majombozi D, Gumede F et al. Interventions for treating tuberculous pericarditis. *Cochrane Database Syst Rev*. 2017;9.
- Guidelines for treatment of drug-susceptible tuberculosis and patient care, 2017 update. Geneva: World Health Organization; 2017. Available at: <https://apps.who.int/iris/bitstream/handle/10665/9789241565714-eng.pdf?sequence=1>. Accessed on 25 March 2021.

Cite this article as: Primanelza DH, Pramudita A, Mansyoer R. A rare case of adolescent tuberculous pericardial effusion: a case report. *Int J Adv Med* 2022;9:939-41.