

## Case Report

# Precipitation of acute angle closure glaucoma following withdrawal of donepezil hydrochloride

Uvaraj Thresika\*, Sebastian Nayana

Department of Ophthalmology, Amala Institute of Medical Sciences, Amala Nagar, Thrissur, Kerala, India

**Received:** 04 June 2015

**Accepted:** 20 June 2015

**\*Correspondence:**

Dr. Uvaraj Thresika,

E-mail: [thresika@hotmail.com](mailto:thresika@hotmail.com)

**Copyright:** © the author(s), publisher and licensee Medip Academy. This is an open-access article distributed under the terms of the Creative Commons Attribution Non-Commercial License, which permits unrestricted non-commercial use, distribution, and reproduction in any medium, provided the original work is properly cited.

### ABSTRACT

Drug induced bilateral acute angle closure glaucoma (AACG) is well known entity reported but accidental withdrawal of a drug precipitating an attack of AACG is rare. Abrupt termination of donepezil, an FDA approved acetylcholinesterase inhibitor to treat mild to moderate Alzheimer's disease, is often attributed to occurrence of side effects. In this case, incidence of bilateral AACG following discontinuation of donepezil hydrochloride in a 76-year-old female patient with Alzheimer's disease is presented.

**Keywords:** Acute angle closure glaucoma, Donepezil hydrochloride, Alzheimer's disease, Iridotomy, Drug withdrawal glaucoma

### INTRODUCTION

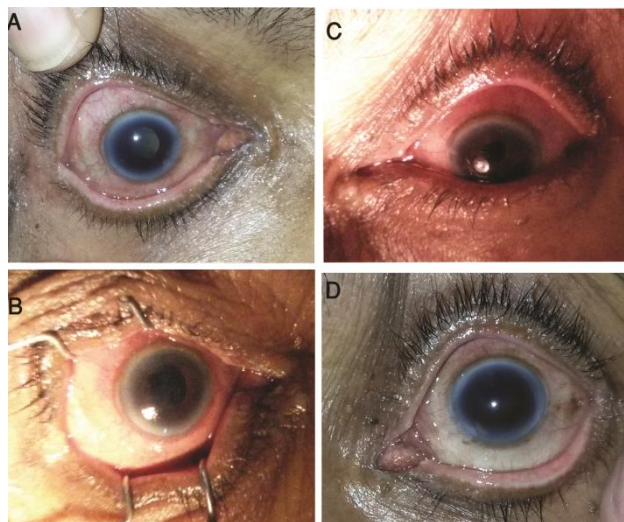
Risk factors for acute angle closure glaucoma (AACG) include genetic predisposition, shallow anterior chamber depth, high hypermetropia, increased lens thickness, small corneal diameter and increased age.<sup>1</sup> Drug induced bilateral (AACG) is well known entity reported to be precipitated by drugs like typical antipsychotics, serotonin-specific reuptake inhibitors, tricyclic antidepressants, antihistamines, adrenergic agonists, anticholinergics, sulpha based drugs, anticoagulants etc.<sup>2</sup> However, accidental withdrawal of a drug precipitating an attack of AACG is rare. We report a case of bilateral AACG following discontinuation of donepezil hydrochloride in a female patient with Alzheimer's disease (AD).

### CASE REPORT

A 76 year old female patient presented to hospital with nausea and vomiting of 3 days duration. She also complained of severe headache, blurring of vision and redness of both eyes of 12 hours duration; started 3 days

after the onset of nausea and vomiting. History revealed that the patient was a known case of AD, diagnosed 2yrs back and was taking donepezil hydrochloride (10 mg) once daily for the past 10 months. She had discontinued the drug 3 days back due to acute gastritis. There was no history of similar episodes in the past or other significant ocular history. Ophthalmic examination found symptoms and signs of acute congestive attack in both eyes (BE). Best corrected visual acuity in right eye (RE) was counting fingers close to face and left eye (LE) was CF 2m. Both eyes showed diffuse conjunctival congestion and hazy cornea (Figure 1 A and C). RE pupil was 5mm dilated, non-reacting and that of LE was 3.5 mm, sluggishly reacting. The intraocular pressure (IOP) of RE was 54.7 mmHg with 10 gm. weight and LE was 34.2mm Hg with 10gm weight. Slit lamp examination showed shallow anterior chamber with Van Herick grade I in BE and gonioscopy revealed narrow angles (grade I in all four quadrants in RE and grade I in three quadrants and grade zero in temporal quadrant in LE). The patient was diagnosed to have bilateral AACG and was started on topical antiglaucoma drugs, 0.5% Timolol maleate twice daily and 2% Pilocarpine nitrate four times daily BE for one week. Donepezil hydrochloride was restarted

immediately after the admission at the hospital. After three days of follow-up, the patient had symptomatic relief and the IOP came down to normal (RE, 20 mm of Hg and 17.3 mm of Hg in LE) (Figure 1-B and D). Once the acute attack was controlled, the patient was referred for laser iridotomy in BE.



**Figure 1:** A) Photographs of patient's right eye (RE) at the time of admission B) RE three days after the treatment C) Patient's left eye (LE) at the time of admission and D) LE three days after the treatment.

## DISCUSSION

AD is recognized as the most common cause of late life dementia in the world accounting for one half to two third of new dementia cases.<sup>3</sup> Donepezil hydrochloride is an FDA approved second generation acetylcholinesterase inhibitor given for mild to moderate AD.<sup>4,5</sup> The abrupt termination of donepezil is often attributed to occurrence of side effects, lack of efficacy or sometimes due to error or negligence.<sup>6,7</sup> Gastrointestinal side effects including nausea, vomiting and diarrhoea are the most common reported side effects.<sup>8</sup> The patient described in this case study was presented with decreased level of consciousness due to mild hyponatremia, hence a speculum was put to take photograph.

Elimination half-life of donepezil hydrochloride is 50-70 hours which is consistent with the temporal link between donepezil withdrawal and development of acute angle closure glaucoma in our case.<sup>9</sup> The exact mechanism of donepezil withdrawal and development of acute angle closure glaucoma remains elusive. The administration of donepezil has been found to be associated with pupillary constriction. The abrupt withdrawal of drug and its subsequent metabolism could lead to rebound dilatation of pupil. This would have caused pupillary block and angle closure in this case. The anatomically more compact anterior chamber in females as well as shallowness of anterior chamber with the aging could also ascribe to the exhibited angle-closure. A similar

incidence reported in a 55-year-old female Alzheimer's patient on withdrawal of donepezil.<sup>11</sup> Hence, an urge the need for cautious prescription of donepezil in AD should be made as the chances of abrupt drug discontinuation are high among these patients either due to drug side effects or the inherent forgetfulness associated with the disease. Donepezil was restarted immediately after the admission could improve the symptoms of the patient. Since, the patient was in a state of dehydration due to acute gastritis and vomiting, she was not able to tolerate the systemic administration of the antiglaucoma drugs. Topical application of Timolol maleate twice daily along with pilocarpine nitrate four times for 3 days could bring down the IOP.

## CONCLUSION

This case report suggest to increase the awareness about symptoms and signs of glaucoma among care givers of Alzheimer's patients so that early recognition and treatment of acute angle closure attack will be possible. Furthermore, a routine ophthalmic screening is recommended before initiating treatment with donepezil.

*Funding: No funding sources*

*Conflict of interest: None declared*

*Ethical approval: Not required*

## REFERENCES

1. Ritch R, Lowe RF. Angle closure glaucoma: Mechanisms and epidemiology. In: Ritch R, Shields MB, Krupin T, editors. *The glaucoma's*. 2nd ed. St Louis: CV Mosby Year Book Inc.; 1996; 801-819.
2. Lachkar Y, Bouassida W. Drug-induced acute angle closure glaucoma. *Curr Opin Ophthalmol.* 2007;18:129-33.
3. Geldmacher DS. Donepezil (Aricept) for treatment of Alzheimer's disease and other dementing conditions. *Expert Rev Neurother.* 2004;4:5-16.
4. Shigetani M, Homma A. Donepezil for Alzheimer's disease: pharmacodynamics, pharmacokinetic, and clinical profiles. *CNS Drug Rev.* 2001;7:353-68.
5. Doody RS. Clinical profile of donepezil in the treatment of Alzheimer's disease. *Gerontology.* 1999;45(Suppl 1):23-32.
6. Umegaki H, Itoh A, Suzuki Y, Nabeshima T. Discontinuation of donepezil for the treatment of Alzheimer's disease in geriatric practice. *Int Psychogeriatr IPA.* 2008;20:800-6.
7. Bidzan L, Bidzan M. Withdrawal syndrome after donepezil cessation in a patient with dementia. *Neurol Sci.* 2012;33:1459-61.
8. Wilkinson DG. The pharmacology of donepezil: a new treatment of Alzheimer's disease. *Expert Opin Pharmacother.* 1999;1:121-35.
9. Román GC, Rogers SJ. Donepezil: a clinical review of current and emerging indications. *Expert Opin Pharmacother.* 2004;5:161-80.

10. Estermann S, Daepf G-C, Cattapan-Ludewig K, Berkhoff M, Frueh BE, Goldblum D. Effect of Oral Donepezil on Intraocular Pressure in Normotensive Alzheimer Patients. *J Ocul Pharmacol Ther.* 2006;22:62-7.
11. Enzenauer RW, Bowers PJ. Angle-closure glaucoma after discontinuing donepezil hydrochloride

(Aricept). *J Gerontol A Biol Sci Med Sci.* 2005;60:1083.

**Cite this article as:** Thresika U, Nayana S. Precipitation of acute angle closure glaucoma following withdrawal of donepezil hydrochloride. *Int J Adv Med* 2015;2:306-8.