International Journal of Advances in Medicine
Sudarmika KA et al. Int J Adv Med. 2024 Nov;11(6):599-602
http://www.ijmedicine.com
pISSN 2349-3925 | eISSN 2349-3933
DOI: https://dx.doi.org/10.18203/2349-3933.ijam20243064

Case Report

Heart failure related to hyperthyroidism in young woman

Kadek Adi Sudarmika[1]*, Ni Luh Eka Sriayu Wulandari[2]

[1]Sanjiwani General Public Hospital, Gianyar, Bali, Indonesia
[2]Department of Cardiology and Vascular Medicine, Sanjiwani General Public Hospital, Gianyar, Bali, Indonesia

Received: 20 August 2024
Accepted: 12 September 2024

***Correspondence:**
Dr. Kadek Adi Sudarmika,
E-mail: adisudarmika21@gmail.com

Copyright: © the author(s), publisher and licensee Medip Academy. This is an open-access article distributed under the terms of the Creative Commons Attribution Non-Commercial License, which permits unrestricted non-commercial use, distribution, and reproduction in any medium, provided the original work is properly cited.

ABSTRACT

Acute decompensated heart failure is a clinical condition that is precipitated by underlying pathology, including thyroid disorders. The condition of hyperthyroidism can result in a hyperactive circulation, which can increase cardiac output and metabolic demands, ultimately leading to heart failure. A 35-year-old woman presented to the hospital with acute shortness of breath that increased during the night, as well as bilateral edema in the lower extremities, palpitations, and intermittent chest pain. According to the patient's medical history, hyperthyroidism was diagnosed two years ago; however, the patient has not adhered to the prescribed treatment. The physical examination shows low blood pressure (80/60 mmHg), tachycardia, and increased jugular venous pressure. Lung auscultation detects bilateral fine crackles. A decrease in ejection fraction is evident on echocardiography. The laboratory results indicated hyperthyroidism. Initial treatment includes a saline infusion, a dobutamine infusion, a high-dose furosemide drip, acetazolamide as an extra diuretic, clopidogrel, atorvastatin, isosorbide dinitrate under the tongue, sacubitril/valsartan, spironolactone, and enoxaparin. This case highlights the importance of recognizing the multifactorial nature of heart failure, especially in patients with hyperthyroidism.

Keywords: Acute decompensated heart failure, Hyperthyroidism, Cardiogenic shock

INTRODUCTION

Acute decompensated heart failure (ADHF) is a critical condition characterized by the sudden onset or worsening of heart failure symptoms, often requiring immediate medical attention. ADHF is a leading cause of hospital admissions and is associated with high morbidity and mortality rates. Numerous factors, including myocardial infarction, arrhythmia, and poorly controlled chronic diseases like hypertension, diabetes mellitus, and metabolic disorders like hyperthyroidism, can trigger this condition.[1,2] Hyperthyroidism is a condition characterized by excessive production of thyroid hormones, leading to a hypermetabolic state. Over time, this effect can lead to heart complications such as atrial fibrillation, heart failure, and cardiomyopathy. The relationship between hyperthyroidism and heart failure, particularly acute heart failure, has been well documented but is often underrecognized in clinical practice. Changes in thyroid hormone concentration directly affect abnormal changes in the structure and/or function of the heart, leading to complications such as heart failure and life-threatening arrhythmias.[3,4]

The management of hyperthyroidism in Indonesia presents unique challenges due to the varying levels of access to and awareness of healthcare services, highlighting the need for targeted public health interventions and improvements in diagnostic and treatment facilities. This case report underscores the importance of recognizing and managing hyperthyroidism to prevent severe heart complications. This also illustrates the need for routine follow-up and patient education to ensure adherence to the prescribed treatment. In this case, we aim to raise awareness about the cardiovascular risks associated with

hyperthyroidism and the importance of early and ongoing intervention.

CASE REPORT

A 35-year-old woman came to the hospital with complaints of acute shortness of breath that started one day ago. Shortness of breath initially occurs during light activities and does not improve after resting; the patient also experiences shortness of breath that causes frequent awakenings at night. In addition to shortness of breath, the patient complained of palpitations, left chest pain, and edema in both lower limbs for the past day. Similar complaints led to the patient's hospitalization two years ago. The diagnosis of hyperthyroidism occurred at that time. Despite receiving a prescription for thiamazole 3x10 mg, the patient did not take it for two years ago. The patient denies any history of diabetes mellitus, hypertension, or stroke, which are often associated with cardiovascular issues. The lack of adherence to treatment since her last hospitalization may have contributed to her symptoms worsening, leading to her current acute symptoms.

During the physical examination, the patient is in a good state of consciousness, or compos mentis. The Glasgow Coma Scale (GCS) score is E4V5M6. Vital signs indicate a blood pressure of 80/60 mmHg, a rapid and regular pulse (110 beats per minute), a respiratory rate of 26 breaths per minute, a temperature of 36.6°C, and an oxygen saturation of 99% with a non-rebreather mask at a flow rate of 12 liters per minute. The general examination did not show signs of anemia or jaundice in the eyes, but there was an increase in jugular venous pressure (JVP) of 5+4 cm H2O. The examination of the ears, nose, and throat (ENT) showed no abnormalities.

The cardiovascular assessment reveals normal heart sounds, specifically S1 and S2, along with a systolic murmur in the 5th intercostal space at the left midclavicular line. This murmur is grade III and radiates to the left axilla. Examining the breathing revealed vesicular breath sounds and fine rales on both sides, but no wheezing was present. Abdominal examination shows normal bowel sounds, no distension, and no tenderness upon palpation. An examination of the extremities reveals bilateral leg edema, warm extremities, and a capillary refill time of less than 2 seconds. The additional examinations conducted provide further insight into the patient's condition. The electrocardiogram (ECG) shows sinus tachycardia with an old myocardial infarction anterior (Figure 1). The chest X-ray results indicate cardiomegaly (Figure 2). A blood test showed that there were a few things that weren't right. The platelet count was low ($127\times10^3/\mu l$), the white blood cell count was high ($16.04\times10^3/\mu l$), and the hemoglobin level was slightly lower (11.6 g/dl). Hematocrit was 36.0%, and the red blood cell count was $4.62\times10\mu l$. Your electrolyte tests indicate hyponatremia with a sodium level of 127 mmol/l, while potassium and chloride levels are within the normal range at 4.1 mmol/l and 101 mmol/l, respectively. Kidney function tests show an elevated urea level of 89.3 mg/dl and creatinine at 1.22 mg/dl, indicating some degree of kidney impairment. Your thyroid function shows a low thyroid stimulating hormone (TSH) level of 0.22 µIU/ml and an increase in free T4 (FT4) of 26.29 pmol/l, consistent with hyperthyroidism.

An echocardiogram showed that all of the heart chambers were dilation, the left ventricle had eccentric hypertrophy (LVH), its systolic function was severely reduced (EF=30.43%), it had grade III diastolic dysfunction, the right ventricle could contract normally, there was mild mitral regurgitation, the estimated right atrial pressure (eRAP) was 15 mmHg, and the pericardium was normal. This finding is consistent with heart failure (Figure 3).



Figure 1: The patient's electrocardiogram shows sinus tachycardia with a rate of 110 beats per minute accompanied by pathological Q waves in leads V2-V3 (arrows sign).

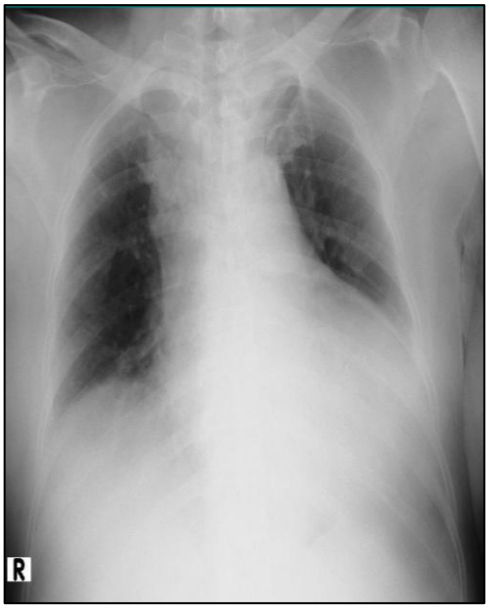

Figure 2. The chest X-ray shows heart enlargement consistent with the appearance of cardiomegaly.

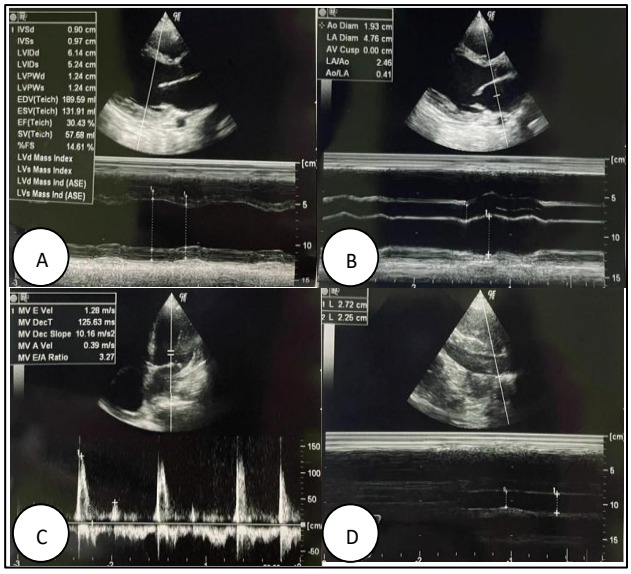

Figure 3: A. Decrease in ejection fraction function with a value of 30.43%; B. Dilation in the left atrium space; C. Diastolic dysfunction decreased to grade III, accompanied by dilation of all heart chambers; D. Estimated right atrial pressure (eRAP) increased by 15 mmHg.

The patient was diagnosed with acute decompensated heart failure profile C caused by hyperthyroidism with coronary artery disease (CAD) and cardiogenic shock after a history taking, physical exam, and other tests. The therapeutic approach aims to stabilize his hemodynamic status, manage his heart failure symptoms, address his thyroid condition, and prevent thromboembolic complications. The patient started intravenous fluid therapy with normal saline (IVFD NS) at a rate of 8 drops per minute to maintain adequate hydration and support their intravascular volume status. In addition, to increase cardiac output and address cardiogenic shock, a continuous infusion of dobutamine is administered at a dose of 5 µg/kg body weight per minute. Dobutamine, a beta-adrenergic agonist, helps to increase myocardial contractility and enhance cardiac output, which is crucial in managing cardiogenic shock.

The patient received a prescription for clopidogrel at a dose of 75 mg once daily to address the potential of coronary artery disease and reduce the risk of myocardial infarction. Clopidogrel, an antiplatelet agent, helps prevent platelet aggregation and thrombus formation. We also include atorvastatin at a dose of 20 mg once a day to manage dyslipidemia and reduce cardiovascular risk. Statins like atorvastatin are effective in lowering LDL cholesterol levels and stabilizing atherosclerotic plaques. We administer 5 mg sublingual isosorbide dinitrate (ISDN) as needed for chest pain to relieve angina symptoms. ISDN acts as a vasodilator, reducing myocardial oxygen demand and alleviating ischemic pain. The patient, suffering from fluid overload and significant edema, is receiving a furosemide drip at a rate of 20 mg per hour. The patient receives a daily dose of 250 mg of acetazolamide. The patient began treatment for heart failure with sacubitril/valsartan at a dose of 50 mg twice daily and spironolactone at a dose of 50 mg once daily. We administer Enoxaparin, a low molecular weight heparin, at a dose of 40 mg or 0.4 ml subcutaneously once a day to prevent thromboembolic events, a significant risk for patients with heart failure due to reduced mobility. This comprehensive therapeutic approach aims to stabilize the patient's condition, optimize heart function, manage symptoms, and prevent complications. We closely monitor the patient's response to this treatment regimen and make necessary adjustments to ensure the best outcomes.

DISCUSSION

Hyperthyroidism can lead to heart failure through several mechanisms. Thyroid hormones have the advantage of increasing metabolic rate and oxygen consumption, putting a greater burden on the cardiovascular system. In addition, it increases the sensitivity of beta-adrenergic receptors, thereby enhancing heart rate, contractility, and cardiac output. A chronic increase in thyroid hormones can lead to structural changes in the heart, such as left ventricular hypertrophy and dilation, as well as functional disorders like diastolic dysfunction. This change can lead to a condition characterized by symptoms of heart failure in the context of hyperthyroidism.[9,10] The goal of treating patients with thyroid heart disease is to restore euthyroidism and manage cardiovascular manifestations using oral antithyroid medications. We can treat hyperthyroidism with antithyroid medications such as PTU and imidazoles (like methimazole, thiamazole, and carbimazole). These two drugs, which belong to the thioamide group, work by stopping the formation of thyroid hormones, but do not affect the secretion of existing thyroid hormones. In the periphery, propylthiouracil can prevent the conversion of T4 into T3.[11-13]

Treatment for heart failure due to thyroid issues follows the general heart failure therapy. When there is excess fluid volume, diuretics and ARNI, a relatively new heart failure medication, help lower blood pressure and reduce afterload, thereby improving heart function and preventing cardiac remodeling.[14] Beta-blockers in patients with stable hemodynamics, along with the addition of aldosterone antagonists, help reduce fluid retention. Thyroid heart disease presents unique therapeutic challenges. Hyperthyroidism can lead to a hyperdynamic circulatory state, increasing cardiac output and metabolic demands.[15–17] Despite receiving a maximum dose of 20 mg/hour, the patient exhibits bilateral lower extremity edema, indicating insufficient diuretic effect. Acetazolamide is used as an adjunctive diuretic therapy. It works by inhibiting carbonic anhydrase in the proximal tubule, leading to increased excretion of bicarbonate, sodium, and water. This mechanism complements the work of loop diuretics, such as furosemide.[18-20] In this case, the addition of acetazolamide helps achieve fluid balance and better symptom control, illustrating its role in the management of

diuretic-resistant heart failure.[21] In this case, low blood pressure accompanied by hypoperfusion indicates cardiogenic shock.[22,23] Cardiogenic shock management entails hemodynamic support with inotropes such as dobutamine, which increases contractility and cardiac output. The use of comprehensive supportive measures, including fluid management and inotropic support, is crucial in stabilizing the patient's condition and addressing the causes of their heart failure.[24,25]

CONCLUSION

Effective management of heart failure in the context of thyroid dysfunction requires a multidisciplinary approach that includes cardiologists and endocrinologists working together in treatment.

Funding: No funding sources
Conflict of interest: None declared
Ethical approval: Not required

REFERENCES

1. Gheorghiade M, Pang PS. Acute heart failure syndromes. J Am Coll Cardiol. 2009;53(7):557-73.
2. Hussein M, Toraih E, Reisner ASC, Miller P, Corsetti R, Kandil E. Prevalence and mortality of cardiovascular events in patients with hyperthyroidism: a nationwide cohort study in the United States. Gland Surg [Internet]. 2021;10(9):2608-21.
3. Doodnauth Yacoub F, Solanki V, Trimmingham A, Soni LI, McFarlane S. NON-ST-segment elevation myocardial infarction associated with inadvertent thyroid hormone overdose. Am J Med Case Reports. 2021;9(3):194-7.
4. Sharma A, Stan MN. Thyrotoxicosis: diagnosis and management. Mayo Clin Proc. 2019;94(6):1048-64.
5. De Leo S, Lee SY, Braverman LE. Hyperthyroidism. Lancet. 2016;388(10047):906-18.
6. Ina Heart. Cardiovascular disease in Indonesia: facts and figures. Jakarta: Indonesian Heart Association. J Epidemiol Glob Health. 2024;14(1): 193–212.
7. Soesanto AM. Echocardiography detection of high-risk patent foramen ovale morphology. Indones J Cardiol. 2021;42(3):45-55.
8. Roger VL. Epidemiology of Heart Failure. Circ Res. 2013;113(6):646-59.
9. Kannan L, Shaw PA, Morley MP, Brandimarto J, Fang JC, Sweitzer NK, et al. Thyroid dysfunction in heart failure and cardiovascular outcomes. Circ Hear Fail. 2018;11(12):1-9.
10. Yamakawa H, Kato TS, Noh JY, Yuasa S, Kawamura A, Fukuda K, et al. Thyroid hormone plays an important role in cardiac function: from bench to bedside. Front Physiol. 2021;12:1-14.
11. Cappola AR, Desai AS, Medici M, Cooper LS, Egan D, Sopko G, et al. Thyroid and cardiovascular disease. circulation. 2019;139(25):2892–909.
12. Tallo NL, Sihombing ME. Kardiomiopati Tirotoksikosis. CDK-329. 2024;51(06):316–20.
13. Habibie M. Manifestasi Klinis dan Tatalaksana Penyakit Jantung Tiroid. J Kedokt Nanggroe Med. 2020;3(1):39-46.
14. Quiroz AJE, Durand VC, Lobato JCJ, Muñoz MJM, Gómez CDCD, Ildefonso NSP, et al. Thyrotoxic Cardiomyopathy: State of the Art. Eur Endocrinol. 2023;19(1):78.
15. Chen RJ, Suchard MA, Krumholz HM, Schuemie MJ, Shea S, Duke J, et al. Comparative first-line effectiveness and safety of ACE (angiotensin-converting enzyme) inhibitors and angiotensin receptor blockers: a multinational cohort study. Hypertension. 2021;78(3):591-603.
16. Messerli FH, Bangalore S, Bavishi C, Rimoldi SF. Angiotensin-converting enzyme inhibitors in hypertension: to use or not to use? J Am Coll CardioL. 2018;71(13):1474-82.
17. Shirakabe A, Matsushita M, Shibata Y, Shighihara S, Nishigoori S, Sawatani T, et al. Organ dysfunction, injury, and failure in cardiogenic shock. J Intensive Care. 2023;11(1):1-9.
18. Nandita SP, Kuncahyo I, Harjanti R. Formulation and optimization of furosemide snedds with variation concentration of tween 80 and PEG 400. J Fundam Appl Pharm Sci. 2021;2(1):34–42.
19. Oh SW, Han SY. Loop diuretics in clinical practice. Electrolytes Blood Press. 2015;13(1):17.
20. Sihite, Abdullah H, MF K, Muhsin M, Azhari G, Muhammad D. Thyroid heart disease in young male, a case report perdana. J Soc Med. 2021;2(1):24-8.
21. Vahdatpour C, Collins D, Goldberg S. Cardiogenic shock. J Am Heart Assoc. 2019;8(8):1-12.
22. Lescroart M, Pequignot B, Janah D, Levy B. The medical treatment of cardiogenic shock. J Intensive Med. 2023;3(2):114-23.
23. Hudaja DN, Soetjipto AS, Ariyani QS, Soesanto M, Pardede IM. A case series coexistence of PFO with other conditions - who's the culprit? Indones J Cardiol. 2021;42(3):90-9.
24. Vos T, Lim SS, Abbafati C, Abbas KM, Abbasi M, Abbasifard M, et al. Global burden of 369 diseases and injuries in 204 countries and territories, 1990–2019: a systematic analysis for the global burden of disease study 2019. Lancet. 2020;396(10258):1204–22.

Cite this article as: Sudarmika KA, Wulandari NLES. Heart failure related to hyperthyroidism in young woman. Int J Adv Med 2024;11:599-602.