

Case Report

Lennert's lymphoma - a diagnostic dilemma: a case report and pathologic review of literature

Akhil Kapoor^{1*}, Surender Beniwal¹, Ramesh Purohit¹,
Vanita Kumar², Harvindra Singh Kumar¹

¹Department of Oncology, Acharya Tulsi Regional Cancer Treatment & Research Institute, Bikaner, Rajasthan, India

²Department of Pathology, Sardar Patel Medical College, Bikaner, Rajasthan, India

Received: 13 December 2014

Accepted: 14 January 2015

*Correspondence:

Dr. Akhil Kapoor,

E-mail: kapoorakhil1987@gmail.com

Copyright: © the author(s), publisher and licensee Medip Academy. This is an open-access article distributed under the terms of the Creative Commons Attribution Non-Commercial License, which permits unrestricted non-commercial use, distribution, and reproduction in any medium, provided the original work is properly cited.

ABSTRACT

Lymphoepithelioid lymphoma, also referred to as Lennert's lymphoma is a T-cell lymphoma characterized by the massive proliferation of epithelial cell clusters infiltrating normal lymph nodal architecture along with lymphoid cells. Epithelial cells can also be associated with infectious lymphadenopathy and Hodgkin's lymphoma. This presents a diagnostic dilemma. We present a case of Lennert's lymphoma along with review of literature with special emphasis on morphological features and immunohistochemistry findings.

Keywords: Lymphoepithelioid lymphoma, Lennert's lymphoma, Epithelioid cell

INTRODUCTION

Lennert Lymphoma (LL), or the lymphoepithelioid variant of peripheral T-cell lymphoma, is an uncommon entity which was first characterized in 1952 by Karl Lennert.¹ It was initially considered as a variant of Hodgkin's Lymphoma (HL), but categorized as a non-Hodgkins lymphoma in 1975 when Lennert et al. changed their views and referred it as 'lympho-epithelioid cellular lymphoma'.² Though it has an almost unique histologic morphology characterized by two predominant cell populations: epithelioid cells and T lymphocytes, mainly of T helper/inducer phenotype.³ Though LL is a well described entity, it is rarely encountered in routine clinical practice. Also, the histological picture may be confused with various benign or other malignant conditions. This article intends to discuss morphological features and immunohistochemistry (IHC) findings of a case of LL

along with various close differential diagnoses that should be considered to clear the diagnostic dilemma.

CASE REPORT

A 50 year old male patient presented with weight loss, anorexia and neck swelling from two months. On physical examination, he was found to have numerous enlarged bilateral cervical lymph nodes and a lesser degree of bilateral inguinal lymphadenopathy along with hepatosplenomegaly. Contrast enhanced computed tomography of the abdomen revealed multiple discrete lymph nodes seen in periportal, peripancreatic, paraaortic and mesenteric regions. An additional finding was malrotated kidneys with the union of lower poles suggestive of horseshoe kidney. Serum lactate dehydrogenase was 850 U/ml. Erythrocyte sedimentation rate was 109 mm/hour. Other abnormal investigations included hemoglobin 8.2 gm/dl; serum albumin 3 gm/dl and total protein 7.1 gm/dl.

Excision biopsy was taken from cervical node of size 3×2.5×0.5 cm. The cut surface was homogeneously grayish white. On microscopic examination, the normal follicular architecture of lymph node with germinal follicular center was completely lost. Few residual follicles were seen associated with the expansion of paracortical zone by with diffuse polymorphous infiltration by small to medium sized lymphoid series cells, numerous clusters of pale stained epithelioid cells, a few eosinophils and plasma cells with prominent arborizing capillary vessels. Epithelioid histiocytes had oval to bean shaped nucleus with finely dispersed chromatin about twice the size of the lymphocytes with ample grayish granular cytoplasm. The lymphoid series cells were having scanty cytoplasm and round to ovoid nuclei with relatively open face nuclear chromatin (Figure 1). Classical or variants of Reed Sternberg giant cells could not be seen. Areas of caseation necrosis or Langhans giant cells were also not seen. The bimodal population of lymphoid series cells and epithelioid cells along with eosinophils, plasma cells and newly proliferating vascular channels was suggestive of Lymphoepithelioid Lymphoma (LL). The bone marrow biopsy did not reveal any lymphoid infiltration.

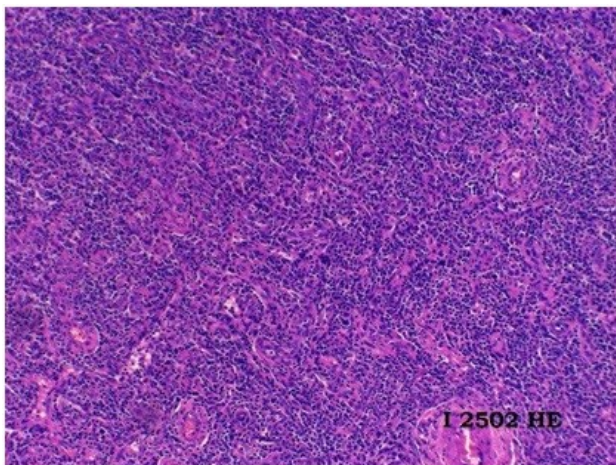


Figure 1: Photomicrograph of lymph node (4x) Hematoxylin-Eosin stain showing diffuse infiltration by small to medium sized lymphoid cells and clusters of pale stained epithelioid cells.

On IHC, CD45 was diffusely positive in lymphoid cells while CD20 was positive in few disrupted follicles. Expanded paracortical zone stained positive for CD3 and 5 with CD4 being positive in majority of T cells and CD8 in few scattered T cells. CD7 was focally positive in T cells and CD15 in granulocytes. Dendritic cells of residual follicles were positively stained for CD23 while CD10 was negative in the majority of the cells (Figure 2, 3) Thus, the overall picture suggested the diagnosis of Peripheral T Cell Lymphoma (PTCL) with epithelioid cells (Lennerts lymphoma), stage IIIB. Age adjusted international prognostic index predicted high intermediate group with a score of two (stage III and raised LDH).

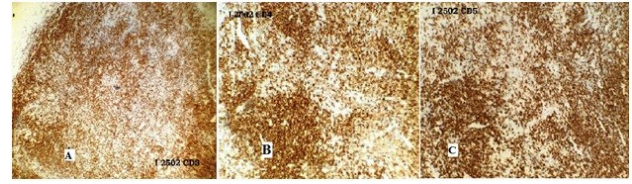


Figure 2: Photomicrograph demonstrating positive immunohistochemistic staining for (A) CD3, (B) CD4, and (C) CD5.

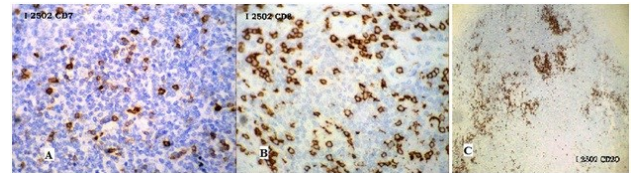


Figure 3: Photomicrograph demonstrating positive immunohistochemistic staining for (A) CD7, (B) CD8, and (C) CD20.

In view of CD20 positivity, standard R-CHOP regimen was planned, but due to poor financial status, only CHOP regimen could be given. After four cycles of chemotherapy, there has been favorable response with complete resolution of the cervical nodes. Two more cycles of the same chemotherapy followed by a complete reevaluation including imaging studies is planned.

DISCUSSION

LL is classified under “Peripheral T-cell lymphoma - Not otherwise specified” by the revised WHO classification system. Older individuals are generally affected by this lymphoma. In a retrospective analysis of 108 LL patients by Patsouris et al., the median age was 60 years.⁴ The case described in this report is of age 50 years. Splenomegaly and lymphadenopathy are the usual findings on presentation, with involvement of Waldeyer’s ring also frequently observed in European cases.⁵ The index case, who belongs to Asian Indian race presented with generalized lymphadenopathy and hepatosplenomegaly while there was no involvement of Waldeyer’s ring.

Histologically LL shows diffuse infiltrates consisting predominantly of small cells with marked nuclear irregularities. Clusters of epithelioid histiocytes are scattered within these infiltrates. Clear cells or high endothelial venules are less frequent than in peripheral T-cell lymphomas of angioimmunoblastic or T-zone type. Few Reed-Sternberg (RS)-like cells, eosinophils and plasma cells can be seen. However, in our case, no RS cell could be identified despite careful search. The above classic pathologic findings are vital in differentiating close differential diagnoses.

Epithelioid cell rich variant of mixed cellularity variety of HL is relatively common and shows clusters of

epithelioid cell with granulomata formation and occasional Langhans cells. Classical RS cells are always detected in this variant, at times after a laborious search which distinguishes it from LL. Such differentiation is mandatory in terms of dramatic treatment differences in the two entities.^{6,7} Other important features that may help to differentiate LL from HL include (a) the marked irregularity of the nuclear outlines of the lymphoid cells, in contrast to the regular nuclear outline of reactive lymphocytes in HL;⁸ (b) the IHC profile of the atypical population, which in turn is CD3⁺, CD45⁺, CD15⁻, and CD30⁺ occasionally, although T-cell markers may be absent in some cases; and (c) higher mitotic index.⁹ These features matched with the case described in the report. Besides conventional IHC staining for CD markers, T-cell Intracellular Antigen-1 (TIA-1) is also reported to be expressed in 70% cases of LL.¹⁰ TIA-1 is a 15 kD cytotoxic granule-associated protein expressed by cytotoxic T-cells. Perforin punctures a hole in the membrane of a target cell. TIA-1 and granzyme enter through the hole and activate proteins which induce apoptosis. Perforin and granzyme are only expressed upon activation of cytotoxic cells; TIA-1 is expressed irrespective of the activation state of cytotoxic T-cells and myeloid cells. This is in contrast to perforin and granzyme B, the expression of which increases in activated cells. However, TIA-1 staining was not performed in the reported case. Bone marrow involvement is common at presentation. However, the case described did not have any infiltration of the bone marrow.

A pathologist should also be aware of the term Lennert's pattern. This is a histologic picture of diffuse epithelioid population scattered throughout the lymph node.¹¹ The monomorphic background can easily rule out sarcoidosis or other reactive or immunologic process. The cytology of Natural killer/T-cell lymphomas show more pleomorphism with irregular chromatin distribution and usually no epithelioid cells.¹¹ Fine needle aspiration cytology of lymph node can be misinterpreted as involvement by high grade mycosis fungoides with a monotonous population of large and small cells. However, it should be kept in mind that mycosis shows more anisocytosis with cerebriform convoluted nuclei against a background of atypical lymphocytes, and plasma cells.^{13,14} Those cases of T-cell rich B-cell lymphoma, which can show also many epithelioid cells and predominance of mature small lymphocytes with few or absent atypical large, immature lymphoid cells should be considered in the differential diagnosis.¹² However atypical large lymphoid cells are much more scarce in LL and IHC can clearly differentiate between them, as the large cells show B-cell marker and the small lymphocytes does not have aberrant antigen expression.

In the case under discussion, CD4 was positive in majority of T cells and CD8 in few scattered T cells; thus, it may point towards the possible origin of LL from cytotoxic T-cells. Double-labeling experiments in four

patients of LL by Feller et al showed that mainly the CD4 positive helper/inducer T cells were proliferating as they were strongly Ki67-positive and the CD8 + lymphocytes and epithelioid cells were Ki67-negative.³ If, as in other malignancies, the proliferating cells represent the neoplastic cell clone, these results leave little doubt as to the T cell nature of Lennert's lymphoma and indicate that the neoplastic cells are phenotypically helper/inducer T cells. However, of 17 LL cases studied by Geissinger et al,¹⁵ expressed CD8, one each was CD4⁺ and CD4⁻CD8⁻; thus, they concluded that nodal peripheral T-cell lymphomas and, in particular, their lymphoepithelioid (Lennert's) variant are often derived from CD8 (+) cytotoxic T-cells.¹⁵ Yamashita et al. studied ten cases of LL to evaluate the cellular origin of the neoplastic cells. They concluded that though LL was formerly known as a CD4⁺ helper T-cell neoplasm, at least in some cases, the neoplastic cells are of cytotoxic T-cell origin.¹⁰

The response to chemotherapy is often poor with mean overall survival being about 42 months.¹² Standard treatment approaches for PTCL NOS include chemotherapy with cyclophosphamide, doxorubicin, vincristine and prednisone (CHOP); fludarabine and cyclophosphamide; and ifosfamide, carboplatin and etoposide (ICE). If CD52 is positive, alemtuzumab may be used with a standard dosing regimen of 30 mg every third day.¹⁶ For relapsed patients, reduced intensity conditioning and allogeneic stem cell transplantation after salvage therapy integrating alemtuzumab for patients. However, the prognosis remains poor with the majority of the series reporting 5-year overall survival of approximately 30-35% using standard chemotherapy.¹² When regarded as a sub entity of PTCL NOS, LL is usually treated with CHOP for initial treatment often consolidated by high dose chemotherapy and autologous stem cell transplantation in case of good remission following induction therapy.¹⁷

To conclude, LL can present as a diagnostic dilemma to a pathologist and the various features which distinguish it from related diseases should be always kept in mind due to completely different management and prognosis of the disease.

Funding: No funding sources

Conflict of interest: None declared

Ethical approval: Not required

REFERENCES

1. Aboud KA, Aboud DA. Eponyms in the literature of cutaneous lymphomas. *Our Dermatol Online*. 2013;4(3):385-8.
2. Lennert K, Mohri N, Stein H, Kaiserling E. The histopathology of malignant lymphoma. *Br J Haematol*. 1975;31(Suppl):193-203.
3. Feller AC, Griesser GH, Mak TW, Lennert K. Lymphoepithelioid lymphoma (Lennert's

- lymphoma) is a monoclonal proliferation of helper/inducer T cells. *Blood*. 1986;68:663-7.
4. Patsouris E, Engelhard M, Zwingers T, Lennert K. Lymphoepithelioid cell lymphoma (Lennert's lymphoma): clinical features derived from analysis of 108 cases. *Br J Haematol*. 1993;84:346-8.
 5. Lennert K, Mestdagh J. Hodgkin's disease with constantly high content of epithelioid cells. *Virchows Arch A Pathol Pathol Anat*. 1968;344:1-20.
 6. Banks PM. The distinction of Hodgkin's disease from T cell lymphoma. *Semin Diagn Pathol*. 1992;9:279-83.
 7. Patsouris E, Handennert N. Cytohistologic and immunohistochemical findings in Hodgkin's disease, mixed cellularity type, with a high content of epithelioid cells. *Am J Surg Pathol*. 1989;13(12):1014-22.
 8. Butler JJ. The histologic diagnosis of Hodgkin's disease. *Semin Diagn Pathol*. 1992;9:252.
 9. Osborne BM, Uthman MO, Butler JJ, McLaughlin P. Differentiation of T-cell lymphoma from Hodgkin's disease: mitotic rate and S-phase analysis. *Am J Clin Pathol*. 1990;93:227.
 10. Yamashita Y, Nakamura S, Kagami Y, Hasegawa Y, Kojima H, Nagasawa T, et al. Lennert's lymphoma: a variant of cytotoxic T-cell lymphoma? *Am J Surg Pathol*. 2000;24:1627-33.
 11. Gerdes I, Lemke H, Baisch H, Wacker HH, Schwab U. Stein cell cycle analysis of a cell proliferation-associated human nuclear antigen defined by the monoclonal antibody Ki-67. *Immunology*. 1984;133:1710.
 12. Knowles DM. Neoplastic Hematopathology. In: Knowles DM, eds. 2nd ed. Philadelphia: Lippincott Williams and Wilkins; 2001: 530-531. Wulf GG, Hasenkamp J, Jung W, Chapuy B, Truemper L, Glass B. Reduced intensity conditioning and allogeneic stem cell transplantation after salvage therapy integrating alemtuzumab for patients with relapsed peripheral T-cell non-Hodgkin's lymphoma. *Bone Marrow Transplant*. 2005;363:271-3.
 13. Melnyk A, Rodriguez A, Pugh WC, Cabannillas F. Evaluation of the revised European-American lymphoma classification confirms the clinical relevance of immunophenotype in 560 cases of aggressive non-Hodgkin's lymphoma. *Blood*. 1997;89:4514-20.
 14. Gisselbrecht C, Gaulard P, Lepage E, Coiffier B. Prognostic significance of T-Cell phenotype in aggressive non-Hodgkin's lymphomas, for the groupe d'Etudes des lymphomes de l'adulte (GELA). *Blood*. 1998;92:76-82.
 15. Geissinger E, Odenwald T, Lee SS, Bonzheim I, Roth S, Reimer P, et al. Nodal peripheral T-cell lymphomas and, in particular, their lymphoepithelioid (Lennert's) variant are often derived from CD8(+) cytotoxic T-cells. *Virchows Arch*. 2004;445(4):334-43.
 16. Zeitlinger MA, Schmidinger M, Zielinski CC, Chott A, Raderer M. Effective treatment of a peripheral T-cell lymphoma/lymphoepithelioid cell variant (Lennert's lymphoma) refractory to chemotherapy with the CD-52 antibody alemtuzumab. *Leuk Lymphoma*. 2005;46:771-4.
 17. D'Amore F, Relander T, Lauritzsen GF, Jantunen E, Hagberg H, Anderson H, et al. Up-front autologous stem-cell transplantation in peripheral T-cell lymphoma: NLG-T-01. *J Clin Oncol*. 2012;30:3093-9.

DOI: 10.5455/2349-3933.ijam20150211

Cite this article as: Kapoor A, Beniwal S, Purohit R, Kumar V, Kumar HS. Lennert's lymphoma - a diagnostic dilemma: a case report and pathologic review of literature. *Int J Adv Med* 2015;2:47-50.