

## Case Report

### Xanthoma disseminatum

Deepak Sharma<sup>1</sup>, Nikha Garg<sup>1</sup>, Tarunveer Singh<sup>1</sup>, Kanwarjit S. Dhillon<sup>1\*</sup>,  
Nishi Tandon<sup>2</sup>, Mohd Sadiq Umar<sup>1</sup>, Vidhi Agrawal<sup>1</sup>, Ritika Srivastava<sup>1</sup>

<sup>1</sup>Department of Dermatology, Era's Lucknow Medical College, Lucknow, Uttar Pradesh, India

<sup>2</sup>Department of Pathology, Era's Lucknow Medical College, Lucknow, Uttar Pradesh, India

**Received:** 1 January 2015

**Accepted:** 19 January 2015

**\*Correspondence:**

Dr. Kanwarjit S. Dhillon,

E-mail: kanwarjit29@yahoo.co.in

**Copyright:** © the author(s), publisher and licensee Medip Academy. This is an open-access article distributed under the terms of the Creative Commons Attribution Non-Commercial License, which permits unrestricted non-commercial use, distribution, and reproduction in any medium, provided the original work is properly cited.

#### ABSTRACT

Xanthoma disseminatum is a rare, benign, normolipemic form of non-Langerhans cell histiocytosis affecting the skin and mucous membranes. The cutaneous manifestations consist of hundreds of papules that are red – brown at first and then become yellowish. The papules symmetrically involve the eyelids, trunk, face and proximal extremities and in flexures and folds, tend quickly to merge, forming soft plaques. It is frequently associated with diabetes insipidus. Biopsy specimens show a mixture of histiocytes, foam cells, and inflammatory cells. Later, foam cells predominate and Touton giant cells are frequently present. This chronic disease has no known established treatment.

**Keywords:** Xanthoma, Non-Langerhans cell histiocytosis, Diabetes insipidus

#### INTRODUCTION

Xanthoma disseminatum is a rare non-familial disease, characterized by proliferation of histiocytic cells in which lipid deposition is a secondary event. The disease predominantly affects male children and young adults, with involvement of the skin, mucous membranes of eyes and upper respiratory tract, the meninges and rarely other organs including liver, spleen and bone marrow.<sup>1-4</sup> No known trigger for xanthomatous proliferation and deposition has been identified.<sup>5</sup>

Xanthoma disseminatum is a self-limiting disease but may persist for years. Skin lesions of xanthoma disseminatum are disfiguring and patients often request treatment. The carbon dioxide laser has been used with good results.<sup>6</sup>

Azathioprine and cyclophosphamide have been effective in some patients with cutaneous disease.<sup>7</sup> Lesions are only mildly radiosensitive.

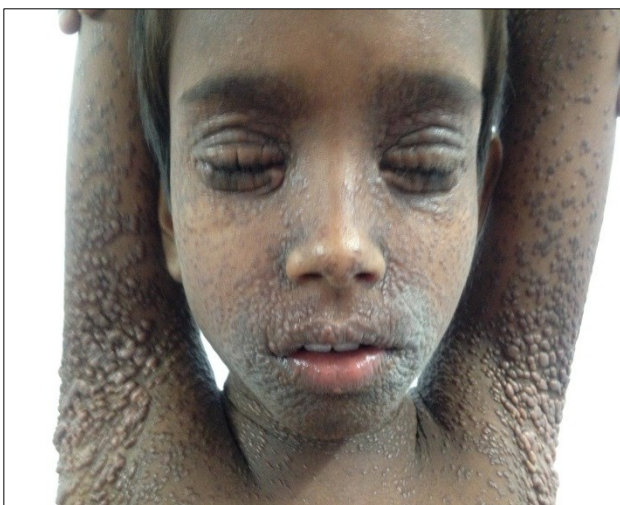#### CASE REPORT

10 year old male child presented to our department with insidious onset of skin eruptions involving the whole body (Figure 1) of 4 years duration. The lesions first appeared on the trunk, then gradually progressed to involve the face (Figure 2), upper limb, flexural area of axilla. Later, it spread to the lower limbs and the flexural areas of groin (Figure 3) and became confluent. Whole body was involved within a period of two years after the initial trunk involvement. Patient also complained of excessive thirst and urination 7-8 times a day. No H/o difficulty in eating or speaking. No H/o difficulty in viewing objects or fits. No pruritus. On examination there were small, yellow-red to brown papules and nodules that were discrete and disseminated seen on the face (including upper eyelids), peri-oral region (confluent xanthomatous plaques), nape of neck, ears, axilla, scapular region, upper limbs, abdomen, groins, shaft of penis, buttocks and popliteal fossa. Buccal mucosa was involved. Tongue also showed xanthomatous lesions.

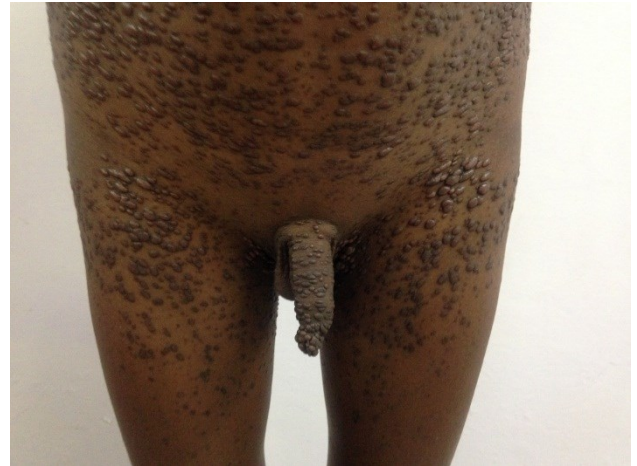Palms & soles unremarkable. Scalp hair were not involved. Investigations revealed Hb 10.0 gm/dl. TLC 9000 per cubic mm. N55, L30, E15, M00. Platelet count 3.0 lakh/cumm. Urine RE: shows 2-4 pus cells. LFT: WNL. Lipid profile: S. cholesterol 144.0 mg/dl. Serum triglycerides 119.0 mg/dl. Serum HDL cholesterol 47.0 mg/dl. Serum VLDL cholesterol 23.8 mg/dl. Serum LDL Cholesterol 73.2 mg/dl. Skin biopsy (on H&E staining at 40x) showed infiltration in dermis with lymphocytes, polymorphs, foamy histiocytes & eosinophils (Figure 4).



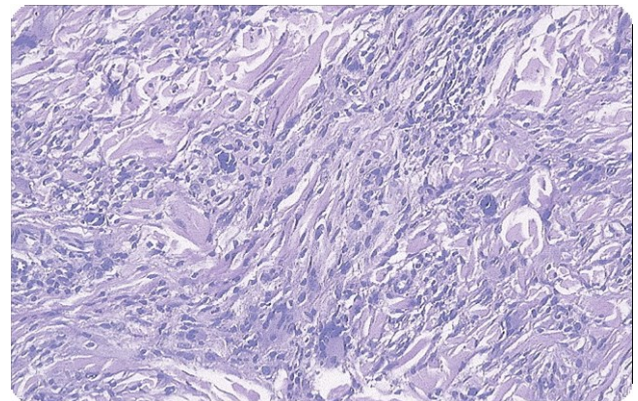
**Figure 1: Eruptions all over the body.**



**Figure 2: Nodular lesions on the face, neck and axilla.**



**Figure 3: Lesions on the lower abdomen, genitals & groins.**



**Figure 4: H&E staining (40x) showing dermal infiltration and foamy cells.**

## DISCUSSION

Xanthoma disseminatum is a rare, non-Langerhans cell histiocytic syndrome that predominantly affects young men and seems to be sporadic. No familial cases have been reported. The disease often begins insidiously but may lead to extensive morbidity. It usually presents with red to yellow papules and nodules, often in such flexural sites as the axillae and groin, that gradually enlarge over several years, forming confluent xanthomatous plaques. Mucous membrane involvement occurs in 40% to 60% of patients, mostly affecting the oropharynx (leading to dysphagia), larynx (dyspnea), or the cornea and conjunctiva (blindness). Involvement of non-mucocutaneous sites also occurs; 40% of patients eventually have diabetes insipidus due to meningeal involvement in the pituitary fossa. Central nervous system lesions may present with epilepsy, hydrocephalus or cerebellar ataxia. Osteolytic bone lesions and synovitis have been described. Histopathologic results include diffuse dermal infiltration by histiocytes and Touton giant cells, along with a sparsity of lymphocytes, plasma cells, and neutrophils. Usually, eosinophils are not a prominent component of the inflammation. The response to any

form of treatment in XD is at best unsatisfactory. Surgical excision or laser therapy can improve physical and functional appearance, but the course of the disease is characteristically punctuated with frequent relapses. Treatment with anti-mitotic drugs has been ineffective in many reported cases.<sup>8</sup> Oral corticosteroids do not seem to be remittive, but may offer some palliation and possibly deter recurrence of cutaneous lesions after surgical excision. Clofibrate has been of limited benefit in a few cases. Cyclophosphamide and azathioprine have been reported to be effective in selected cases.<sup>9</sup> Calverly et al.<sup>10</sup> described a patient with treatment failure to prednisone and vinblastine used in combination, although vinblastine was reported to be effective in another case.<sup>8</sup> Azathioprine was reported to be ineffective for a patient with upper respiratory tract involvement<sup>11</sup> Stojkovic et al.<sup>12</sup> reported symptomatic improvement in an 18-year-old girl with XD and central nervous system lesions treated with a combination of corticosteroid treatment and chemotherapy. Seaton et al.<sup>9</sup> reported that cutaneous lesions remained stable during azathioprine administration, although pre-existing plaques did not improve and ocular lesions progressed despite treatment. Cyclophosphamide therapy has resulted in significant resolution of cutaneous, ocular, and laryngeal lesions.

*Funding: No funding sources*

*Conflict of interest: None declared*

*Ethical approval: Not required*

## REFERENCES

1. Komatsuda A, Chubach A, Miura AB. Virus associated haemophagocytic syndrome due to measles accompanied by acute respiratory failure. J Intern Med. 1995;34:203-6.
2. Atzman J, Winklemann RK. Xanthoma disseminatum. Arch Dermatol. 1962;86:582-9.
3. Calverly DC, Wismer J, Rosenthal D, deSa D, Barr RD. Xanthoma disseminatum in an infant with skeletal and marrow involvement. J Pediatr Hematol Oncol. 1995;17:61-5.
4. Fleishmajer R. Xanthoma disseminatum. In: Fleishmajer R, eds. Dyslipoides. 1st ed. Springfield, IL: Thomas; 1960: 176-183.
5. Yusuf SM, Mijinyawa MS, Musa BM, Mohammed AZ. Xanthoma disseminatum in a black African woman. Int J Dermatol. 2008;47(11):1145-7.
6. Carpo BG, Grevelink SV, Brady S, Gellis S, Grevelink JM. Treatment of cutaneous lesions of xanthoma disseminatum with CO<sub>2</sub> laser. Dermatol Surg. 1999;25:751-4.
7. Seaton ED, Pillai GJ, Chu AC. Treatment of xanthoma disseminatum with cyclophosphamide. Br J Dermatol. 2004;150:346-9.
8. Pruvost C, Picard-Dahan C, Bonnefond B, Grossin M, Gehanno P, Souteyrand P, et al. Vinblastine treatment for extensive non-X histiocytosis (xanthoma disseminatum). Ann Dermatol Venereol. 2004;131(3):271-3.
9. Seaton ED, Pillai GJ, Chu AC. Treatment of xanthoma disseminatum with cyclophosphamide. Br J Dermatol. 2004;150(2):346-9.
10. Calverly DC, Wismer J, Rosenthal D, deSa D, Barr RD. Xanthoma disseminatum in an infant with skeletal and marrow involvement. J Pediatr Hematol Oncol. 1995;17(1):61-5.
11. Büyükcavci M, Selimoglu A, Yildirim U, Ertekin V, Atasoy M. Xanthoma disseminatum with hepatic involvement in a child. Pediatr Dermatol. 2005;22(6):550-3.
12. Stojkovic T, de Seze J, Maurage CA, Rose C, Hache JC, Vermersch P. Atypical form of non-Langerhans histiocytosis with disseminated brain and leptomeningeal lesions. J Neurol Neurosurg Psychiatry. 2000;69(5):675-8.

DOI: 10.5455/2349-3933.ijam20150218

**Cite this article as:** Sharma D, Garg N, Singh T, Dhillon KS, Tandon N, Umar MS, Agrawal V, Srivastava R. Xanthoma disseminatum. Int J Adv Med 2015;2:71-3.