

Case Report

Reactive perforating collagenosis

K. S. Dhillon^{1*}, Uroos Fatima², Isha Singh¹, Tarunveer Singh¹,
Tanu Gupta¹, Nawed Khan¹, Krati R. Varshney³, Rakhee Sharma⁴

¹Department of Dermatology, Era's Lucknow Medical College & Hospital, Lucknow-226003, Uttar Pradesh, India

²Department of Pathology, Era's Lucknow Medical College & Hospital, Lucknow-226003, Uttar Pradesh, India

³Department of Microbiology, Era's Lucknow Medical College & Hospital, Lucknow-226003, Uttar Pradesh, India

⁴Department of Gynaecology, Era's Lucknow Medical College & Hospital, Lucknow-226003, Uttar Pradesh, India

Received: 18 April 2014

Accepted: 27 April 2014

***Correspondence:**

Dr. K. S. Dhillon,

E-mail: kanwarjit29@yahoo.co.in

© 2014 Dhillon KS et al. This is an open-access article distributed under the terms of the Creative Commons Attribution Non-Commercial License, which permits unrestricted non-commercial use, distribution, and reproduction in any medium, provided the original work is properly cited.

ABSTRACT

Reactive Perforating Collagenosis (RPC) is a rare disease of elimination of altered collagen through the epidermis. The disease exists in childhood form with autosomal recessive mode of inheritance and an adult form acquired in association with diseases such as Diabetes Mellitus (DM), Chronic Renal Failure (CRF), hypothyroidism, lymphoma, hyperparathyroidism, neurodermatitis, AIDS, pulmonary fibrosis, scabies and herpes zoster infection.

Keywords: Reactive perforating collagenosis, Diabetes mellitus, Chronic renal failure

CASE REPORT

A 22 year old female, a housewife, came to us with complaints of small papular lesions over hands and feet of 2 years duration. Papules were initially 1-2 mm in size and gradually increased in size over a period of time. Papules were skin coloured and extremely pruritic. Patient also developed similar lesions over elbows, knees and infra-mammary area. Subsequently, the lesions became umbilicated over a period of 3-5 weeks and patient noticed extrusion of greyish-white material from the centre of the lesions. Individual stated development of fresh lesions on scratching and also at the site of minor trauma. The lesions used to regress spontaneously, usually, after 2-3 months of evolution with a resultant hyperpigmented patch with central hypopigmentation. There was history of winter exacerbation of lesions with improvement in summer months. She sought treatment but with no benefits. In the past, patient was diagnosed as a case of renal stones 3 years back when she developed dribbling of urine for which she took treatment from a

local practitioner and the symptoms had abated. No follow-up was done. The patient does not suffer from any chronic disability in the form of diabetes mellitus, TB, Asthma or hypertension. Individual of average built and nourishment. Afebrile. Vital parameters were within normal limits: BP - 110/70 mm of Hg. Pulse - 76/min. Respiration rate - 16/min. No icterus, cyanosis, clubbing, lymphadenopathy, pedal oedema. Multiple small dome shaped papules over feet (Figure 1), hands (Figure 2), elbows, forearm, lower limbs and buttocks (Figure 3) measuring from between 2 to 5 mm in diameter. Few lesions were skin coloured & others were hyperpigmented (Figure 4) with central umbilication. Central keratotic plugging was seen. Greyish black keratotic debris were seen extruding out from some of the lesions (Figure 1). Lesions were seen in different stages of development and Koebner's phenomenon was demonstrable. Residual scars and areas of hyperpigmentation were also visible. Other systemic examination was unremarkable. Investigations revealed the following: hemoglobin - 11 gm/dl, total leucocyte count - 8000 cu/mm with 61% polymorphs and 33%

lymphocytes. Blood urea - 48 mg/dl, serum creatinine - 1.2 mg/dl. Blood sugar (random) - 91 mg/dl and chest X-ray was normal. USG abdomen revealed showed a left renal calculus measuring around 6.7 mm at lower calyx. Skin biopsy taken from the dorsum of the foot showed a shallow cup-shaped lesion with a central crusted ulceration containing degenerated collagen in vertical strands, parakeratotic horny material, inflammatory cells and transepidermal elimination of collagen fibres from the dermis through the defect in the epidermis (H & E - 100x) (Figure 5). In view of the clinical findings and investigations reports, a diagnosis of Acquired Reactive Perforating Collagenosis (ARPC) with renal calculus was made. Treatment with topical retinoids and antihistamines was started. When reviewed after 1 month of therapy, there was symptomatic improvement in skin lesions. Hair, Mucous Membranes and nails were normal.

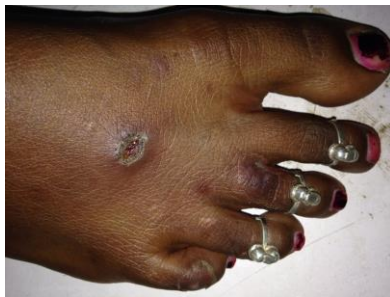

Figure 1: Central keratotic plugging is seen.

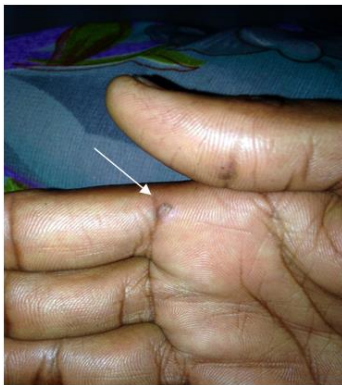

Figure 2: Lesion over palm.

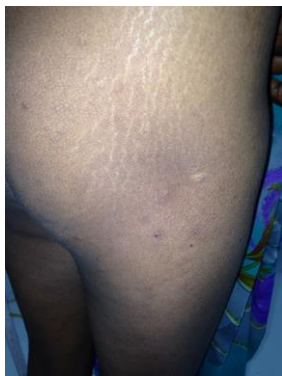

Figure 3: Lesions over buttocks.

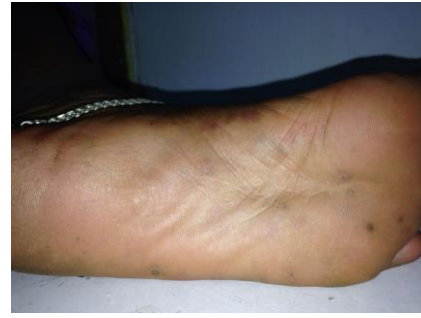

Figure 4: Lesion with central keratotic plugging interspersed with resolving hyperpigmented lesions.

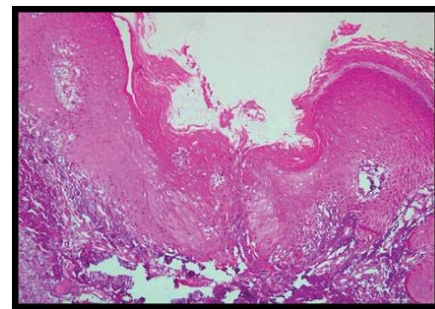


Figure 5: Skin biopsy from dorsum of the foot H & E stain (100x).

DISCUSSION

Reactive Perforating Collagenosis (RPC), first described by Mehregan et al. in 1967, is a type of essential perforating disorders.¹ It is characterized by transepidermal elimination of altered dermal substances. The elimination takes place by the upward movement of regenerating keratinocytes. In RPC, there is transepidermal elimination of altered collagen. The pathogenesis of RPC is unknown. As originally postulated by Mehregan et al., “mild superficial trauma in genetically susceptible persons leads to necrobiosis of collagen in dermal papillae, which is subsequently eliminated from the dermis by means of transepithelial elimination,” still seems to be correct. In RPC, the defect occurs in papillary dermis where histochemically altered but ultra-structurally intact type - IV collagen is present,² which is surrounded and engulfed by focal epidermal proliferation. A central crater containing inflammatory cells, keratinous material and altered collagen then develops and the altered collagen is subsequently expelled by transepithelial migration.¹ Lesions of RPC are intensely itchy, show Koebner's phenomena and mainly involve the extensor surface. Progressive itching leads to development of a skin-colored papule, which becomes umbilicated in 3-5 weeks and undergoes spontaneous regression in next 6-8 weeks, leaving a residual scar. At any given time, lesions may be seen in various stages of development. The important treatment options are topical retinoids, topical corticosteroids, intralesional steroids, Psoralen Ultra Violet-A (PUVA), Narrow Band UV-B (NBUB) and allopurinol.³⁻⁵

Funding: No funding sources

Conflict of interest: None declared

Ethical approval: Not required

REFERENCES

1. Mehregan AH, Schwartz OD, Livingood CS. Reactive perforating collagenosis. *Arch Dermatol*. 1967;96:277-82.
2. Herzinger T, Schirren CG, Sander CA, Jansen T, Kind P. Reactive perforating collagenosis - transepidermal elimination of type 4 collagen. *Clin Exp Dermatol*. 1996;21:279-82.
3. Cullen S. Successful treatment of reactive perforating collagenosis with tretinoin. *Cutis*. 1979;23:187-91.
4. Morton CA, Henderson IS, Jones MC, Lowe JG. Acquired perforating dermatosis in a British dialysis population. *Br J Dermatol*. 1996;135:671-7.
5. Hoque SR, Ameen M, Holden CA. Acquired reactive perforating collagenosis: four patients with a giant variant treated with allopurinol. *Br J Dermatol*. 2006;154:759-62.

DOI: 10.5455/2349-3933.ijam20140512

Cite this article as: Dhillon KS, Fatima U, Singh I, Singh T, Gupta T, Varshney KR, Sharma R. Reactive perforating collagenosis. *Int J Adv Med* 2014;1:49-51.