

## Case Report

# Cavernous haemangioma of cervix mimicking malignancy: a case report and review of the literature

Parveen Rana Kundu<sup>1\*</sup>, Sunita Siwach<sup>2</sup>, Kalpana Beniwal<sup>1</sup>, Vijeta<sup>2</sup>

<sup>1</sup>Department of Pathology, BPS Government Medical College for Women, Khanpur Kalan, Sonapat-124001, Haryana, India

<sup>2</sup>Department of Obstetrics & Gynaecology, BPS Government Medical College for Women, Khanpur Kalan, Sonapat-124001, Haryana, India

**Received:** 7 July 2014

**Accepted:** 19 July 2014

### \*Correspondence:

Dr. Parveen Rana Kundu,

E-mail: kundupvk@rediffmail.com

**Copyright:** © the author(s), publisher and licensee Medip Academy. This is an open-access article distributed under the terms of the Creative Commons Attribution Non-Commercial License, which permits unrestricted non-commercial use, distribution, and reproduction in any medium, provided the original work is properly cited.

### ABSTRACT

Haemangiomas are defined as benign neoplasm arising from blood vessels, either in internal organs or in the skin. There are two types of haemangioma: capillary and cavernous. Capillary haemangioma is usually seen at the top layer while cavernous is often found at deeper layer. These are characterized by abnormal accumulation or growth of blood vessels filled with blood. The cavernous haemangiomas occur less frequently than the capillary ones. These are usually soft to touch. Although some haemangiomas involve large portion of body, most are localized. The majority of lesions are superficial, often of head and neck, but can occur internally. The internal organs mostly affected are liver, spleen, pancreas, GIT, skin, uterus and sometimes the brain. The cervical localization is low. Most of cervical haemangiomas are incidental findings and show asymptomatic behaviour. They sometimes may cause abnormal vaginal bleeding as menorrhagia, metrorrhagia or post coital bleeding and dyspareunia. The most common differential diagnosis include cervical malignant tumor. The treatment is the surgical excision.

**Keywords:** Cavernous haemangioma, Cervix, Capillary, Malignancy

### INTRODUCTION

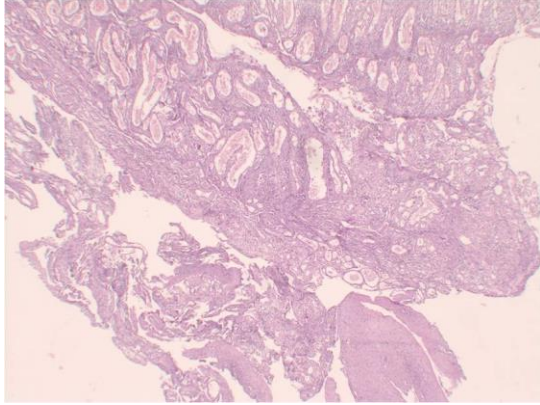
Haemangioma are benign neoplasm arising from blood vessels, either in internal organs or in the skin. There are two types of haemangioma: capillary and cavernous.<sup>1</sup> The cavernous haemangioma occur less frequently than the capillary ones. The uterine cervix localization is very rare. Till date less than 50 cases have been reported.<sup>2</sup> Most of cervical haemangioma are incidental findings and show asymptomatic behaviour. The most common differential diagnosis include cervical malignant tumor. The anatomopathological study proves it benign and vascular nature.<sup>3</sup> We present a case of 50 years old postmenopausal woman who reported in the outpatient department with history of infrequent episodes of bleeding for the duration of the last six months; the histopathology of which proved it to be the cavernous

haemangioma. This cavernous haemangioma of cervix was clinically mimicking malignancy in view of its large size and polypoidal growth. The updated review of the literature is also being discussed (Table 1).

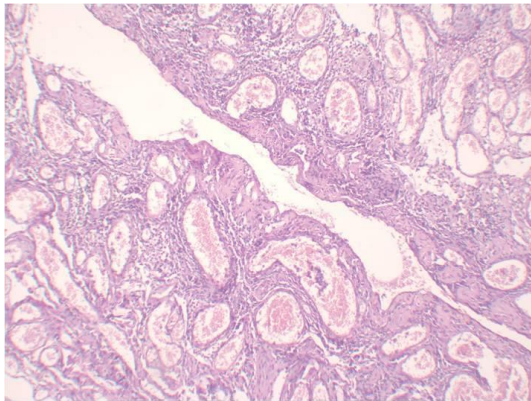
### CASE REPORT

A 50 years old postmenopausal women present at our out-door patient department with complaints of episodes of infrequent episodes of painless bleeding for the last six months. She had normal menstrual history. She had four normal delivered and last child birth was 12 years back. Her physical examination and vital were unremarkable. Per speculum examination showed a spongy vascular growth having from the cervical region, fresh vaginal bleeding was present.

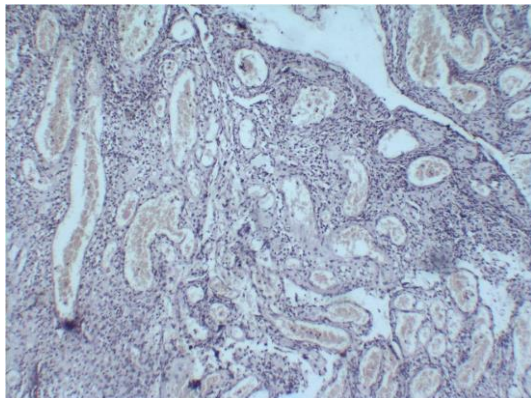
Per vaginal examination revealed uterus of normal size, firm, non-tender mobile with fornices free. A mass was felt arising from the endo-cervical canal. After routine investigation excisional biopsy was done and sent for histopathology. The post-operative period was uneventful. The histopathological analysis revealed cavernous haemangioma of cervix (Figure 1, 2 and 3).



**Figure 1: Polypoidal growth showing blood filled spaces along with stratified squamous epithelium (Haematoxylin and Eosin 40x).**



**Figure 2: Stromal tissue showing blood filled spaces (Haematoxylin and Eosin 100x).**



**Figure 3: Stromal tissue showing dilated capillaries filled with blood along with inflammatory infiltrate (Haematoxylin and Eosin 400x).**

## DISCUSSION

Haemangioma are very common tumors characterized by increased number of normal and abnormal vessels filled with blood and they are difficult to distinguish by vascular malformation. Uterine cervix cavernous haemangioma is a rare benign vascular tumor primarily superficial and/or deep dilated blood vessels. Other internal organs being affected are liver, spleen, pancreas, GIT, uterus, brain etc.<sup>4</sup>

Cavernous haemangioma differs from capillary in that they are less well circumscribed larger and deep in submucosal tissues. Less is known about the aetiopathogenesis of these mesenchymal tumors. According to Batsakis cavernous type is result of either a trauma or a congenital malformation. Hereditary factors may play a role in pathogenesis of some familial form of these tumors.<sup>5</sup> Grey scale & Doppler shows a well-defined, uniformly hypoechoic lesion with peripheral feeder vessel which are pathogenesis of haemangioma.<sup>6</sup>

The Table 1 reports the cases of haemangioma associated with pregnancy, post coital bleeding or asymptomatic pathology. Like this case; the most of the reported cases presented with post coital bleeding. These lesions were suspected malignant clinically although cervical haemangioma are generally asymptomatic; 35% of cases presented as menometrorrhagia or post coital metrorrhagia. The age ranges from 12-52 years.<sup>7</sup>

Surgical excision is curative in most of the cases, but because of its haemorrhagic risk, conservative therapies have been suggested as sclerosing agents, cryotherapy, CO<sub>2</sub> laser excision. In order to preserve the fertility in young patients, local excision, conisation or laser ablation can done. Embolization treatment for A-V malformation was crowned in patients presenting with serious menorrhagia for symptomatic relief and to preserve reproduction. If necessary they can be treated by hysterectomy.<sup>8</sup> Tanaka et al. reported spontaneous regression of the lesion.<sup>9</sup>

The diagnosis of cavernous haemangioma is histological. Histologically mass is shapely defined and not encapsulated and composed of large cavernous blood filled vascular spaces separated by modest connective tissue stroma. Intravascular thrombosis with associated dystrophic calcification is common. Histological differential diagnosis includes benign lesion having vascular component of reactionary nature like pyogenic granulomas or botryomycosis granulomas. However its lobulated character and abundant inflammatory infiltrate favour most of a reactionary lesion.<sup>10</sup>

A few cases associated with pregnancy are reported. Changes during pregnancy under hormonal influences can cause obstetrical complication like premature rupture of membrane, premature labour, fetal death, Post-Partum Haemorrhage (PPH) and Disseminated Intravascular

Coagulation (DIC).<sup>11</sup> Although delivery by natural way is possible but caesarean section is recommended to avoid

serious consequences. Uterine atony or DIC can be observed which can lead to hysterectomy.

**Table 1: Review of various cases of the uterine cervix cavernous haemangioma in the literature.<sup>7</sup>**

Review of various cases of the uterine cervix cavernous haemangioma		
Brand Foss RT	1955	54 years women presenting with painless vaginal bleeding.
Ahern	1978	Patient found to have cervical haemangioma on ultrasound, managed in a conservative way.
Jackson	1993	Cervical haemangioma is diagnosed in an asymptomatic multiparous woman or during pregnancy, expectant management is warranted.
Petry	1994	31-year old multiparous woman in the 34 + 1 gestational week, who presented herself with a fast growing cervical haemangioma, indicates that this benign tumor may cause obstetrical complications.
Padmanabhan	2001	Oral Contraceptive Pills related cervical haemangioma and focal nodular hyperplasia of the liver.
Riggs	2003	Patient presented intractable bleeding after Medical termination of pregnancy. Required hysterectomy on Histopathology-cavernous haemangioma.
Kondi-Pafiti	2003	9 unusual vascular tumors of the female genital tract and to investigate the problems in the differential diagnosis from other genital lesions. A capillary haemangioma of the endometrium, one capillary and one cavernous haemangioma of the cervix, 6 vulva lesions (one capillary, and one cavernous haemangioma and 4 angiokeratomas) and one haemangiosarcoma of the mons pubis in a 76-year-old patient were diagnosed. The differential diagnosis of the vascular tumors must be made mainly from endometriotic lesions and melanomas. Immunohistochemistry (S-100, CD31, CD34, CKS, EMA) aid in the Diagnosis. Local excision is appropriate for the benign vascular lesions.
Baxi	2005	Haemangioma of the cervix was found in a 60-year-old female patient with prolapse of uterus. The haemangioma was incidentally detected during routine histopathological examination of the organ removed by surgery.
Wang	2005	Examination of a 39-year-old patient presenting pelvic pain revealed a noticeable pelvic mass consisting of a 10 cm tumor extending from the cervix to the retro peritoneum. The pathology report demonstrated spindle cell haemangioma. This is a rare case of spindle cell haemangioma of the cervix after transvaginal resection.
Ozyer	2006	Reported a case of cavernous haemangioma of the cervix in a 53-year-old patient complaining about postcoital spotting.
Tanaka	2007	The Patient has BRBNS, haemangioma of the uterine cervix appeared during pregnancy. Caesarean section was performed without complications, One month after delivery, cervical haemangiomas were found to have decreased in size.
El Khateb	2008	25-year old multiparous patient in the 33-34 gestational weeks for premature labor with membranes rupture. A 3 cm × 6 cm soft regular purplish red mass is found in the uterine cervix. Caesarean has been made for tumor previa interference. The tumor excision has been made through the vagina after caesarean.
Reggiani Bonetti	2009	3 cases of haemangioma of the cervix in asymptomatic women, diagnosed as cavernous haemangioma. All tumors were immunoreactive for CD31, CD34, and factor-VIII-related antigen. Focal expression of estrogen receptors was detected. No positivity was obtained with progesterone receptor antibodies. The presence of estrogen receptor in the endothelial cells of the haemangioma of the cervix suggests a direct role of this hormone in the haemangioma development. A possible target therapy is discussed.
Dahiya et al	2011	43 years female presenting with post coital bleeding.

## CONCLUSION

Though uterine cervix cavernous haemangioma is a rare pathology, it may cause abnormal vaginal bleeding in the form of menometrorrhagia, post-coital bleeding or post-menopausal.<sup>12</sup> Its differential diagnosis is difficult due to its rarity but one should always keep its possibility in a women proceeding with vaginal bleeding. The final diagnosis can only be made by histopathology.

*Funding: No funding sources*

*Conflict of interest: None declared*

*Ethical approval: Not required*

## REFERENCES

1. Boyd W. Haemangioma. In: Boyd W, eds. Text Book of Pathology. 6th ed. Philadelphia: Lea & Febiger; 1953: 327.

2. Sebnem Ozyer, Ozlem Uzunlar, Muhammet Gocmen, Suleyman Bal, Levent Srwan, Leyla Mollamahmutoğlu. Cavernous haemangioma of cervix: a rare cause of vaginal bleeding. *J Low Genit Tract Dis.* 2006 Apr;10(2):107-8.
3. Gupta R, Singh S, Nigam S, Khurana N. Benign vascular tumors of the female genital tract. *Int J Gynaecol Cancer.* 2006;16:1195-200.
4. Gusdon JP. Haemangioma of the cervix four new cases and a review. *Am J Obstet Gynaecol.* 1965;91:204-9.
5. Batsakis JG. Chapter 1. In: Batsakis JG, eds. *Tumour of the Head & Neck: Clinical and Pathological Considerations.* 2nd ed. Baltimore: Williams & Wilkins; 1978: 1-75.
6. Paltiel HJ, Burrows PE, Kosakewich HP, Zurakowski D, Mulliken JB. Soft-tissue vascular anomalies: utility of US for diagnosis. *Radiology.* 2000;214(3):747-54.
7. Ozyer S, Uzunlar O, Gocmen M, Bal S, Srwan L, Mollamahmutoğlu L. Cavernous haemangioma of the cervix: a rare cause of vaginal bleeding. *J Low Genit Tract Dis.* 2006;10(2):107-8.
8. Wang YC, Chen CH, Su HY, Li HS, Liu JY. Huge spindle cell haemangioma of the cervix-mimicking a pelvic tumor. *Gynaecol Obstet Invest.* 2005;60(2):98-101.
9. Tanaka N, Tsuda M, Samura O, Miyoshi H, Hara T, Kudo Y. Blue rubber bleb nevus syndrome: report of a patient with haemangiomas of the vaginal portion of the cervix appearing during pregnancy. *J Obstet Gynaecol Res.* 2007;33(4):546-8.
10. Kondi-Pafiti A, Kairi-Vassilatou E, Spanidou-Carvouni H, Kontogianni K, Dimopoulou K, Goula K. Vascular tumors of the female genital tract: a clinicopathological study of nine cases. *Eur J Gynaecol Oncol.* 2003;24(1):48-50.
11. Riggs J, Bertoni M, Schiavello H, Weinstein A, Kazimir M. Cavernous haemangioma of the cervix with intractable bleeding: a case report. *J Reprod Med.* 2003;48(9):741-3.
12. Dahiya N, Dahiya P, Kalra R, Marwah N, Jain S. Cavernous haemangioma of uterine cervix: a rare cause of post coital bleeding. *Int J Pharmaceut Sci Res.* 2011;2(5):1209-11.

DOI: 10.5455/2349-3933.ijam20140809

**Cite this article as:** Kundu PR, Siwach S, Beniwal K, Vijeta. Cavernous haemangioma of cervix mimicking malignancy: a case report and review of the literature. *Int J Adv Med* 2014;1:158-61.