

Case Report

Multiple extragastrointestinal stromal tumors: a case report

Jamila Alagarsamy*, Valarmathi Kadhivel, Chandramouleeswari Kathirvel,
Arun Hemavathy, Mary Lilly

Department of Pathology, Stanley Medical College, Chennai, Tamil Nadu, India

Received: 22 July 2014

Accepted: 16 August 2014

***Correspondence:**

Dr. Jamila Alagarsamy,

E-mail: drjamilarose@yahoo.com

Copyright: © the author(s), publisher and licensee Medip Academy. This is an open-access article distributed under the terms of the Creative Commons Attribution Non-Commercial License, which permits unrestricted non-commercial use, distribution, and reproduction in any medium, provided the original work is properly cited.

ABSTRACT

Gastro-Intestinal Stromal Tumor (GIST) is a non-epithelial, mesenchymal tumor. They most commonly originate from the stomach or small intestine, but in rare examples they involve the omentum in this article, we are reporting a case of multiple extragastrointestinal stromal tumour of the omentum, peritoneum and mesentery which was diagnosed cytologically and confirmed by histopathology and immunohistochemistry.

Keywords: Extragastrointestinal stromal tumour, Omentum, Peritoneum, Mesentery, DOG-1 marker

INTRODUCTION

Gastro-Intestinal Stromal Tumor (GIST) is a non-epithelial, mesenchymal tumor. They most commonly originate from the stomach or small intestine, rarely in the omentum.

The term GIST was first used in 1983 by Mazur and Clark to encompass gastrointestinal non-epithelial neoplasms that lacked the immunohistochemical features of Schwann cells and did not have the ultrastructural characteristics of smooth muscle cells.¹ Gastrointestinal stromal tumour is a mesenchymal neoplasm in which the line of differentiation recapitulates the cells of Cajal and has a broad spectrum of biological behavior. They express CD117, a c-kit proto-oncogene protein, and show gain of function mutation of c-kit gene that encodes a growth factor receptor with tyrosine kinase activity.²

Extra-Gastrointestinal Stromal Tumour (EGIST) is histologically and immunohistochemically similar to their gastrointestinal counterpart but they have an aggressive course resembling small intestinal stromal tumors and they have no or little connection to the abdominal wall or

serosal surface of the gastrointestinal tract.³ Mesenchymal tumours of omentum, mesentery and retroperitoneum with immunohistochemical features of the GISTs are classified as extragastrointestinal stromal tumors because these organs have no connection with the wall of the gastrointestinal tract. The incidence of EGISTS is less than 10% of the GISTs group³ and because of their rarity, clinicopathologic and immunohistochemical features of EGISTS are not fully elucidated.³

CASE REPORT

A 65 year female presented with complaints of abdominal pain, vomiting and abdominal lump for 2 months duration. Clinical and laboratory examination showed no significant abnormalities. Imaging modalities, including computed tomography and magnetic resonance imaging reveals a large heterogenous soft tissue mass lesion with foci of calcification noted with air pockets and necrotic areas and size of around 10.9x9.8x11.3 cm in the pelvis (Figure 1). Upper gastrointestinal endoscopy shows normal gastric mucosa. Scope was passed upto terminal ileum which shows normal mucosal study.

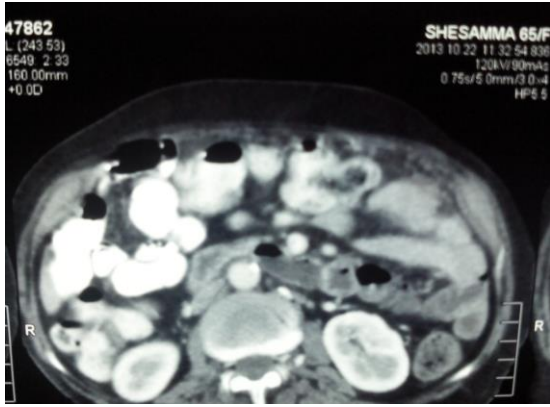


Figure 1: CT picture, large heterogenous soft tissue mass lesion with foci of calcification, air pockets and necrotic areas measuring 10.9x9.8x11.3 cm in the pelvis.

Laparotomy was done and found that well defined mass lesions of variable size and consistency were found arising from the mesentery behind urinary bladder, above uterus and above the ovaries. Largest mass measuring 15x10x6 cm and smallest measuring 2x2x1 cm with restricted mobility. Antimesenteric surface of ileum was almost merging with the mass lesion with impending obstruction. About 200 ml of hemoperitoneum was found. Entire surface of peritoneum, small bowel mesentery and colon were nodular. Omental mass imprint cytology was done and sent for cytology.

Imprint cytology revealed a cellular smear composed of round to polygonal pleomorphic cells in diffuse sheets with abundant eosinophilic cytoplasm and hyperchromatic nuclei. Focal clusters of spindle shaped cells were also seen in a hemorrhagic background (Figure 2). Impression was given as smear positive for malignancy with following possible differential diagnosis. Adenocarcinomatous deposit/malignant extragastrintestinal stromal tumour (Epithelioid type).

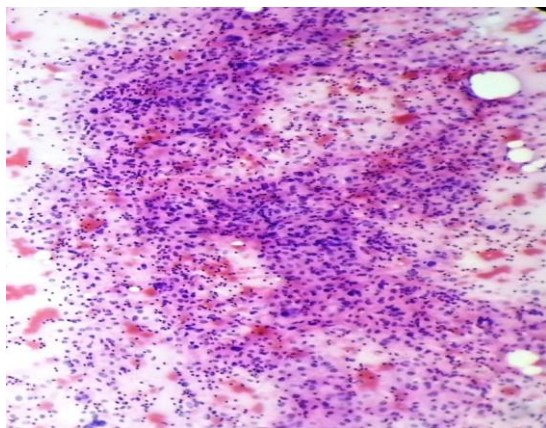


Figure 2: Imprint cytology showing a cellular smear composed of dispersed round, polygonal and spindle shaped cells with moderate degree of pleomorphism and hyperchromatic nuclei.

Subsequently patient was treated with side to side ileoileal anastomosis and omental biopsy taken. Omental biopsy was measuring 2.5x2x1 cm. in size. External surface was irregular. Cut surface showed a grey white lesion. Microscopic examination showed a neoplasm composed of fascicles of epithelioid cells having moderate eosinophilic cytoplasm with centrally placed round to oval nuclei separated by fibrous stroma admixed with congested blood vessels. High cellularity, a high mitotic count (>5/ 50 hpf) and marked nuclear atypia suggested the high risk nature of the tumour. However, necrosis was absent. A diagnosis of malignant epithelioid extragastrintestinal stromal tumour was made (Figure 3).

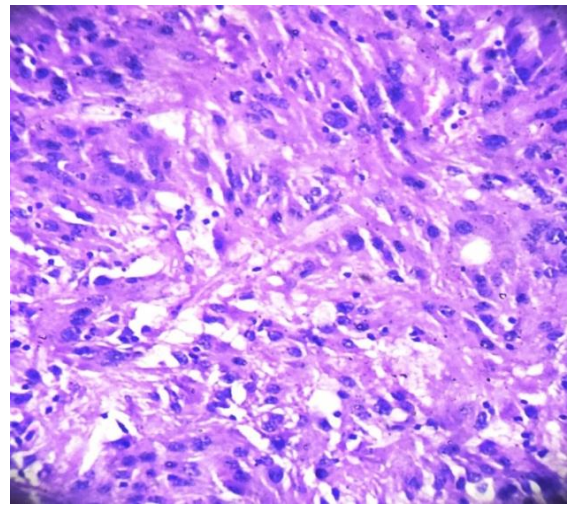


Figure 3: Histopathology exhibiting tumour cells with epithelioid morphology, pleomorphism and mitosis arranged in fascicular pattern.

Immunohistochemical staining demonstrated positive staining with DOG 1 antibody in the tumour cell cytoplasm (Figure 4). Postoperative period was uneventful and the Patient was started on imatinib.

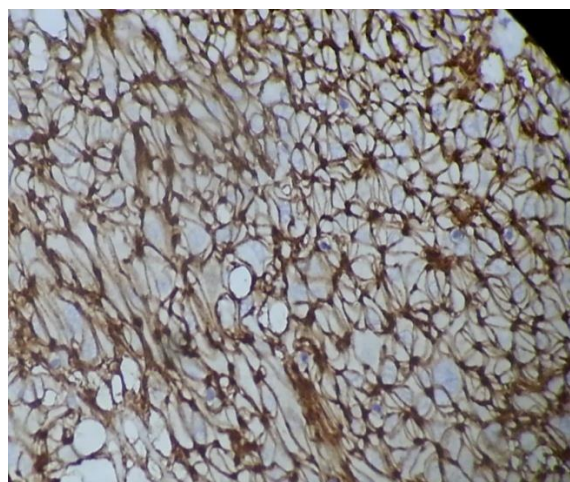


Figure 4: Immunohistochemistry showing membrane and cytoplasmic positivity for DOG 1.

DISCUSSION

Extra-gastrointestinal stromal tumour is a rare stromal tumour that occurs outside the GIT and comprises about 5-7% of all the GISTs.⁴ Most of the EGIST cases are located in the mesentery, omentum and retroperitoneum.^{3,5} There are rare cases of EGIST localization in the posterior mediastinum, liver, gallbladder, pancreas, urinary bladder, inguinal hernia sac, scrotum, uterus, fallopian tube and rectovaginal septum.⁶⁻¹⁰

EGISTs are histologically and immunohistochemically similar to their gastrointestinal counterparts but are rare and have an aggressive course. Their histogenesis is said to be from the interstitial cells of Cajal, as these cells express CD-117. EGISTs also show positivity for CD-34 in 50% of the cases. A recent observation that the interstitial cells of Cajal do not express CD34 whereas the fibroblasts of Auerbach's plexus do, suggests that the stromal tumours may display hybrid features.¹¹

The tumours which present as multiple nodules are usually metastatic from primary GIST and are confused with peritoneal carcinomatosis.¹² In our case, the tumour presented as multiple nodules and there was no evidence of any primary tumour in the gastrointestinal tract.

The main differential diagnoses which were considered in the present case were fibromatosis, smooth muscle tumours, neural tumours and malignant fibrous histiocytomas.

The distinction from fibromatosis is made primarily on the basis of morphology. Fibromatosis has low cellularity and it is composed of spindle cells lying in a collagenous stroma. Necrosis and mitotic activity is absent. Also, mesenteric fibromatoses are usually negative for CD-117.¹³ Smooth muscle tumours and neural tumours are differentiated from EGISTs on the basis of both morphology and immunohistochemistry. Both of these tumours are negative for CD-117.¹⁴

The Storiform pattern of the tumour might be confused with that of Malignant Fibrous Histiocytoma (MFH). But, there was an absence of giant cells and CD-117 positivity favoured the diagnosis of EGIST.

When first detected, many cases of EGISTs can be accessed by a Fine Needle Aspiration Biopsy (FNAB) or imprint cytology. In our case, we performed a cytological diagnosis on imprint and the result was highly suspicious for the diagnosis of extragastrointestinal stromal tumor. Although GISTs primary in the gastrointestinal tract commonly metastasize to the omentum and mesentery, often as multiple nodules, GISTs may also occur as primary tumors outside of the gastrointestinal tract proper in other intra-abdominal locations, especially in the omentum and mesentery.

These tumors are composed of either purely rounded epithelioid cells (predominantly) or short fusiform cells in a fine fibrillary collagenous background. Rarely, mixed pattern is also encountered. Similar to GISTs, EGISTs also display varying amounts of stromal hyalinization, myxoid change and cyst formation. However skeinoid fibers, a common marker in GIST of the small bowel, are absent in this tumor.

DOG-1 (Discovered on GIST 1) has proved to be sensitive and specific for the diagnosis of GISTs when compared with C-kit, including cases of extragastrointestinal and metastatic GIST. DOG-1 expression was membranous and cytoplasmic. Immunohistochemistry in this case has shown diffuse positivity for DOG-1 marker.

This case emphasises that though it is a rare tumour, EGIST must be considered in the differential diagnosis of the mesenchymal tumours and that immunohistochemistry should be done to confirm the diagnosis. The prognostic values of the different parameters need to be discussed and each case must be followed properly. The behaviour of these tumours varies from being benign to highly malignant and so the correct assessment of the behaviour of the tumour is a must for the proper management of the patient.

Funding: No funding sources

Conflict of interest: None declared

Ethical approval: Not required

REFERENCES

1. Mazur MT, Clark HB. Gastric stromal tumors: Reappraisal of histogenesis. *Am J Surg Pathol.* 1983;7:507-19.
2. Hirota S, Isozaki K, Moriyama Y, Hashimoto K, Nishida T, Ishiguro S, et al. Gain-of-function mutations of C-kit in human gastrointestinal stromal tumours. *Science.* 1998 Jan;279(5350):577-80.
3. Reith JD, Goldblum JR, Lyles RH, Weiss SW. Extragastrointestinal stromal tumours: an analysis of 48 cases with emphasis on histologic predictors of outcome. *Mod Pathol.* 2000;13(5):577-85.
4. Yamamoto H, Oda Y, Kawaguchi K, Nakamura N, Takahira T, Tamiya S, et al. C-kit and PDGFRA mutations in extragastrointestinal stromal tumour (gastrointestinal stromal tumour of the soft tissue). *Am J Surg Pathol.* 2004;28(4):479-88.
5. Miettinen M, Monihan JM, Sarlomo-Rikala M, Kovatich AJ, Carr NJ, Emory TS, et al. Gastrointestinal stromal tumours/smooth muscle tumours (GISTs) primary in the omentum and mesentery: clinico-pathologic and immunohistochemical study of 26 cases. *Am J Surg Pathol.* 1999;23(9):1109-18.
6. Lee JR, Anstadt MP, Khwaja S, Green LK. Gastrointestinal stromal tumour of the posterior

- mediastinum. *Eur J Cardiothorac Surg.* 2002;22:1014-6.
7. Hu X, Forster J, Damjanov I. Primary malignant gastrointestinal stromal tumour of the liver. *Arch Pathol Lab Med.* 2003;127:1606-8.
 8. Yamaura K, Kato K, Miyazawa M, Haba Y, Muramatsu A, Miyata K, et al. Stromal tumour of the pancreas with expression of C-kit protein: report of a case. *J Gastroenterol Hepatol.* 2004;19:467-70.
 9. Krokowski M, Jocham D, Choi H, Feller AC, Horny HP. Malignant extragastrointestinal stromal tumour of bladder. *J Urol.* 2003;169(5):1790-1.
 10. Wingen CB, Pauwels PA, Debiec-Rychter M, van Gemert WG, Vos MC. Uterine gastrointestinal stromal tumour (GIST). *Gynecol Oncol.* 2005;97(3):970-2.
 11. Vanderwinden JM, Rumessen JJ, DeLaet MH, Vanderhaeghen JJ, Schiffmann SN. CD34+ cells in human intestine are fibroblasts adjacent to, but distinct from, interstitial cells of Cajal. *Lab Invest.* 1999;79:59-65.
 12. Sinha R, Verma R, Kong A. Mesenteric Gastrointestinal Stromal tumour in a patient with neurofibromatosis. *AJR.* 2004;183:1844-6.
 13. Weiss SW, Goldblum JR. Fibromatoses. In: Enzinger FM, Weiss SW, eds. *Soft Tissue Tumours.* 5th ed. St. Louis: Mosby; 2008: 247-249.
 14. Gupta N, Mittal S, Lal N, Misra R, Kumar L, Bhalla S. A rare case of primary mesenteric gastrointestinal stromal tumour with metastasis to the cervix uteri. *World J Surg Oncol.* 2007;5:137.

DOI: 10.5455/2349-3933.ijam20140823

Cite this article as: Alagarsamy J, Kadirvel V, Kathirvel C, Hemavathy A, Lilly M. Multiple extragastrointestinal stromal tumors: a case report. *Int J Adv Med* 2014;1:176-9.