

Case Report

Stewart-Treves syndrome: a rare entity

K. S. Dhillon^{1*}, Deepak Sharma¹, Uroos Fatima², Isha Singh¹, Nikha Garg¹, Tarunveer Singh¹,
Tanu Gupta¹, Nawed Khan¹

¹Department of Dermatology, Era's Lucknow Medical College, Lucknow, Uttar Pradesh, India

²Department of Pathology, Era's Lucknow Medical College, Lucknow, Uttar Pradesh, India

Received: 01 October 2014

Accepted: 13 October 2014

*Correspondence:

Dr. K. S. Dhillon,

E-mail: kanwarjit29@yahoo.co.in

Copyright: © the author(s), publisher and licensee Medip Academy. This is an open-access article distributed under the terms of the Creative Commons Attribution Non-Commercial License, which permits unrestricted non-commercial use, distribution, and reproduction in any medium, provided the original work is properly cited.

ABSTRACT

Stewart-Treves syndrome is a rare, deadly cutaneous angiosarcoma that develops in long - standing chronic lymphedema. Most commonly, this tumor is a result of lymphedema induced by radical mastectomy to treat breast cancer. Stewart-Treves syndrome occurs in 0.5% of patients, who survive mastectomy for more than 5 years. The mean age at appearance of the angiosarcoma is 62 years, and the mean interval between mastectomy and the appearance of the tumor is 10.5 years. The exact pathogenesis is not known so far. On histopathology, vascular channels infiltrate the normal structures in a disorganized fashion, as if trying to line every available tissue space with a layer of endothelial cells. The prognosis is poor as it is very aggressive. Only early diagnosis and prompt radical excision with or without adjuvant radiotherapy, can promote survival.

Keywords: Stewart-Treves syndrome, Angiosarcoma, Chronic lymphedema

INTRODUCTION

Stewart-Treves syndrome is a kind of angiosarcoma associated with chronic lymphedema.¹⁻³ It was first reported by Stewart and Treves,⁴ in 1948. The exact mechanism of Stewart-Treves syndrome is not clear so far. It may be however, due to the accumulation of protein-rich interstitial fluid in a chronically swollen limb.⁵ The prognosis of Stewart-Treves syndrome has been regarded as poor due to its aggressiveness. Wide excision is the only known curative treatment option for the localized disease, and there is no known effective therapy for the metastatic disease.⁶ Thus, only early diagnosis and prompt radical excision with or without adjuvant radiotherapy, can promote survival.

CASE REPORT

A 42-year-old female presented with swelling of left leg of 5 years duration superimposed with multiple ulcerative nodular lesions (Figure 1). Patient was apparently asymptomatic 5 years back, when she started developing

swelling over her left leg. It was accompanied by constitutional symptoms periodically. Swelling of left leg gradually increased over a period. She consulted various medical practitioners, but her symptoms continued to persist. Since past 5 months, the swelling in left leg suddenly increased with multiple nodules developing over calf and adjoining area. They rapidly increased in size emanating foul smelling serosanguinous discharge. The nodules were covered with black to brown colored necrotic crust. The nodules size varied from 2 cm × 3 cm to the largest size of 8 cm × 10 cm. The crusts over the nodule were extremely friable and the bled on touch. Popliteal and inguinal lymphadenopathy was present. On histopathology, vascular channels infiltrated the deeper layers of skin in a disorganized fashion (Figure 2). CD34 immunohistochemistry highlighted the vascular nature of angiosarcomas (Figure 3).

DISCUSSION

More than 400 cases of angiosarcoma related to chronic lymphedema have been reported so far in English literature.⁷

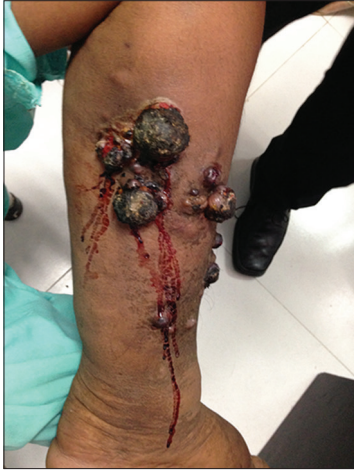

Figure 1: Ulcerative nodules on left leg.

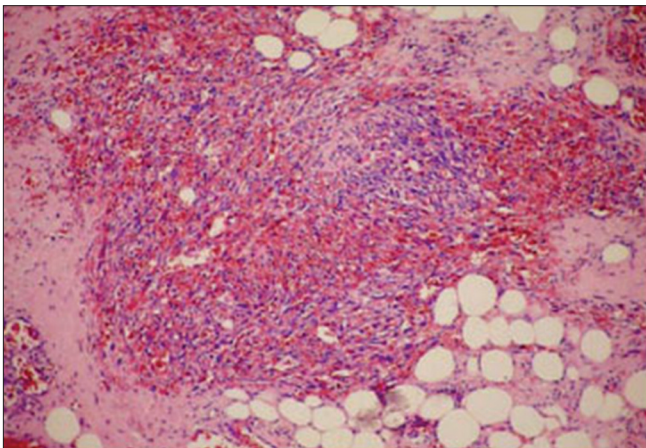


Figure 2: Vascular lesion of small-vessel inter-anastomotic with fusicellular cells presenting intense atypias infiltrating adipose tissue.

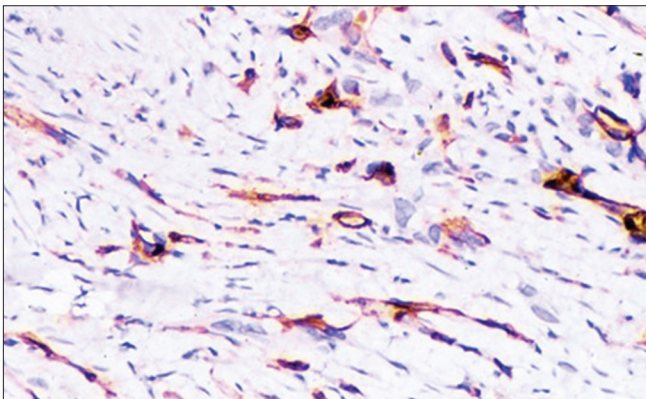


Figure 3: CD34 immunohistochemistry highlights the vascular nature of angiosarcomas.

Cutaneous angiosarcoma arising in chronic lymphedema after filarial infection is very rare. Muller et al.⁸ has reported three cases of a similar nature. Sordillo et al.,⁹ Sinclair et al.,¹⁰ Hallel-Halevy et al.¹¹ and Komorowski et al.¹² have also reported cases of angiosarcoma in long-standing elephantiasis.

Clinically, angiosarcoma can present as a simple bruise that resembles hemangioma to large nodular or ulcerative lesion. The exact mechanism of Stewart-Treves syndrome is not clear. It may be due, however, to the accumulation of protein-rich interstitial fluid in a chronically swollen limb. This fluid alters the local immune environment of the chronically edematous limb and promotes lymphangiogenesis. The presence of lymphangiomatosis is a precursor lesion for angiosarcoma, which was seen in our case. Even though immunohistochemistry is confirmatory, histopathological examination is the mainstay for diagnosis. The mean survival period of this disease has been quoted to be 7 months, with an overall 5 years survival rate of approximately 35%.¹³

Funding: No funding sources

Conflict of interest: None declared

Ethical approval: Not required

REFERENCES

1. Gonne E, Collignon J, Kurth W, Thiry A, Henry F, Jerusalem G, et al. Angiosarcoma in chronic lymphoedema: a case of Stewart-Treves syndrome. *Rev Med Liege.* 2009;64(7-8):409-13.
2. Schwartz RA. Kaposi's sarcoma. In: Schwartz RA, editor. *Skin Cancer: recognition and Management.* New York, NY: Springer Verlag; 1988: 80-8.
3. Sharma A, Schwartz RA. Stewart-Treves syndrome: pathogenesis and management. *J Am Acad Dermatol.* 2012;67(6):1342-8.
4. Stewart FW, Treves N. Lymphangiosarcoma in postmastectomy lymphedema: a report of six cases in elephantiasis chirurgica. *Cancer* 1948;1:64-81.
5. McHaffie DR, Kozak KR, Warner TF, Cho CS, Heiner JP, Attia S. Stewart-Treves syndrome of the lower extremity. *J Clin Oncol.* 2010;28(21): e351-2.
6. Abraham JA, Hornicek FJ, Kaufman AM, Harmon DC, Springfield DS, Raskin KA, et al. Treatment and outcome of 82 patients with angiosarcoma. *Ann Surg Oncol.* 2007;14(6): 1953-67.
7. Schmitz-Rixen T, Horsch S, Arnold G, Peters PE. Angiosarcoma in primary lymphedema of the lower extremity – Stewart-Treves syndrome. *Lymphology.* 1984;17(2):50-3.
8. Muller R, Hajdu SI, Brennan MF. Lymphangiosarcoma associated with chronic filarial lymphedema. *Cancer.* 1987;59(1):179-83.
9. Sordillo EM, Sordillo PP, Hajdu SI, Good RA. Lymphangiosarcoma after filarial infection. *J Dermatol Surg Oncol.* 1981;7(3):235-9.
10. Sinclair SA, Sviland L, Natarajan S. Angiosarcoma arising in a chronically lymphoedematous leg. *Br J Dermatol.* 1998;138(4):692-4.
11. Hallel-Halevy D, Yerushalmi J, Grunwald MH, Avinoach I, Halevy S. Stewart-Treves syndrome in a patient with elephantiasis. *J Am Acad Dermatol.* 1999;41:349-50.

12. Komorowski AL, Wysocki WM, Mitus J. Angiosarcoma in a chronically lymphedematous leg: an unusual presentation of Stewart-Treves syndrome. *South Med J.* 2003;96(8):807-8.
13. Young RJ, Brown NJ, Reed MW, Hughes D, Woll PJ. Angiosarcoma. *Lancet Oncol.* 2010;11(10):983-91.

DOI: 10.5455/2349-3933.ijam20141116

Cite this article as: Dhillon KS, Sharma D, Fatima U, Singh I, Garg N, Singh T, Gupta T, Khan N. Stewart-Treves syndrome: a rare entity. *Int J Adv Med* 2014;1:282-4.