

Original Research Article

Superficial fungal infections in end stage renal disease patients

Upma Narain^{1*}, Arvind Gupta²

¹Department of Microbiology, Tejas Microdiagnostics, Allahabad, Uttar Pradesh, India

²Department of Nephrology, Moti Lal Nehru Medical College, Allahabad, Uttar Pradesh, India

Received: 04 September 2016

Accepted: 03 October 2016

*Correspondence:

Dr. Upma Narain,

E-mail: upmanarain@gmail.com

Copyright: © the author(s), publisher and licensee Medip Academy. This is an open-access article distributed under the terms of the Creative Commons Attribution Non-Commercial License, which permits unrestricted non-commercial use, distribution, and reproduction in any medium, provided the original work is properly cited.

ABSTRACT

Background: Patients with end stage renal disease commonly present a spectrum of dermatological disorders. Each one has its own unique presentation and treatment approaches. Superficial fungal infections of the skin do not account for much in the end stage renal disease patients; hence most of the reports do not discuss this issue. In the present study we analysed patients with end stage renal disease who had developed superficial fungal infections.

Methods: During January 2015 to June 2016, we tried to analyse 150 patients with end stage renal disease, who developed superficial fungal infections and were undergoing haemodialysis at least thrice a week for a minimum of three months at our centre.

Results: Out of the 150 suspected cases we identified, 36 cultures tested positive. The macroscopic examination of the scalp, skin and the nails revealed 2.2% *Tinea capitis*, 13.9% *Tinea versicolor*, 44.5% *Tinea corporis*, 8.4% *Tinea manuum*, 16.8% onychomycosis, 5.7% *Tinea cruris* and 8.5% *Tinea pedis*. The culture examination highlighted 44.4% *Trichophyton rubrum*, 27.8% *Trichophyton mentagrophyte*, 2.8% *Trichophyton violaceum*, 2.8% *Trichophyton verrucosum*, 2.8% *Microsporum canis*, 2.8% *Epidermophyton floccosum*, 2.8% *Scopulariopsis brevicaulis* and 13.8% *Malassezia*). The predominant clinical abnormality observed was *Tinea corporis* and the prevalent fungal isolate was *Trichophyton rubrum*.

Conclusions: The current study illustrates that a significant number of patients with the end stage renal disease had a prevalence of superficial fungal infections; hence, a prompt recognition of skin lesions and the identification of these superficial fungi may alarm us so that early and the judicious management to reduce the associated morbidity and in turn to improve the quality of life in these patients is taken.

Keywords: Dermatophytes, End stage renal disease, Superficial fungal infections, Tinea

INTRODUCTION

Patients with end stage renal disease (ESRD) suffer from a multitude of symptoms with very low quality of life accompanied by a particularly high prevalence of dermatological disorders.¹ Uremia is associated with a state of immune dysfunction characterized by immunodepression that likely contributes to the high prevalence of infections among these patients.² Superficial mycoses are prevalent worldwide. Superficial fungal infections

arise from a pathogen that is restricted to the stratum corneum, with little or no tissue reaction.³ The host's immune response against infections caused by dermatophytes basically depends on the host's defence against metabolites of the fungi, virulence of the infecting strain of species and anatomical site of the infection.⁴ Much has been reported about the cutaneous changes and invasive fungal infections among these patients but dedicated description of superficial fungal infections lack in literature. Thus the aim of this study is to evaluate the

prevalence of superficial fungal infections in ESRD patients at our centre.

METHODS

This retrospective study included 150 suspected cases of fungal infections undergoing haemodialysis at least thrice a week for a minimum of three months at our centre. Dermatological evaluation and confirmation of the presenting lesions were done by the dermatologist. In all cases, data related to the age, sex, duration of the lesions, occupation, personal habits etc. was noted. After a detailed clinical examination, the physical features of the scalp, skin and nails were recorded. A lot of care was particularly taken to record the past history of superficial mycotic infections.

Before obtaining a specimen, the infected areas were cleansed by swabbing them liberally with alcohol to eliminate as many bacteria as possible, because they can overgrow and inhibit the growth of dermatophytes. Scrapings and clippings were collected from the diseased portions of the scalp, skin and nails. When both the skin and the nails were affected, specimens were collected from both the sites.

Each specimen was divided into two parts; one was taken for direct microscopic examination after 10% KOH solution treatment and the second was inoculated on sabouraud dextrose agar (M286) and sabouraud cycloheximide chloramphenicol agar (M664). Two successive cultures were performed to establish the colonization of the pathogen because successive sampling rarely demonstrates the same contaminant. Cultures were routinely incubated at 25–30° C and examined daily for up to 4 weeks. The identification of the individual fungi was based on standard methods such as microscopy, morphology, colonial characterization and pigment production, rate of growth and biochemical test.⁵

RESULTS

A total of 150 clinically suspected cases of superficial fungal infections were undertaken for mycological studies during the period spanning from Jan 2015 to June 2016 at our centre. The base line and the demographic data of all 150 patients are summarized (Table 1).

Out of a total of 150 suspected cases of superficial mycosis, 36 cases were culture positive; the rest 114 cases did not show any fungal growth on culture media after an incubation period of 4 weeks hence they were considered as negative. A complete illustration of Tinea infections, the spectrum of lesions and spectrum of fungal isolates of the 36 culture positive cases are depicted in (Figure 1), (Figure 2) and (Figure 3) respectively. Culture isolates in relation to the site of involvement are shown (Table 2). For the 36 Culture Positive patients the predominant clinical abnormality observed was Tinea corporis and the prevalent fungal isolate was

Trichophyton rubrum. The duration of the lesions varied from one month to 4 months but a majority of these cases were of less than two month duration.

Table 1: Demographic features.

Demographic features	
Age	59.19±9.099
Gender	Male 115 (76.7%) Female 35 (23.3%)
Haemodialysis vintage (months)	21.01±8.045
Primary diagnosis	
Diabetes	82 (54.7%)
Glomerulonephritis	44 (29.3%)
Hypertension	20 (13.3%)
Unknown	4 (2.7%)
Laboratory test	
Kt/V*	1.2±0.1
S. creatine (mg/dl)	5.4±0.3
S. albumin (g/dl)	3.2±0.4
Haemoglobin (g/dl)	10.0±1.0
BUN (mg/dl)	40.0±2.0

*Values expressed in mean±SD. Kt/V parameter used for measurement of the adequacy of haemodialysis treatment.

The macroscopic examination of the scalp, skin and the nails of these 36 patients further revealed 2.2% Tinea capitis, 13.9% Tinea versicolor, 44.5% Tinea corporis, 8.4% Tinea mannum, 16.8% onychomycosis, 5.7% Tinea cruris and 8.5% Tinea pedis. Culture examinations revealed 44.4% *Trichyopyton rubrum*, 27.8% *Trychophyton mentagrophyte*, 2.8% *Trychophyton violaceum*, 2.8% *Trichophyton verrucosum*, 2.8% *Microsporum canis*, 2.8% *Epidermophyton flucossum*, 2.8% *Scopulariopsis brevicaulis* and 13.8% *Mallessesia*.

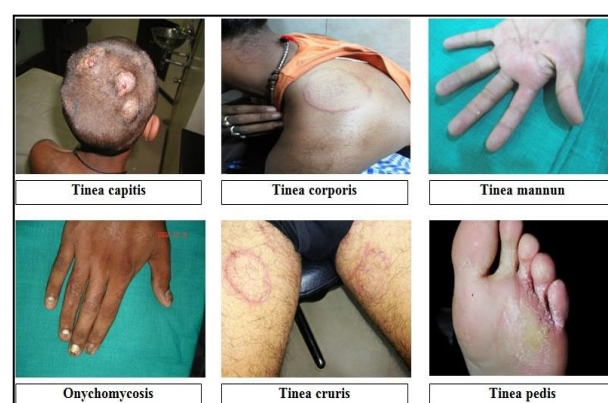

Figure 1: Different sites of superficial fungal infections in patients with ESRD.

As for the remaining 114 culture negative cases, the macroscopic examination of the scalp, skin and the nails revealed 7.1% Tinea capitis, 11.4% Tinea versicolor, 15.8% Tinea corporis, 17.5% Tinea mannum, 34.2% onychomycosis, 8.7% Tinea cruris and 5.3% Tinea pedis.

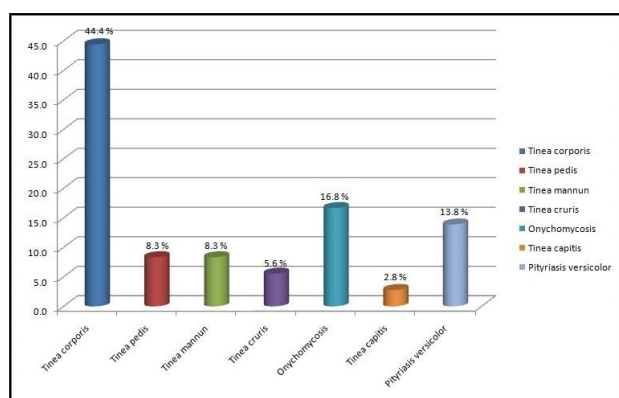


Figure 2: Spectrum of superficial fungal infections in patients with ESRD.

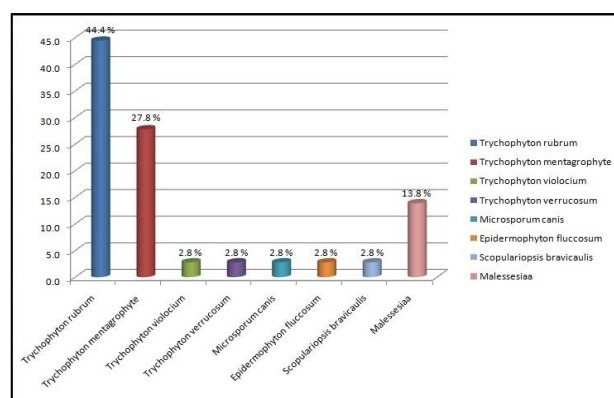


Figure 3: Spectrum of fungal isolates in patients with ESRD.

Table 2: Culture isolates in relation to the site of involvement.

Fungus	Cutaneous Infection							Total
	<i>Tinea corporis</i>	<i>Tinea pedis</i>	<i>Tinea mannum</i>	<i>Tinea cruris</i>	<i>Onycho-mycosis</i>	<i>Tinea capitis</i>	<i>Pityriasis versicolor</i>	
<i>Trychophyton rubrum</i>	10 27.8%	2 5.6%	3 8.3%	0 0.0%	1 2.8%	0 0.0%	0 0.0%	16 44.4%
<i>Trychophyton mentagrophyte</i>	6 16.7%	1 2.8%	0 0.0%	1 2.8%	2 5.6%	0 0.0%	0 0.0%	10 27.8%
<i>Trychophyton violocium</i>	0 0.0%	0 0.0%	0 0.0%	0 0.0%	1 2.8%	0 0.0%	0 0.0%	1 2.8%
<i>Trychophyton verrucosum</i>	0 0.0%	0 0.0%	0 0.0%	1 2.8%	0 0.0%	0 0.0%	0 0.0%	1 2.8%
<i>Microsporum canis</i>	0 0.0%	0 0.0%	0 0.0%	0 0.0%	0 0.0%	1 2.8%	0 0.0%	1 2.8%
<i>Epidermophyton fluccosum</i>	0 0.0%	0 0.0%	0 0.0%	0 0.0%	1 2.8%	0 0.0%	0 0.0%	1 2.8%
<i>Scopulariopsis bravicaulis</i>	0 0.0%	0 0.0%	0 0.0%	0 0.0%	1 2.8%	0 0.0%	0 0.0%	1 2.8%
<i>Mallesesia</i>	0 0.0%	0 0.0%	0 0.0%	0 0.0%	0 0.0%	0 0.0%	5 13.8%	5 13.8%
Total	16 44.4%	3 8.3%	3 8.3%	2 5.6%	6 16.8%	1 2.8%	5 13.8%	36 100.0%

DISCUSSION

Superficial mycoses are common in tropical countries. Superficial fungal infections arise from a pathogen that is restricted to the stratum corneum, with little or no tissue reaction.³ The host immune response against infections caused by the dermatophytes depends on factors such as the host defences against metabolites of the fungus, the virulence of the infecting strain or species, the anatomical site of infection and local environmental factors.⁴

Out of a total of 150 suspected cases of superficial mycosis, 36 cases were culture positive; the rest 114 cases did not show any fungal growth on culture media

after an incubation period of 4 weeks. The possible reasons for a negative fungus culture might be the following: the presence of non-viable hyphae elements in the distal region of the diseased nail and in the margins of the skin lesions, an uneven colonization of lesion with the fungus and an antifungal treatment had been used prior to the collection of the specimen. Low culture positivity rate was also reported in previous studies, in 2004 and 2005, the MRL received 5312 and 5137 dermatology specimens, respectively, of which 2321 (45%) and 2277 (43%) were positive by direct microscopy, 1538 (30%) and 1553 (29%) were positive by culture and 1430 (28%) and 1415 (27%) were positive by both microscopy and culture.⁶

In the present study, a macroscopic examination of scalp, skin and nails for the 36 culture positive patients revealed 2.2% *Tinea capitis*, 13.9% *Tinea versicolor*, 44.5% *Tinea corporis*, 8.4% *Tinea mannum*, 16.8% onychomycosis, 5.7% *Tinea cruris* and 8.5% *Tinea pedis*. The culture examination for these patients revealed 44.4% *Trichyopyton rubrum*, 27.8% *Trychophyton mentagrophyte*, 2.8% *Trychophyton violaceum*, 2.8% *Trichophyton verrucosum*, 2.8% *Microsporum canis*, 2.8% *Epidermophyton flucossum*, 2.8% *Scopulariopsis brevicaulis* and 13.8% *Malassezia*. Hence, for the first time from India, we are reporting superficial fungal infections in patients with ESRD.

In ESRD, uremia is associated with immune-suppression due to the impact of uremic milieu and a variety of associated disorders exerted on immunocompetent cells. Hypercytokinemia is a typical feature of uremia, likely due to accumulation of pro-inflammatory cytokines as a consequence of decreased renal elimination and/or increased generation following induction by uremic toxins, oxidative stress, volume overload, comorbidities etc.⁷⁻⁸

Susceptibility to dermatophytes is variable and may be related to the variations in the composition of sebum, fatty acids, skin surface, carbon dioxide tension, presence of moisture or presence of inhibitors for the growth of dermatophytes in sweat or serum such as transferrin.⁹⁻¹⁰

Factors related to the fungus also contribute to the development of infection. Dermatophytes are able to penetrate keratinized cells by producing enzymes such as keratinases. *Trichophyton mentagrophyte* has two enzyme isotypes. *Malassezia* species produce lipases which may aid in the digestion of fats in sebum. The Fungi that cause nail diseases do not all produce keratinases and some appear to be able to invade the nail plate only if there is a pre existing abnormality, such as peripheral vascular disease, trauma etc. Therefore, small changes in the host defence are important for allowing organisms to invade the skin.¹¹

Virulence factors of dermatophytes contribute to the modulation of the host immune response and can be expressed throughout the whole infectious process.¹²⁻¹³ Several studies suggested that the immunosuppressive properties of the mannans was responsible for the chronicity of dermatophytosis especially caused by *Trichophyton rubrum* and was less inflammatory in individuals with impaired functions of T lymphocytes.¹⁴

Different dermatophyte species vary in their ability to stimulate an immune response: organisms such as *Trichophyton rubrum* cause chronic or relapsing infections, whereas other fungi induce resistance to re-infection.¹⁵⁻¹⁶ In our study two patients exhibited *Tinea corporis* lesions caused by *Trichophyton rubrum* during the period of one year. Thus, the fungus/host interaction exerts influence on the degree of inflammatory reaction

which will define the clinical presentation and duration of the lesion in these patients.

CONCLUSION

The present study illuminates the findings that a noticeable number of patients with the end stage renal disease had a prevalence of superficial fungal infections, therefore, prompt recognition of these skin lesions and the identification of these superficial fungi may increase our awareness so that early and judicious management to reduce the associated morbidity and in turn improve the quality of life in these patients can be taken.

Funding: No funding sources

Conflict of interest: None declared

Ethical approval: The study was approved by the institutional ethics committee

REFERENCES

1. Shafiee MA, Akbarian F, Memon KK, Aarabi M, Boroumand B. Dermatologic Manifestations in End-stage Renal Disease. IJKD. 2015;9:339-53.
2. Kato S, Chmielewski M, Honda H, Pecoits-Filho R, Matsuo S, Yuzawa Y, et al. Aspects of Immune Dysfunction in End-stage Renal Disease. Clin J Am Soc Nephrol. 2008;3(5):1526-33.
3. Schwartz RA. Superficial fungal infections. The Lancet. 2004;364:1173-82.
4. Criado PR, Dantas KC, Benini LV, Oliveira CB, Takiguti FA, Vasconcellos C. Superficial mycosis and the immune response elements. An Bras Dermatol. 2011;86(4):726-31.
5. Narain U, Gupta A. Peritoneal Dialysis Related Candida Peritonitis: A 16-year Single-Centre Experience. Arch Clin Microbiol. 2016;7:2.
6. Borman AM, Campbell CK, Fraser M, Johnson EM. Analysis of the dermatophyte species isolated in the British Isles between 1980 and 2005 and review of worldwide dermatophyte trends over the last three decades. Medical Mycology. 2007;45:131-41.
7. Kimmel PL, Phillips TM, Simmens SJ, Peterson RA, Weihs KL, Alleyne S, et al. Immunologic function and survival in hemodialysis patients. Kidney Int. 1998;54:236-44.
8. Stenvinkel P, Ketteler M, Johnson RJ, Lindholm B, Pecoits-Filho R, Riella M, et al. IL-10, IL-6, and TNF-alpha: central factors in the altered cytokine network of uremia—the good, the bad, and the ugly. Kidney Int. 2005;67:1216-33.
9. Calderon RA. Immunoregulation in dermatophytosis. Crit Rev Microbiol. 1989;16:339-68.
10. King RD, Khan HA, Foye JC, Greenberg JH, Jones HE. Transferrin, iron, and dermatophytes. I. Serum dermatophyte inhibitory component definitively identified as unsaturated transferrin. J Lab Clin Med. 1975;86:204-12.

11. Hay RJ. *Fungi and Skin Disease*. London: Gower Medical Publishing. 1993.
12. Hay RJ, Calderon RA, Mackenzie CD. Experimental dermatophytosis in mice: correlation between light and electron microscopic changes in primary, secondary and chronic infections. *Br J Exp Pathol*. 1988;69:703-16.
13. Acorci-Valério MJ, Bordon-Graciani AP, Dias-Melicio LA, Golim MA, Nakaira-Takahagi E, Soares AMVC. Role of TLR2 and TLR4 in human neutrophil functions against *Paracoccidioides brasiliensis*. *Scand J Imm*. 2010;71:99-108.
14. Mignon B, Tabart J, Baldo A, Mathy A, Losson B, Vermout S. Immunization and dermatophytes. *Curr Opin Infect Dis*. 2008;21:134-40.
15. MacGregor JM, Hamilton A, Hay RJ. Possible mechanisms of immune modulation in chronic dermatophytosis - an in vitro study. *Br J Dermatol*. 1992;127:233-8.
16. Vermout S, Tabart J, Baldo A, Mathy A, Losson B, Mignon B. Pathogenesis of dermatophytosis. *Mycopathologia*. 2008;166:267-75.

Cite this article as: Narain U, Gupta A. Superficial fungal infections in end stage renal disease patients. *Int J Adv Med* 2016;3:1043-7.