

## Original Research Article

# Histopathological study of ovarian lesions in a tertiary care center in Hyderabad, India: a retrospective five-year study

Akina Prakash\*, Sravan Chinthakindi, Ramanan Duraiswami, Indira V.

Department of Pathology, Malla Reddy Institute of Medical Sciences, Suraram, Hyderabad, Telangana, India

**Received:** 05 April 2017

**Accepted:** 06 April 2017

**\*Correspondence:**

Dr. Akina Prakash,

E-mail: [akina.p.p@gmail.com](mailto:akina.p.p@gmail.com)

**Copyright:** © the author(s), publisher and licensee Medip Academy. This is an open-access article distributed under the terms of the Creative Commons Attribution Non-Commercial License, which permits unrestricted non-commercial use, distribution, and reproduction in any medium, provided the original work is properly cited.

### ABSTRACT

**Background:** The aim of the study was to identify the pattern of pathologies involving ovarian mass lesions which were received for histopathological evaluation at a tertiary hospital in Hyderabad, Telangana, India during the period January 2012 to December 2016.

**Methods:** The data pertaining to samples of ovarian lesions received for histopathological evaluation at the laboratory of a tertiary care hospital in Hyderabad from January 2012 to December 2016, were analyzed to determine the pattern of pathologies diagnosed during such evaluation and the age distribution of all lesions.

**Results:** Non-neoplastic lesions of the ovary constituted 44.0% of all cases received; follicular cysts constituted 45.5% of these lesions. Malignant lesions constituted only 2.0% of all pathologies. Serous cystadenoma of the ovary constituted the predominant neoplastic lesion diagnosed (62.5% of all neoplastic lesions). 53.2% of patients whose samples were received belonged to the age group of 20-39 years. 90.8% of the lesions were unilateral

**Conclusions:** The majority of ovarian lesions received for evaluation were benign and unilateral. Most patients were in the third to sixth decades of life.

**Keywords:** Follicular cysts, Incidence of pathologies, Ovarian mass lesions, Serous cystadenoma

### INTRODUCTION

Ovarian lesions are unusual because of their diverse morphology and association with relatively mild symptoms. Neoplastic disorders can arise from (1) mullerian epithelium, (2) germ cells or (3) sex cord stromal cells.<sup>1</sup> Tumors of the ovary are a common neoplasm in women.<sup>2</sup> The most common lesions encountered in the ovary are functional or benign cysts and tumors.<sup>3</sup> Ovarian cancer is the sixth most common female cancer and is seen predominantly after the third decade of life.<sup>4</sup> Ovarian neoplasms are usually detected at a late stage and are large in size, because of their presentation with mild symptoms.<sup>5</sup> An accurate and early diagnosis of malignant lesions will go a long way in optimal management of these cases.

### METHODS

The study was undertaken as a retrospective systematic study using existing patient data retrieved from the records of the Department of Pathology, Malla Reddy Institute of Medical Sciences.

During the period from January 2012 to December 2016, 229 ovarian mass specimens were received for evaluation, either as solitary specimens, or as part of total abdominal hysterectomy (TAH) specimens.

All samples were received from the operation theater in buffered formol saline as per protocols given in the Standard Operating Procedure (SOP) for Histopathology of the Hospital. Samples were grossed on the same day

that they were received, after ensuring adequate tissue fixation.

Tissue slices were taken and processed as per SOP. Microsections of 5 microns thickness were taken onto glass slides and stained by standard Hematoxylin and Eosin stains as per protocols. After mounting and labeling, all slides were viewed by at least two Pathologists before final reporting. All lesions were classified using WHO guidelines.

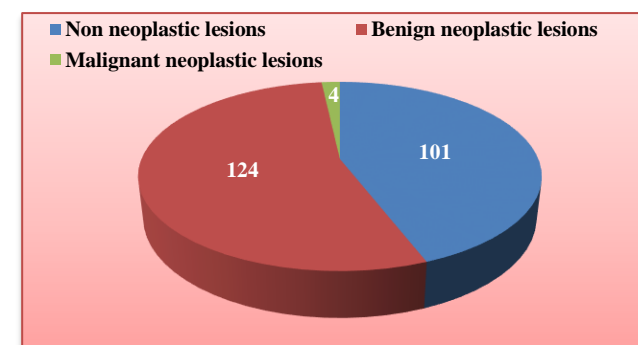
For the purpose of this study, all records pertaining to the study period were retrieved. Details of the histopathological diagnoses of the ovarian masses evaluated, as well as the age distribution of the patients, were analyzed. All patient data were kept confidential. Data was analyzed using an MS Excel worksheet and calculations of incidence made from the same.

**RESULTS**

A total of 229 samples of ovarian masses were received for histopathological evaluation at our Hospital, a tertiary care hospital located in Hyderabad in Telangana, India. Of these, 208 masses were unilateral (90.8%) and 21 were bilateral (9.2%). The age-wise distribution of the patients whose samples were received is given in Table 1. Patients in the age group of 20-39 years constituted the majority of patients (122 out of 229; 53.4%).

**Table 1: Age wise distribution of patients operated for ovarian masses.**

| Age in years | Number of patients (total=229) | Patients (%) |
|--------------|--------------------------------|--------------|
| <19          | 13                             | 5.7%         |
| 20-39        | 122                            | 53.4%        |
| 40-59        | 84                             | 36.6%        |
| >60          | 10                             | 4.3%         |

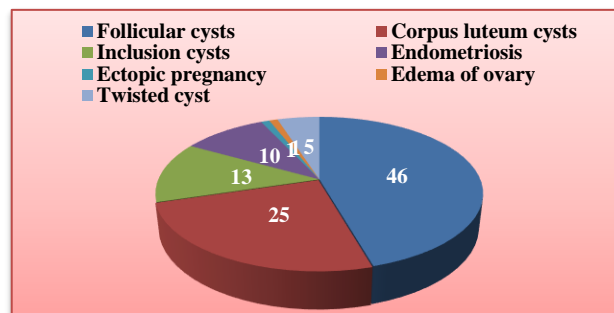


**Figure 1: Distribution of lesions based on histopathological diagnoses (total- 229).**

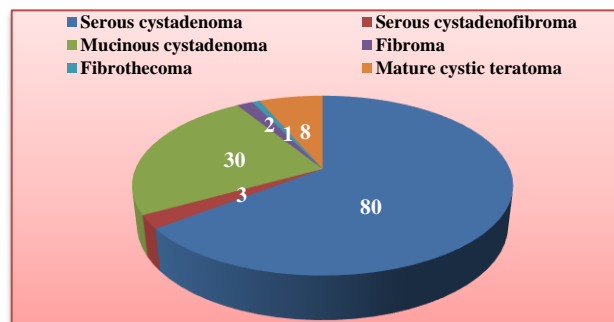
The lesions were broadly classified as non - neoplastic lesions, benign neoplastic lesions and malignant neoplastic lesions. The distribution of the cases amongst

these broad categories is given in Figure 1. Benign neoplastic lesions constituted the majority of lesions diagnosed (124 out of 229 cases; 54%).

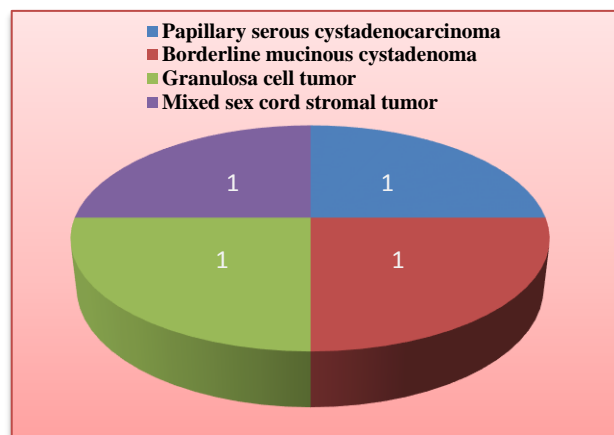
The distribution of lesions that were diagnosed as non - neoplastic is given in Figure 2. Follicular cysts were the predominant non - neoplastic lesions diagnosed (46 out of 101;45.5%) followed by corpus luteum cysts (25 out of 101; 25%). The distribution of lesions diagnosed as benign neoplastic lesions as per WHO guidelines is given in Figure 3.



**Figure 2: Distribution of non-neoplastic lesions of ovaries (T=101).**

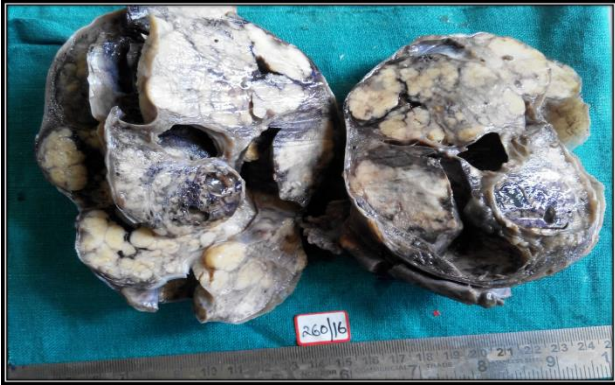

**Figure 3: Distribution of benign neoplastic lesions of ovaries (T=124).**

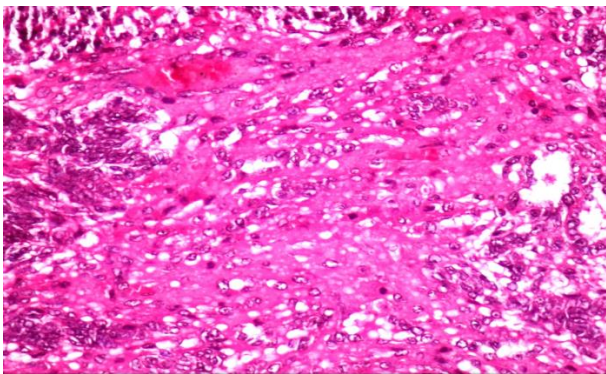


**Figure 4: Distribution of malignant neoplastic lesions of ovaries (T=4).**

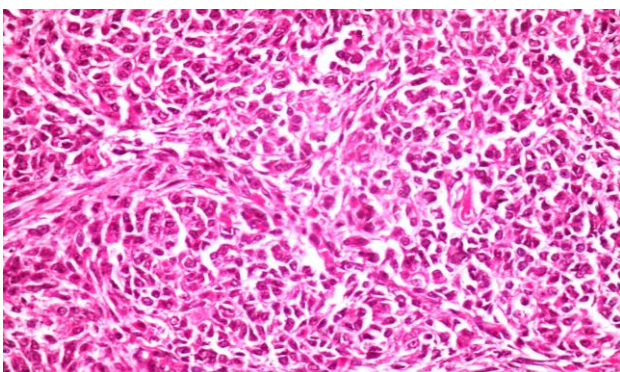
Serous cystadenomas were the most common lesion diagnosed (80 out of 124; 64.5% of benign neoplasia; 62.5% of all neoplastic lesions). Mucinous cystadenomas were the second most common benign neoplastic lesion diagnosed (30 out of 124; 24.2%).



**Figure 5: gross specimen of mixed sex cord stromal tumor showing a variegated appearance with solid and cystic areas along with areas of necrosis and haemorrhage.**



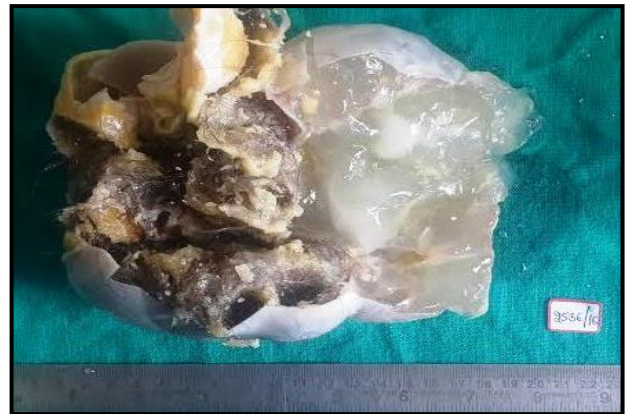**Figure 6: Sertoli-leydig cell component of mixed sex cord stromal tumor showing darkly stained sertoli cells and leydig cells with dense eosinophilic cytoplasm. (H and E,40X).**



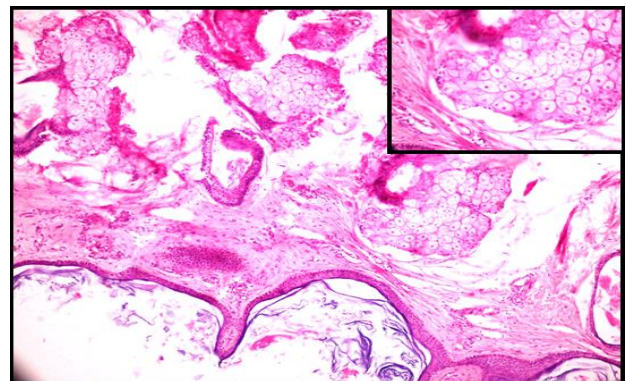
**Figure 7: Granulosa cell component of mixed sex cord stromal tumor with tumor cells arranged in sheets and nests, few of the nuclei have a coffee-bean appearance with grooves; few foci showing call-exner bodies (H and E,40 X).**

Only four malignant lesions were diagnosed, the distribution of which is given in Figure 4. The age of patients with these malignant tumors was:

- Mixed sex cord stromal tumor -26 years
- Mucinous cystadenoma with borderline malignancy - 35 years
- Granulosa cell tumor - 46 years
- Bilateral serous papillary cystadenocarcinoma - 56 years
- The histopathological pattern of various tumors encountered during our study is shown in the microphotographs in Figures 5 - 9.



**Figure 8: Cut section of benign cystic teratoma of ovary showing cystic spaces filled with hair, pultaceous and mucoid material.**



**Figure 9: Low power view of benign cystic teratoma showing cyst wall lined by keratin material and sebaceous glands (H and E, 10X); inset showing high power view of sebaceous glands (H and E,40X)**

## DISCUSSION

Typically, ovarian masses consist of functional and pathological lesions.<sup>6</sup> Given the location of these paired organs and the mildness of symptoms associated with lesions arising in them, these lesions usually attain a fairly large size before they are detected and removed.<sup>5,7</sup> Ovarian lesions are unusual because of their diverse morphology and association with relatively mild

symptoms. Neoplastic disorders can arise from (1) müllerian epithelium, (2) germ cells or (3) sex cord stromal cells.<sup>1</sup> Precise diagnosis of lesions of the ovary is a sine qua non-for optimal management of such lesions.<sup>8</sup> Laterality of ovarian neoplastic lesions in various studies in comparison with present study is illustrated in Table 2. Our study revealed that 208 out of 229 ovarian specimens were unilateral (90.8%) and only 21 (9.2%) were bilateral. Our findings are in concordance with other studies (Prabhakar and Kalyani-90.9% unilateral; Couto et al-91.25% unilateral 10; Thakkar and Shah- 88.4% unilateral).<sup>9,11</sup>

**Table 2: Laterality of ovarian neoplastic lesions in various studies in comparison with present study.**

| Authors         | Laterality |           |
|-----------------|------------|-----------|
|                 | Unilateral | Bilateral |
| Prabhakar et al | 90.9%      | 9.1%      |
| Misra et al     | 95.5%      | 4.5%      |
| Couto F et al   | 91.2%      | 8.7%      |
| Kar et al       | 73.13%     | 26.8%     |
| Present study   | 90.8%      | 9.2%      |

The percentage distribution of patients in various age groups in comparison with other studies is illustrated in Table 3. The majority of our patients were in the age group 20-39 years (122 patients, 53.4% of patients) while those in the age group 40-59 years were the second largest group of patients (84 patients, 36.6% of patients). This is in concordance with the studies of Ramachandran et al (20-39 years -53.0%; 40-59 years -30% of patients) and Pilli et al (20-39 years -58.0%; 40-59 years-30% of patients).<sup>12,13</sup> However, Thakkar and Shah found only 25.6% of their patients in the age group 20-39 years and 53.5% in the age group 40 - 59 years. Kar et al reported 46.25% of patients in the age group 40-59 years.<sup>14</sup>

**Table 3: Percentage distribution of cases in various age groups in comparison with present study.**

| Authors            | Age group in years |       |       |      |
|--------------------|--------------------|-------|-------|------|
|                    | 0-19               | 20-39 | 40-59 | >60  |
| Ramachandran et al | 7.9%               | 53%   | 30%   | 9.1% |
| Pilli et al        | 7%                 | 58%   | 30%   | 5%   |
| Kar et al          | 7.4%               | 41.7% | 46.2% | 4.4% |
| Present study      | 5.7%               | 53.4% | 36.6% | 4.3% |

In present study, 101 lesions were non -neoplastic (44.1% of all specimens evaluated]; 124 lesions in our study (54%) were benign neoplasms. In contrast, in the study by Zaman et al, 68.87% of the lesions were non -neoplastic and 31.13% were neoplastic.<sup>15</sup> Gurung et al found 43.7% non-neoplastic lesions in their study, and 51.1% benign tumors.<sup>16</sup> Follicular cysts were the most common non-neoplastic lesion in our study (45.5%) followed by corpus luteum cysts (25%). In contrast, Gurung et al found endometriotic cysts in 17% and corpus luteum cysts in 9.6% of their cases. Maliheh et al

found 57.1% of functional cysts and 5.9% of endometriotic cysts in their study.<sup>17</sup> Endometriotic cysts were seen in 10% of our cases.

Benign neoplastic lesions constituted 124 out of 128 neoplastic lesions in present study (96.8%). This percentage is much higher than other authors (Pachori et al 72.3%; Couto et al 80.76%; Pilli et al 76%; Thakkar and Shah 84.5%.<sup>7,10,11,13</sup> Serous cystadenomas were the most common benign neoplasm encountered in our study (64.5% of benign neoplastic lesions) followed by mucinous cystadenomas (24.2%). This is in agreement with other studies.<sup>11,16,18</sup> However, Yogambal et al reported serous cyst adenoma (21.4%) and mature cystic teratoma (19.9%) as the most common lesions in their study.<sup>19</sup> We had only four cases of malignant / borderline lesions in our study. The four malignant/borderline tumors were seen in four different decades of life and showed no age predilection. This reflects the wide clinical presentation of ovarian tumors. Given the small number of cases, no conclusions could be drawn from studying their frequency or distribution. We have not been able to elicit any reason for the low incidence of malignant neoplasms in our study.

## CONCLUSION

Study present findings of pathologies diagnosed on histopathological evaluation of ovarian mass lesions received during a five-year period from January 2012 to December 2016. Our distribution of benign neoplasms and non-neoplastic lesions was similar to other studies; however, we had a very small percentage of malignant/borderline lesions (3.2%) as compared to other studies. We propose a more detailed prospective study, to include genetic profiling, to establish the reason for this low incidence of malignant lesions in our dependent population.

*Funding: No funding sources*

*Conflict of interest: None declared*

*Ethical approval: The study was approved by the institutional ethics committee*

## REFERENCES

1. Modi D, Rathod GB, Delwadia KN, Goswami HM. Histopathological pattern of neoplastic ovarian lesions. *IAIM.* 2016;3(1):51-7.
2. Young RH. The ovary. In: Sternberg S. *Diagnostic Surgical Pathology.* 17th Ed. New York: Raven Press. 1994:2195.
3. Ellenson LH, Pirog EC. Ovaries. In: Robbins and Cotran- *Pathologic Basis of Disease.* South Asia Edition. New Delhi: Reed Elsevier India. 2014: 1022.
4. Tortolero L, Mitchell FM, Rhodes HE. Epidemiology and screening of ovarian cancer. *Obstet Gynecol Clin North Am.* 1994;21:63-75.

5. Bhattacharya MM, Shinde SD, Purandare VN. A clinicopathological analysis of 270 ovarian tumors. *J Postgrad Med.* 1980;26:103-7.
6. Forae GD, Aligbe JU. A histopathological overview of ovarian lesions in Benin City, Nigeria: How common is the functional cyst? *Int J Med Public Health.* 2014;4:265-8.
7. Pachori G, Meena US, Sunaria RK, Pachori P, Jethani N, Bayla T. Histopathological study of ovarian tumors in Ajmer region. *Int J Med Sci Public Health.* 2016;5:1400-3.
8. Rashid S, Sarwas G, Ali A. A clinicopathological study of ovarian cancer. *Mother Child.* 1998;36:117-25.
9. Prabhakar BR, Kalyani M. Ovarian tumors - prevalence in Punjab. *Indian J Pathol Microbiol.* 1989;32(4):276-81.
10. Couto F, Nadkarni NS, Rebello MJ. Ovarian tumors in Goa. A clinicopathological study. *J Obstet Gynecol of India.* 1993;43(3):408-12.
11. Thakkar NN, Shah SN. Histopathological study of ovarian lesions. *Int J Sci Research* 2015; 4(10):1745-9.
12. Ramachandran G, Harilal KR, Chinnamma K, Thangavelu H. Ovarian neoplasms -A study of 903 cases. *J Obstet Gynecol India.* 1972;22:309 -15.
13. Pilli GS, Sunitha KP, Dhaded AV, Yenni VV. Ovarian tumors - a study of 282 cases. *J Indian Med Associ.* 2002;100(7):420-4.
14. Kar T, Kar A, Mohapatra PC. Intra-operative cytology of ovarian tumors. *J Obstet Gynecol India.* 2005;55(4):345-9.
15. Zaman S, Majid S, Hussain M, Chughtai O, Mahboob J, Chughtai S. A retrospective study of Ovarian tumors and tumor - like lesions. *J Ayub Med Coll Abbottabad.* 2010;22(1):104-8.
16. Gurung P, Hirachand S, Pradhanang S. Histopathological study of ovarian cystic lesions. *J Inst Med.* 2013;35(3):44-7.
17. Maliheh A, Yasmin S. Surgical histopathology of benign ovarian cysts: a multicentric study. *Iranian J Pathology.* 2010;5(3):132-6.
18. Misra RK, Sharma SP, Gupta U, Gaur R, Misra SD. Pattern of ovarian neoplasms in eastern UP. *J Obstet Gynecol.* 1990;41(2):242-6.
19. Yogambal M, Arunalatha P, Chandramouleeswari K, Palaniappan V. Ovarian tumors - Incidence and distribution in a tertiary referral center in South India. *IOSR J Dent Med Sci.* 2014;13(2):1400-3.

**Cite this article as:** Prakash A, Chinthakindi S, Duraiswami R, Indira.V. Histopathological study of ovarian lesions in a tertiary care center in Hyderabad, India-a retrospective five-year study. *Int J Adv Med* 2017;4:745-9.