

Case Report

Recurrent self-healing painful ecchymoses and fever: a case of Gardner-diamond syndrome

Sachanidou M. G.,¹ Arampatzis G. D.¹, Zioga A.³, Gaitanis G.,^{1,2} Ioannis D. Bassukas^{1,2*}

¹Department of Skin and Venereal Diseases, Faculty of Medicine, School of Health Sciences, University of Ioannina, Ioannina, Greece

²Department of Dermatology, ³Department of Pathology Laboratory, University Hospital of Ioannina, Ioannina, Greece

Received: 19 December 2016

Accepted: 16 January 2017

*Correspondence:

Dr. Ioannis D. Bassukas,
E-mail: ibassuka@cc.uoi.gr

Copyright: © the author(s), publisher and licensee Medip Academy. This is an open-access article distributed under the terms of the Creative Commons Attribution Non-Commercial License, which permits unrestricted non-commercial use, distribution, and reproduction in any medium, provided the original work is properly cited.

ABSTRACT

Gardner - Diamond syndrome (GDS) is a rare recurrent condition of painful ecchymoses without apparent eliciting factors. We report a 40-year old woman with GDS without psychiatric comorbidity. She presented with, recurrent episodes of spontaneous, self-limiting crops of painful ecchymotic bruising and fever. Her medical history, physical and psychiatric examinations, a focused imaging work up and bone marrow biopsy were unremarkable; the skin biopsy excluded vasculitis. However, the erythrocyte auto-sensitization test was positive; a finding that together with history and clinico-laboratory results highly suggests GDS.

Keywords: Erythrocyte auto-sensitization test, Eryptosis, GDS

INTRODUCTION

Gardner - Diamond syndrome (GDS; synonyms: psychogenic purpura, autoerythrocyte sensitization syndrome, painful bruising syndrome) is seen predominantly in women and comprises painful ecchymoses without apparent eliciting factors.

Psychiatric background and autoreactivity to blood components are well known features of the disease, but the exact cause remains elusive.^{1,2}

The sporadic reporting of GDS is in contrast to the wide geographic distribution and variable underlying background of reported cases, pointing towards a spectrum of conditions that comprise this "by exclusion" diagnosis. Herein, we report a woman with recurrent episodes of spontaneous, painful ecchymotic bruising finally diagnosed with GDS.

CASE REPORT

A 40-year old woman was admitted to the Dermatology Department for spontaneous, symmetrical, edematous, painful bruises and ecchymotic purpuric lesions of her upper thighs, anterior shins and periorbitally [Figure 1(a)]. Fever (38.9°C) and cough heralded their appearance by three days. With the exception of the facial lesions, the patient reported three similar episodes the previous 16 years. On every occasion, no apparent eliciting factor, including physical trauma or stress could be identified and all episodes subsided within 15 days.

A cholecystectomy performed 3 years earlier did not elicit the clinical syndrome under investigation. Otherwise, medical history and physical examination were unremarkable. The patient was working in the family bakery and no underlying psychiatric signs could be discerned to warrant a specialist evaluation. Extensive

laboratory workout revealed increased white blood cell count (12.40x10³/μl, neutrophils: 85.4%), C-reactive-protein (13 mg/L, normal<6 mg/L) and erythrocyte sedimentation rate (29 mm/h). Additionally, fibrinogen, factors II and IX were significantly increased (542 mg/dl, 134% and 129% respectively) with normal values in prothrombin time and partial thromboplastin time. Focused laboratory [Widal-Wright, Rose-Bengal and Coombs tests, Interferon Gamma Release Assay (IGRA)] and imaging work up (chest-X-ray, chest and abdominal CT scan, abdominal ultrasound) were unremarkable. A lesional skin biopsy was non-diagnostic; however, vasculitis or granulomatous diseases were ruled out (Figure 2). Under the hypothesis of GDS an intradermal erythrocyte auto-sensitization test was performed and turned out positive [Figure 1 (c, b)].

unremarkable. She was discharged 3 days later without therapy and remains disease free during a 12-month follow-up.

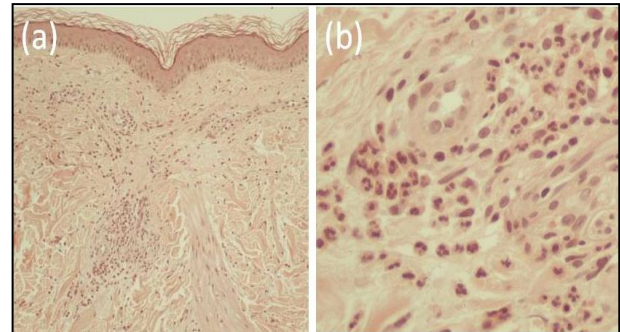


Figure 2: Lesional skin biopsy (5mm punch biopsy, the biopsy site at the right thigh as indicated in Figure 1, Panel a) shows dense neutrophilic dermal infiltrate that surrounds dilated blood vessels with endothelial swelling but without any signs of vasculitis (Hematoxylin-Eosin; Panel a: original magnification x100, Panel b: detail, x400).

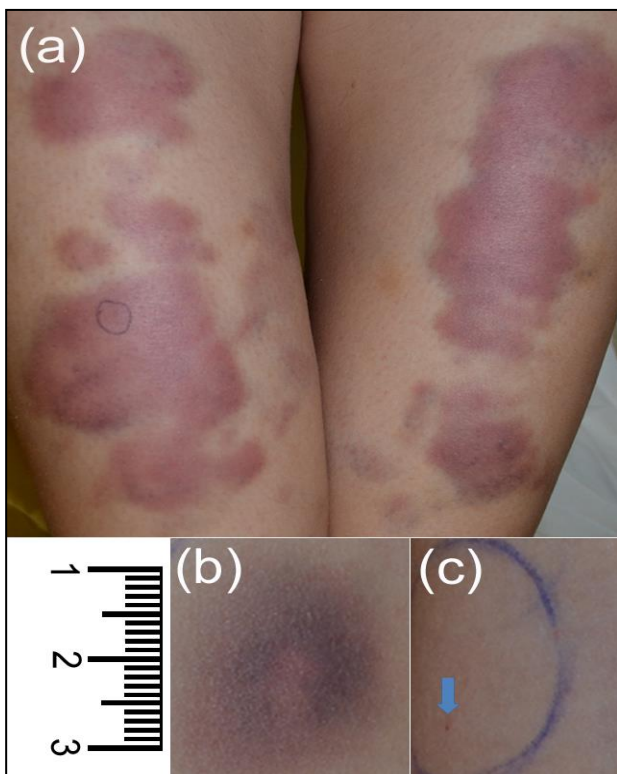


Figure 1: Panel (a)-Lesions at presentation (detail; the site of skin biopsy is indicated); Panels (b, c)- Erythrocyte auto-sensitization test: Intradermal injection of 0.1 mL of patient's washed red blood cells (volar surface of right forearm: test site). Concurrent application of 0.1 mL normal saline solution (left forearm: control site). Six hours later, the patient developed a painful ecchymotic reaction only on the test site

With the exception of paracetamol, no therapy was given, and fever subsided by day 12. The skin lesions gradually resolved during the next 15 days, following the well-known clinical course of a bruise. The patient was re-admitted to the hospital a month later with a bout of fever (38.5°C) without skin lesions or other findings. This time a bone marrow biopsy was also performed which was

The long periods of disease remissions, the absence of specific signs or findings, including a non-diagnostic skin biopsy and a positive erythrocyte auto-sensitization test favored the diagnosis GDS, despite the absence of overt psychiatric pathology in this case.

DISCUSSION

Erythrocyte auto-sensitization was a distinctive finding of this patient. A positive erythrocyte auto-sensitization test is a distinctive, though not characteristic finding of patients with GDS.^{3,4} The pathophysiological mechanism underlying the erythrocyte auto-sensitization in GDS is not known. Phosphatidylserine a phosphoglyceride of red blood cell membrane is considered to play an important role in the pathogenesis of this condition.³ This hypothesis is based on the observation that the incubation of normal donor erythrocytes with plasma from GDS patients resulted in redistribution of phosphatidylserine to the erythrocyte surface heralding eryptosis, i.e. the spontaneous erythrocyte cell death. This alteration is proposed to promote the binding of damaged erythrocytes to vascular wall and activate platelets heralding the development of the characteristic ecchymoses of GDS.⁵ However, how psychological stress triggers febrile corps of ecchymoses in GDS cases still remains elusive. Notably, the vast amount of triggers of phosphatidylserine redistribution and eryptosis points towards the existence of distinct subtypes of GDS.⁶

CONCLUSION

In conclusion, GDS is a rare, yet exciting clinical condition. Functional studies of erythrocytes in well characterized GDS patients could provide important insights in the mechanisms that underlie eryptosis.

Funding: No funding sources

Conflict of interest: None declared

Ethical approval: Not required

REFERENCES

1. Gardner FM, Diamond LK. Auto-erythrocyte sensitization. A form of purpura producing painful bruising following autosensitization to red blood cells in certain women. *Blood*. 1955;10:675-90.
2. Ratnoff OD. Psychogenic purpura (autoerythrocyte sensitization): an unsolved dilemma. *Am J Med*. 1989;87:16-21.
3. Tainwala RR, Phiske M, Raghuwanshi A, Mathapati S, Manjare AK, Jerajani HR. Perplexing purpura in two females: Rare case of autoerythrocyte sensitization syndrome. *Indian Dermatol Online J*. 2013;4:305-8.
4. Ivanov OL, Lvov N, Michenko V, Künzel J, Mayser P, Gieler U. Autoerythrocyte sensitization syndrome (Gardner-Diamond syndrome): review of the literature. *J Eur Acad Dermatol Venereol*. 2009;23:499-504.
5. Strunecká A, Krpejšová L, Paleček J. Transbilayer redistribution of phosphatidylserine in erythrocytes of a patient with autoerythrocyte sensitization syndrome (psychogenic purpura). *Folia Haematol Int Mag Klin Morph Blutforsch*. 1990;117:829-41.
6. Lang E, Lang F. Triggers, inhibitors, mechanisms, and significance of eryptosis: the suicidal erythrocyte death. *Biomed Res Intern*. 2015;2015:513-8.

Cite this article as: Sachanidou MG, Arampatzis GD, Zioga A, Gaitanis G, Bassukas ID. Recurrent self-healing painful ecchymoses and fever: a case of Gardner-diamond syndrome. *Int J Adv Med* 2017;4:593-5.