

## Original Research Article

# Spectrum of primary epithelial tumors of major salivary glands: a 5 year record based descriptive study from a tertiary care centre

Jayalakshmy Payipatt Leelamma\*, Bhavya P. Mohan

Department of Pathology Government Medical College, Kottayam, Kerala, India

**Received:** 14 December 2016

**Accepted:** 16 January 2017

### \*Correspondence:

Dr. Jayalakshmy Payipatt Leelamma,

E-mail: [jayafloyd@gmail.com](mailto:jayafloyd@gmail.com)

**Copyright:** © the author(s), publisher and licensee Medip Academy. This is an open-access article distributed under the terms of the Creative Commons Attribution Non-Commercial License, which permits unrestricted non-commercial use, distribution, and reproduction in any medium, provided the original work is properly cited.

### ABSTRACT

**Background:** Salivary gland tumors constitute a highly heterogeneous histopathologic group. There are few epidemiological studies of large series of benign and malignant epithelial tumors of major salivary glands in South India.

**Methods:** This is a retrospective study in a tertiary care centre in Kerala, South India. A total of 180 epithelial neoplasms of major salivary gland were studied over a 5 year period. In each case age, sex, anatomical location and histopathological diagnosis were recorded.

**Results:** Patients with benign and malignant tumors presented with a mean age of 52.3 and 55.9 years respectively. The frequency of benign tumors was 80.6% (n = 145) and of malignant tumors was 19.4% (n = 35). There was a higher prevalence of tumors in males 60.6% (n = 109) than in females 39.4% (n = 71). 91.9% (n = 164) of the tumors were localized in the parotid gland, 8.3% (n = 15) in the submandibular gland and 0.6% (n = 1) in the sublingual gland. The most common benign tumors were Pleomorphic adenoma (48.9%, n = 88) and Warthin's tumor (28.9%, n = 52). Among malignant tumors, Mucoepidermoid carcinoma was the most common (9.5%, n = 17) followed by Carcinoma ex pleomorphic adenoma (2.8%, n = 5) and adenoid cystic carcinoma (2.2%, n = 4).

**Conclusions:** Parotid gland was the most common site of both benign and malignant tumours. Plemorphic adenoma was the most common benign tumor and mucoepidermoid carcinoma was the most common malignant tumor.

**Keywords:** Epidemiology, Epithelial, Heterogeneous, South India, Salivary gland

### INTRODUCTION

Salivary gland tumors are a heterogeneous group of neoplasms in the head and neck area. Major salivary glands include the parotid, submandibular and sublingual glands. Tumors of the major salivary glands have complex morphologic appearances. They represent less than 1% of all tumors and 3-6% of all head and neck neoplasms in various reports.<sup>1,2</sup> The complex features exhibited by many of these neoplasms has aroused considerable speculations concerning their histogenesis and till date continues to hold the interest of clinicians and pathologists. This study was performed to analyse the

spectrum of major salivary gland tumours at a tertiary care centre in South India, encountered over a 5 year period, covering aspects of age, sex, anatomical location and histopathological diagnosis.

### METHODS

The present study was conducted at the Department of Pathology, Kottayam Medical College over a period of five years. The data were collected from the files of our department from 2011 to 2015. During this period, we found 180 tumors of major salivary glands. Information about age, gender and tumor location was obtained from

each clinical record. The histopathological analysis of all cases were meticulously reviewed and classified according to 2005 WHO histological classification of tumors of the salivary glands.

Tumors of minor salivary glands were excluded from the study. Also excluded were all non-epithelial tumors of major salivary glands.

**RESULTS**

There were 145 benign and 35 malignant tumors. The peak incidence of major salivary gland tumors in the present study was found to be in the 5th and 6th decade of life (Figure 1), with a male preponderance (Table 1). Patients with benign tumors presented with a mean age of

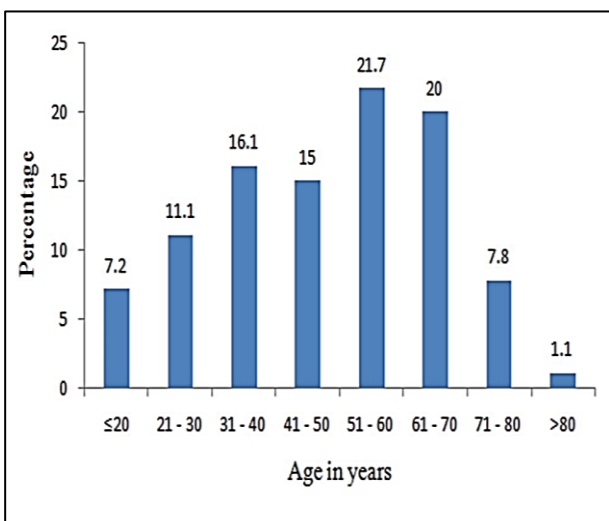
52.3 years and those with malignant tumors presented with a mean age of 55.9 years (Table 2). Histopathological diagnosis of tumors is also shown in Table 2. Distribution of major salivary gland tumours according to anatomical site is shown in Table 3. Relative frequency of benign and malignant tumors according to site is shown in Figure 2.

**Table 1: Gender distribution of major salivary gland tumours.**

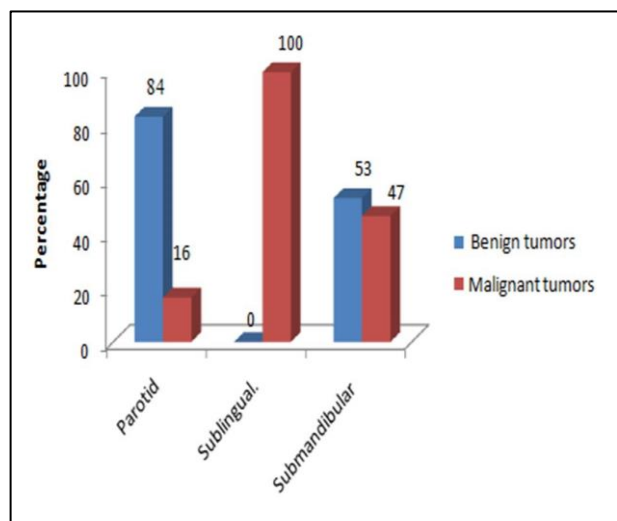
Gender	Frequency	Percent
Female	71	39.4
Male	109	60.6
<b>Total</b>	<b>180</b>	<b>100.0</b>

**Table 2: Histopathological diagnosis and relative frequency of benign and malignant tumors according to age.**

Tumor	Histologic type	Frequency	Percent	Median age	Age range
Benign	Pleomorphic adenoma	88	48.9	37.0	14-85
	Warthin's tumour	52	28.9	58.0	17-82
	Basal cell adenoma	4	2.2	58.0	23-77
	Oncocytoma	1	0.6	56.0	-
Malignant	Mucoepidermoid carcinoma	17	9.5	55.0	35-78
	Carcinoma ex pleomorphic adenoma	5	2.8	55.0	42-76
	Adenoid cystic carcinoma	4	2.2	44.0	30-71
	Acinic cell carcinoma	2	1.1	46.0	32-60
	Adenocarcinoma NOS	2	1.1	63.5	63-64
	Salivary duct carcinoma	2	1.1	73.5	69-78
	Epithelial myoepithelial carcinoma	1	0.6	68.0	-
	Papillary cystadenocarcinoma	1	0.6	51.0	-
	Secretory analogue mammary carcinoma	1	0.6	48.0	-
<b>Total</b>		<b>180</b>	<b>100</b>	<b>51</b>	<b>14-85</b>



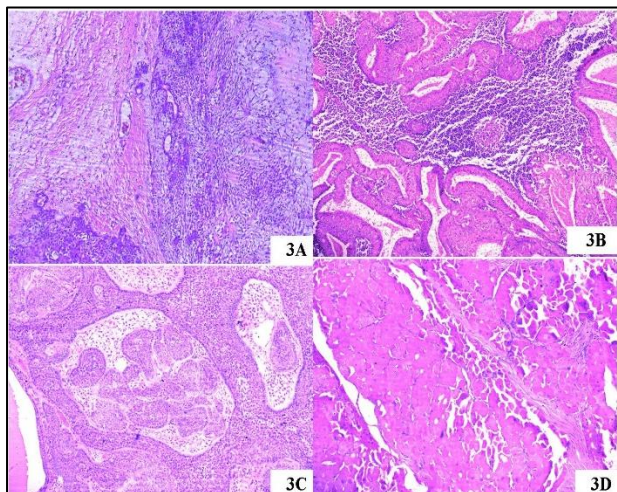
**Figure 1: Age distribution of major salivary gland tumours.**



**Figure 2: Relative frequency of benign and malignant tumors according to site**

**Table 3: Site distribution of major salivary gland tumours.**

Site	Frequency	Percent
Parotid gland	164	91.1
Submandibular gland	15	8.3
Sublingual gland	1	0.6
<b>Total</b>	<b>180</b>	<b>100.0</b>



**Figure 3: Pleomorphic adenoma (3A, H and E 100X), Warthin 's tumor (3B, H and E 100X), Basal cell adenoma (3C, H and E 100X), Oncocytoma (3D, H and E 100X).**

**Benign tumor**

*Pleomorphic adenoma*

There were 88 cases of Pleomorphic adenoma (PA) [(Figure 3(A)], which constituted 48.9% of the total number of tumors. Parotid gland was affected in 81 cases, followed by 7 cases in submandibular gland. It was not noted in sublingual gland. The female to male ratio was 1.4:1. The age range was 14-85 years. The mean age was 37 years.

*Warthin's tumor*

There were 52 cases (28.9%) of Warthin's tumor (WT) [Figure 3(B)]. WT affected mainly parotid gland (51 cases), but one case was noted in submandibular gland and were bilateral in 4 cases. The male to female ratio was 25:1. The age range was 17-82 years. The mean age was 58 years.

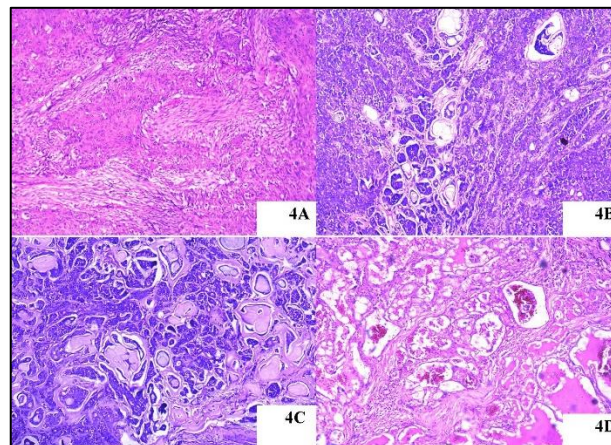
*Basal cell adenoma*

There were 4 cases (2.2%) of Basal cell adenoma [Figure 3(C)]. All 4 cases were noted in parotid gland. The male to female ratio was 1:1. The age range was 23-77 years. The mean age was 58 years.

*Oncocytoma*

A single case of oncocytoma (0.6%) (Fig. 3D), was detected in the parotid gland of a 56-year-old male.

**Malignant tumors**



**Figure 4: Mucoepidermoid carcinoma (4A, H and E 100X), Carcinoma ex pleomorphic adenoma (4B, H and E 100X), Adenoid cystic carcinoma (4C, H and E 100X), Acinic cell carcinoma (4D, H and E 100X).**

*Mucoepidermoid carcinoma*

In the present study, 17 tumors were identified as Mucoepidermoid carcinoma [Figure 4(A)] and these accounted for 9.5% of all tumors or 48.6% of the malignant tumors. We noted 12 cases in parotid gland and 5 cases in submandibular gland. 7 cases were histologically classified as low grade, 3 cases as intermediate grade and 7 cases as high grade. Mucoepidermoid carcinoma occurred in 6 females and 11 males with an age range of 35-78 years. The mean age was 55 years.

*Carcinoma ex pleomorphic adenoma*

There were 5 cases of Carcinoma ex pleomorphic adenoma (CPA) [Figure 4(B)] and these accounted for 2.8% of all tumors and 14.3 % of the malignant tumors. Out of 5 cases, 3 cases were noted in parotid gland and 2 cases in submandibular gland. The malignant component noted was adenocarcinoma in 3 cases, adenoid cystic carcinoma in 1 case and epithelial myoepithelial carcinoma in 1 case. The male to female ratio was 3:2. The age range was 42-76 years. The peak incidence was in the 6th decade.

*Adenoid cystic carcinoma*

There were 4 cases of Adenoid cystic carcinoma (ACC) [Figure 4(C)] and these accounted for 2.2% of all tumors or 11.4% of the malignant tumors. We observed 2 cases in the parotid gland and 2 cases in the submandibular

gland. ACC affected 2 females and 2 males. The age range was 30-71 years. The mean age was 44 years.

*Acinic cell carcinoma*

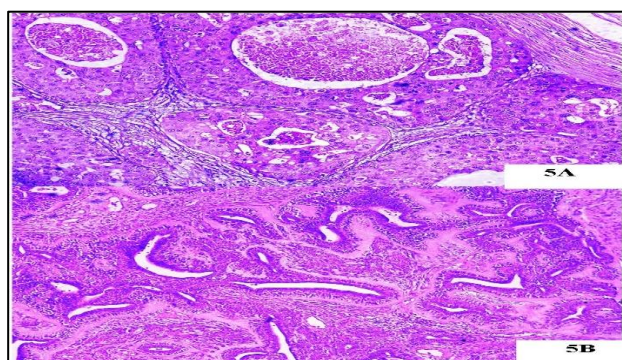
In this series, 2 tumors were identified as acinic cell carcinoma [Figure 4(D)] and these accounted for 1.1% of all cases or 5.7% of the malignant tumors. We observed both cases in the parotid gland. It affected 2 females. The age range was 32-60 years. The mean age was 46 years.

*Adenocarcinoma not otherwise specified (NOS)*

There were 2 cases of adenocarcinoma NOS and these accounted for 1.1% of all cases or 5.7% of the malignant tumors. Both were noted in the parotid gland. The male to female ratio was 1:1. The age range was 63-64 years. The mean age was 63.5 years.

*Salivary duct carcinoma*

In this series, 2 tumors were identified as Salivary duct carcinoma [Figure 5(A)] and these accounted for 1.1% of all cases or 5.7% of the malignant tumors. We observed both cases in the parotid gland. It affected 2 males. The age range was 69-78 years. The mean age was 73.5 years.



**Figure 5: Salivary duct carcinoma (5A, H and E 100X), Epithelial myoepithelial carcinoma (5B, H and E 100X).**

*Epithelial-myoepithelial carcinoma*

A single case of epithelial-myoepithelial carcinoma (0.6%) [Figure 5(B)] was observed in the parotid gland of a 68-year-old female.

*Papillary cystadenocarcinoma*

A single case of papillary cystadenocarcinoma (0.6%) was noted in the parotid gland of a 51-year-old female.

*Secretory analogue mammary carcinoma*

A single case of secretory analogue mammary carcinoma (0.6%) was diagnosed in the parotid gland of a 48-year-old male.

**DISCUSSION**

In the present study, we reviewed 180 major salivary gland tumors, revealing a predominance of benign (80.6%) compared to malignant tumors (19.4%) similar to a series of 124 cases by Vagas et al in a Brazilian population. We found a higher prevalence of tumors in males (60.6%) than in females (39.4%) as observed by Gonzalez F et al.<sup>3,4</sup>

Majority of the major salivary gland tumors occurred in the parotid gland (91.1%), which correlated well with the study conducted by Fernandez GC et al.<sup>5</sup> The percentage of submandibular salivary gland tumors is next to that of the parotid gland. As seen in Table 4, in the present study also the submandibular gland was the second common site of major salivary gland neoplasms (8.3%). The percentage of tumors in the sublingual glands has been reported as 0.78% by Das DK et al and the present study records a percentage of 0.6%.<sup>6</sup> This result demonstrates the low prevalence of sublingual tumors, as has been reported by Eveson et al who observed one sublingual tumor to 100 parotid tumors. Similarly, Ma’aita et al reported one sublingual tumor (0.4%) among 221 cases.<sup>7,8</sup>

**Table 4: Comparative analysis of site distribution of major salivary gland tumours.**

Series	Parotid	Submandibular	Sublingual
Fernandes GC et al <sup>5</sup>	52.04%	44.71%	0.81%
Das KD et al <sup>6</sup>	65.63%	33.59%	0.78%
Eveson et al <sup>7</sup>	72.90%	10.7%	0.3%
Canan E et al <sup>18</sup>	75.54%	24.46%	0.00%
Present study	91.1%	8.3%	0.6%

The mean age for benign and malignant tumors was 52.3 years and 55.9 years respectively in our study. In contrast, studies by Satko et al in Slovakian population

and Ahmad et al in Kashmir showed the highest incidence of benign tumors in the 4th decade and malignant tumors in the 5th decade of life.<sup>9,10</sup> The mean

age of patients with malignant neoplasms was higher than the patients with benign neoplasms.

Pleomorphic adenoma was the most common tumor (48.9%) encountered in the present study and corresponded to 60.7% of all benign tumors. 81 cases were noted in the parotid and seven in the submandibular gland. All epidemiological papers analyzing the prevalence of major salivary gland tumors in the head and neck region showed a singular predominance of pleomorphic adenoma (50% to 80%) among benign and malignant tumors.<sup>4,8,9</sup> The parotid gland is the main site affected by pleomorphic adenomas followed by the submandibular and minor salivary glands.

Warthin's tumor (WT) comprised 35.9% of the benign salivary gland tumors and formed the second common benign tumor. WT affected mainly parotid gland (51 cases), but one case was noted in submandibular gland. The frequency observed in the literature of WT ranged from 9% to 28%.<sup>11,12</sup> Most bilateral parotid gland tumors are WT and bilateralism occurred in four out of 52 cases in our study permitted the following conclusions.<sup>12</sup> Basal cell adenoma occurred only in the parotid gland. Basal cell adenomas are reported as tumors affecting principally the parotid gland and the peak incidence ranged from 4th to 7th decade.<sup>13</sup> We came across 4 cases which were noted in the parotid gland. The age range was 23-77 years. Oncocytomas are rare benign tumors with a median age of 60.1 years and a male predominance.<sup>14</sup> All the tumours occurred in the parotid gland.<sup>14</sup> We noted a single case of oncocytoma in the parotid gland of a 56-year-old male.

Mucoepidermoid carcinoma (MEC) accounted for 9.5% of all tumors or 48.6% of the malignant tumors. When we analysed malignant tumors, MEC was the most common tumor as reported in a majority of the studies in Table 4. We detected seven low-grade cases, three intermediate-grade cases, and seven high-grade cases. Of the 234 cases of MEC reported by Goode et al.<sup>15</sup> 178 cases were low grade, 18 cases were intermediate grade and 31 cases were high grade.

Carcinoma ex pleomorphic adenoma formed the second common malignant tumor (14.3%) and affected parotid and submandibular glands in our study. Olsen et al.<sup>17</sup> reported 73 cases of carcinoma ex pleomorphic adenoma, of which 64% occurred in males and 36% in females. The mean age was 61 years. Adenocarcinoma (31 cases) and salivary duct carcinoma (24 cases) were the most common malignant subtypes. In our study, the male to female ratio was 3:2, the mean age was 55 years and the malignant histologic subtypes observed were adenocarcinoma, adenoid cystic carcinoma and epithelial myoepithelial carcinoma.

Adenoid cystic carcinoma (ACC) accounted for 2.2% of all tumors or 11.4% of the malignant tumors. We observed 2 cases in the parotid gland and 2 cases in the

submandibular gland. Szmaja et al. 16 studying 111 cases of ACC, observed that the main site affected was the parotid gland (47 cases) and the most common location of ACC in a minor salivary gland was the palate (14 cases). All cases of acinic cell carcinoma (1.1%) occurred in the parotid gland. Adenocarcinoma not otherwise specified (NOS) and Salivary duct carcinoma were noted in both parotid gland and submandibular gland. Epithelial myoepithelial carcinoma, Papillary cystadenocarcinoma and Secretory analogue mammary carcinoma occurred in 1 case (0.6%) each and affected the parotid gland.

## CONCLUSION

The epidemiological analysis of 180 primary epithelial tumors of major salivary salivary glands has permitted patients with benign and malignant tumors presented with a mean age of 52.3 and 55.9 years respectively. The frequency of benign tumors was 80.6% (n = 145) and of malignant tumors was 19.4% (n = 35). There was a higher prevalence of tumors in males 60.6% (n = 109) than in females 39.4% (n = 71). 91.9% (n = 164) of the tumors were localized in the parotid gland, 8.3% (n = 15) in the submandibular gland and 0.6% (n = 1) in the sublingual gland. The most common benign tumors were Pleomorphic adenoma (48.9%, n = 88) and Warthin's tumor (28.9%, n = 52). Among malignant tumors, Mucoepidermoid carcinoma was the most common (9.5%, n = 17) followed by Carcinoma ex pleomorphic adenoma (2.8%, n = 5) and adenoid cystic carcinoma (2.2%, n = 4).

## ACKNOWLEDGEMENTS

Authors would like to thank the paramedical staff Miss Kalakumari and Miss. Suja who provided the slides for histopathological study.

*Funding: No funding sources*

*Conflict of interest: None declared*

*Ethical approval: The study was approved by the institutional ethics committee*

## REFERENCES

1. Ansari M. Salivary gland tumors in an Iranian population: a retrospective study of 130 cases. *J Oral Maxillofac Surg.* 2007;65:2187-94.
2. Jones AV, Craig GT, Speight PM. The range and demographics of salivary gland tumors diagnosed in a UK population. *Oral Oncol.* 2008;44:407-17.
3. Vargas PA, Gerhard R, AraujoFilho VJ, de Castro IV. Salivary gland tumors in a Brazilian population: A retrospective study of 124 cases. *Rev Hosp Clin Fac Med Sao Paulo.* 2002;57:271-6.
4. Gonzalez C, Ramirez A, Caballero T, Caballero T. Epidemiological study of salivary gland tumours. *Rev Laryngol Otol Rhinol.* 1999;120:331-6.
5. Fernandes GC, Pandit AA. Diagnosis of salivary gland tumours by FNAC. *Bombay Hospital J.* 2002;4:201-6.

6. Das DK, Petkar MA, Al-Mane NM, Sheikh ZA, Mallik MK, Anim JT. Role of fine needle aspiration cytology in the diagnosis of swellings in the salivary gland regions: a study of 712 cases. *Med Princ Pract.* 2004;13:95-106.
7. Eveson JW, Cawson RA. Salivary gland tumors: a review of 2410 cases with particular reference to histological types, site, age, and sex distribution. *J Pathol.* 1985;146:51-8.
8. Ma'aita JK, Al-Kaisi N, Al-Tamimi S, Wraikat A. Salivary gland tumors in Jordan: a retrospective study of 221 patients. *Croat Med J.* 1999;40:539-42.
9. Satko I, Stanko P, Longauerova I. Salivary gland tumours treated in the stomatological clinics in Bratislava. *J Craniomaxillofac Surg.* 2000;28:56-61.
10. Ahmad S, Lateef M, Ahmad R. Clinicopathological study of primary salivary gland tumours in Kashmir. *JK Pract.* 2002;9:231-3.
11. Chung YF, Khoo ML, Heng MK. Epidemiology of Warthin's tumour of the parotid gland in an Asian population. *Br J Surg.* 1999;86:661-4.
12. Watanabe T, Ichimiya I, Suzuki M, Mogi G. Clinical study of bilateral parotid tumors. *Nippon Jibiinkoka Gakkai Kaiho.* 1999;102:1169-74.
13. Suzuki S, Okamura H, Ohtani I. Bilateral parotid gland basal cell adenomas. *ORL J Oto-rhinolaryngol Specialt.* 2000;62:278-81.
14. Zhou CX, Gao Y. Oncocytoma of the salivary glands: a clinicopathologic and immunohistochemical study. *Oral Oncol.* 2009;45:232-8.
15. Goode RK, Auclair PL, Ellis GL. Mucoepidermoid carcinoma of the major salivary glands. Clinical and histopathologic analysis of 234 cases with evaluation of grading Criteria. *Cancer.* 1998;82:1217-24.
16. Olsen KD, Lewis JE. Carcinoma ex pleomorphic adenoma: a clinicopathologic review. *Head Neck.* 2001;23:705-12.
17. Szmeja Z, Kulczynski B, Citowicki W. Adenoid cystic carcinomas of the head and neck (cylindromas). *Otolaryngol Pol.* 1999;53:539-44.
18. Canan E, Uguz AH, Tuncer U, Soyulu L, Kiroglu M. Fine needle aspiration cytology of the salivary glands: a twelve years experience. *Aeg Pathol J.* 2004;1:51-6.

**Cite this article as:** Leelamma JP, Mohan BP. Spectrum of primary epithelial tumors of major salivary glands: a 5 year record based descriptive study from a tertiary care centre. *Int J Adv Med* 2017;4:562-7.