

Review Article

Priapism: what to do?

Mehmet Giray Sönmez^{*}, Abdülkadir Kandemir², Mehmet Balasar¹

¹Department of Urology, Meram Medical Faculty, Necmettin Erbakan University, Konya, Turkey

²Department of Urology, Gümüşhane Kelkit State Hospital, Gümüşhane, Turkey

Received: 23 August 2017

Accepted: 19 September 2017

*Correspondence:

Dr. Mehmet Giray Sönmez

E-mail: drgiraysonmez@gmail.com

Copyright: © the author(s), publisher and licensee Medip Academy. This is an open-access article distributed under the terms of the Creative Commons Attribution Non-Commercial License, which permits unrestricted non-commercial use, distribution, and reproduction in any medium, provided the original work is properly cited.

ABSTRACT

Priapism is a painful erection condition of penis or clitoris lasting more than four hours without sexual desire. Glans and corpus spongiosum do not participate in this period. Although the incidence is not common in males, it can also be seen in females very rarely. Priapism has three types. These are classifying as; Ischemic (low-flow) priapism, Non-ischemic (high-flow) priapism, Recurrent (stuttering) priapism. Priapism is an urgent urological disease which should be managed well since it may cause severe penile function disorder. Our aim in this article is presenting appropriate management of priapism in the light of current literature. We hope that the studies to be done in the future would be helpful to reveal priapism molecular mechanisms and develop our ability of care for the patients in this condition.

Keywords: Pain, Priapism, Priapism Treatment, Penile erection, Urological emergency

INTRODUCTION

The term 'priapism' was derived from the large falls of Priapus known as the god of fertility and desire.¹ Priapism is a painful erection condition of penis or clitoris lasting more than four hours without sexual desire. Glans and corpus spongiosum do not participate in this period.

Although the incidence is not common in males (0.3-0.9/100.000), it can also be seen in females very rarely. Priapism was clinically reported for the first time in 1845.²⁻⁴

Priapism can be seen in any age group. But bimodal peak distribution can be observed between the ages 5 and 10 among children and 20 and 50 among adults. Although the probable causes of priapism differ according to

priapism types, it is observed that they are mostly related to idiopathic causes.

Alcohol, medicine, drug use (21%), perineal trauma (12%) and or sickle cell nephropathy (5%) are other possible etiological causes in order.^{5,6} Priapism is an urgent urological disease which should be managed well since it may cause severe penile function disorder. Our aim in this article is presenting appropriate management of priapism in the light of current literature.

TYPES OF PRIAPISM

Priapism has three types. These are classifying as

- Ischemic (low-flow) priapism
- Non-ischemic (high-flow) priapism
- Recurrent (stuttering) priapism.

Ischemic priapism

It is the most common type (95%).³ It is characterized by persistent erection and rigidity of corpus cavernosum (CC). It is characterized by scarcity or lack of flow in CC. Cavernosal blood gas analyses are often characterized by hypoxia, hypercapnia and acidosis. In ischemic priapism, the ultrastructural changes in cavernosal flat muscle are observed 12hours later, focal necrosis 24hours later and finally necrosis and transformation of wide necrosis and fibroblast-like cells are observed 48hours later.⁷ If untreated or treated late (>24 hours) necrosis, irreversible corporal fibrosis and erectile dysfunction occur in cavernosal flat muscles.²

Non-ischemic priapism

Non-ischemic (arterial, high-flow) type is a rare type of priapism and occurs due to irregular cavernosal blood flow. This type often (82.5% in adults and 96.1% in children) occurs due to the rupture of cavernosal artery or one of its branches into CC.⁸ It was also reported that laserization of cavernosal artery with injection during intracavernosal treatment causes high flow priapism.⁹ Erection is generally unpainful, and CC is not rigid. Cavernosal blood analysis demonstrates normal arterial oxygen pressure and there is no acidosis and hypoxia. Aspiration blood colour is light red and urgent treatment is not required.¹⁰

Recurring (stuttering) priapism

The third type recurrent priapism is rather rare and occurs with detumescence periods between undesired painful erection episodes. Although it is commonly idiopathic, it has a tendency of being more ischemic. It can be related with sickle cell anemia in children especially. The aim in these patients is to develop preventive treatment protocols to prevent priapism episodes in the future.¹¹⁻¹³

METHODS

A literature search was conducted with the assistance of a senior researcher. There were no restrictions to language or publication status. The articles were selected by reviewing their titles and abstracts with additional references identified from the reference lists of selected articles.

SEARCH STRATEGY

We searched the following electronic databases from 1964 to 2017: Pubmed, Medline, Embase (Excerpta Medica Database), CINAHL (Cumulative Index to Nursing and Allied Health Literature), Cochrane Database of Systematic Reviews, EBSCO Publishing's Electronic Databases, Exlibris-Primo Central, Google Scholar, Hinari, Infotrieve, Journal Guide, National Science Library, OpenJGate, ProQuest, TdNet.

The following search strategy was modified for the various databases and search engines: priapism, priapism management, priapism treatment, penile shunt, priapism review, priapism case report.

Along with MeSH terms and relevant keywords, we used the Cochrane Highly Sensitive Search Strategy for identifying reports of articles in Pubmed. There were no restrictions to language or publication status.

TYPES OF STUDIES

Randomized controlled trials (RCT), reviews and case control studies.

Inclusion and exclusion criteria

Based on the key questions, we came up with inclusion and exclusion criteria. Included were abstract and full articles written in all languages and reporting on priapism.

Abstract and full text of inaccessible studies and articles written before 1964 were excluded. A total of 43 studies were included in this review.

Data extraction and management

Two research team members (MGS and AK) independently conducted data extraction from the final sample of articles by using a pre-established data extraction form. Disagreements were resolved by consensus or by arbitration of a third review author (MB).

Studies were reviewed for relevance based on the type of priapism, treatment, interventions (priapism treatment) and outcome measures.

We retrieved full text copies of the articles identified as potentially relevant by either one or both review authors. The flow of study selection is described in a Preferred Reporting Items for Systematic Reviews and Meta-Analyses (PRISMA) diagram (figure 1). Data are reported in a narrative manner.

CURRENT STATUS OF KNOWLEDGE

The final screening resulted in a sample of 43 articles that had information on priapism. These were articles published between 1964 and 2017. Figure 1 illustrates the search strategy and the selection process.

ANAMNESIS

Priapism duration, duration of pain (ischemic priapism is typically painful, and the pain generally starts in the first hour of episode), perineal (especially in horse riding style) or penile trauma should be investigated.

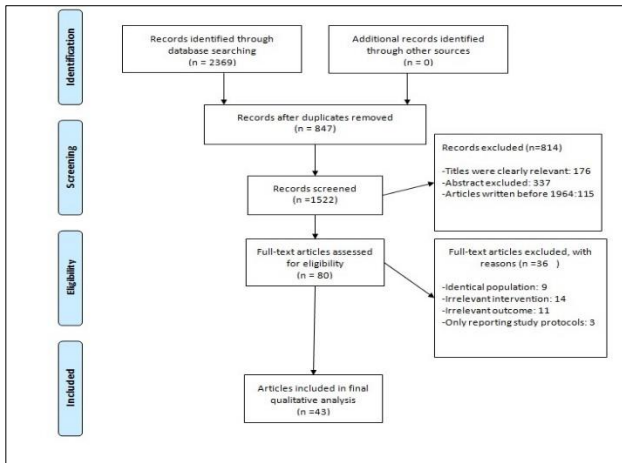


Figure 1: Illustrates the search strategy and the selection process.

Cavernosal hematomata should be distinguished from high flow priapism. Still the most common reason for priapism is the use of high dose of intracavernosal agents (papaverine, prostaglandin E1, phentolamine and similar vasoactive agents). On the other hand, many oral medicines such as antihypertensives (hydralazin, prazosin, guanethidine, anticoagulants (heparin), antidepressants (trazodone), antipsychotics (chlorpromazine, clozapine) may be related with priapism. So, medicine history should be investigated carefully.^{2,14}

Other hemoglobinopathies such as β thalassemia and sickle cell anemia causing hematological and thrombotic disorders may cause priapism. Additionally, many malign disease types may cause priapism due to the obstruction formed by the tumour in venous exit.

Cancer types frequently causing priapism are bladder (30%), prostate (30%), rectosigmoid (16%) and kidney (11%) cancers. Neurological diseases such as spinal stenosis and spinal cord lesion (especially high level) may cause priapism.^{15,16}

PHYSICAL EXAMINATION

Genital organs and perine should be evaluated to determine new traumas which may be the demonstrator of non-ischemic priapism.

While rigidity was detected in corpus cavernosum in priapism patients, rigidity cannot be detected in corpus spongiosum and glans penis. Evaluation of corpus cavernosum can be helpful in the detection of priapism type.

Fully rigid corpus cavernosum is observed in ischemic priapism and partially-rigid corpus cavernosum is observed in non-ischemic priapism. Additionally, abdominal and rectal examination should be done to

exclude the presence of malignity which may cause ischemic priapism.^{3,6}

DISCUSSION

Laboratory/radiological evaluation

Blood analyses

Complete blood count should be done if a hematological abnormality is detected as a result, an additional evaluation (hb electrophoresis, reticulocyte count for sickle cell anemia) should be done.

Blood gas tests

Everyone should have corporeal aspiration and blood analysis. Blood gas values are hypoxic and acidotic in ischemic priapism (PO₂ <30mmHg, PCO₂ >60mmHg, pH<7.25) and the colour of aspirated blood is dark red due to hypoxia. Blood gas values are similar to arterial blood in non-ischemic priapism and the colour of aspiration blood is light red.

Penile colour doppler ultrasonography

It may be helpful for blood gas analysis in priapism evaluation. However, especially in perineal trauma patients, it has a critical importance in demonstrating abnormalities such as cavernosal artery fistula or pseudoaneurysm. Cavernosal blood flow is frequently normal in non-ischemic priapism or it has increased a little. It demonstrates that the blood flow level in PRDU cavernosal arteries is low or there is no blood flow in ischemic priapism.⁶

Penile arteriography

It can both be used in the diagnosis of non-ischemic priapism and embolisation for treatment.⁶

TREATMENT

Ischemic priapism treatment

It is recommended to start with the least invasive one in priapism approach (corporeal blood aspiration) and follow with the more invasive (shunt procedures or penile prosthesis implantation) is recommended.⁴

Non-surgical treatments

The aim in the treatment of all priapism patients is preserving erectile function and detumescence to relieve the pain. It was reported that there was persistent erectile dysfunction table secondary to penile necrosis and fibrosis in patients with nearly 90% in cases in which detumescence loss has passed 24 hours in ischemic priapism cases. Possible etiological factors causing priapism should be evaluated according to the data which

may be acquired before intervention and the treatment should directly be made on the underlying etiological factor. For example, in hydration, alkalization, transfusion and oxygenation are other treatment alternatives available in sickle cell anemia. Chemotherapy and radiotherapy may contribute to the recurrence of priapism in hematological malignities. On the other hand, the specific systemic treatment of the causing etiological factor should not be perceived as priapism treatment and intracavernosal intervention and systemic treatments should be started simultaneously.¹²

Before specific treatment, in the early phase of priapism, priapism can be eased by inducing vaso-constructive reflex by cold shower and ice bags.²

Medical treatment

Non-invasive treatment approaches are recommended for ischemic priapism in current studies

Habous et al. provided detumescence in 34% of priapism patients in 60 minutes with salbutamol 4 mg oral treatment which is B2 adrenergic agonist.¹⁷ Lowe and Jarow compared terbutaline which is B2 adrenergic agonist and pseudoephedrine which is α - and β -adrenergic agonist in priapism patients and took a respond ratio of 38% with terbutaline and 28% with pseudoephedrine.¹⁸ With the negative affect on testosterone, gonadotropin-releasing hormone agonists, estrogens, anti- androgens and 5 α -reductase inhibitors can also be used in non-invasive medical treatment of priapism.^{3,4}

Corporal aspiration

Priapism can be fixed with corporal blood aspiration in nearly 1/3 of the patients.¹² Paying attention to dorsal neurovascular bundle, corporal aspiration should be continued in peno-scrotal resultant level using 19 Gauge (G) or 21G butterfly needle laterally and in 3 or 9 o'clock level until red, fresh blood comes.¹⁹

Intracavernosal sympathomimetics

Intracavernosal sympathomimetics provide detumescence by stimulating cavernous flat muscle and the success rate of the treatment depends on priapism duration and close to 80%.²⁰ Treatment response ratio decreases in patients with a ischemia duration longer than 72 hours. Use of selective α 1-adrenergic receptor agonists is recommended in order to minimize possible undesired cardiac side effects.¹² Heart rate and blood pressure values should be followed closely during medicine application.⁷ 200 μ g phenylephrine can be applied up to maximum 1 mg per 5-10 minutes.²¹ Although there are studies on intracavernosal injection of tissue plasminogen activator which is a thrombolytic agent in ischemic priapism treatment, this method couldn't go beyond being an experimental application.²²

Surgical treatment

If it was impossible to take response to the medical treatment at the beginning, first distal shunts should be considered (such as Ebbehøj, Winter's and Al-Ghorab, etc) and if it cannot be succeeded, proximal shunts (Quackel, Grayhack) should be tried.

Distal shunt

If recovery is not possible although sympathomimetic agents are used in irrigation and aspiration is made, surgical procedures should be considered. The next step is the application of a distal shunt between glans penis and corpus cavernosum. This shunt provides drainage of venous blood trapped in corpus spongiosum to corpus cavernosum. There are many different shunt procedures such as Ebbehøj, Winter's and Al-Ghorab. In Ebbehøj shunt, glans penis end lower lateral is tied to one or both corpus cavernosum using a bisturi.²³ It contains the same maneuver in Winter's shunt. But biopsy needle takes the place of bisturi.²⁴ Finally a transverse incision is present inside the corona and superior part of urethral meatus and glans in Al-Ghorab shunt. The incision can be done by sliding the incision from corpus cavernosa to the closed edge of tunica albuginea.²⁵

Although Al-Ghorab shunt is the most effective among distal shunts, it was observed that width invasive and impotence ratio were highest in the report. Some leaders recommend that this shunt is made after trying Winter's and Ebbehøj shunt.²⁴

The first T-Shunt is recommended as shunt procedure in a study by Lian et al. The reason is the simplicity and rapid applicability of this operation. But this shunt is not appropriate for patients arriving with priapism lengthened >48 hours. The reason is the difficult installation of this shunt due to the damaged proximal CC blood perfusion and the severe tissue edema occurring in the patient with lengthened priapism patient. So, the authors modified the shunt and intracavernous dilatation methods in lengthened ischemic priapism and demonstrated that intracavernous tunnel method done by using Corpus Cavernosum-spongiosum + hegar bougies was better than other methods [CC-CSS shunt + ICT].²⁵

Burnett et al aimed the mobilization of the blood from penis proximal to the distal using hegar bougies no 7 and 8 along a few centimeters towards the inside of cc in a technique they modified al-ghorab shunt. They also defend that distal shunt activity will increase due to dilatator usage.²⁶

Kilinc developed a new artificial cavernosal-cephalic shunt in 15 patients referring with ischemic priapism lasting 20 hours in average. Two 18-gauge angiocath were located in (each) corpus cavernosum with transglanular approach and heparinized saline solution was infused with an angiokat and the other section was

tied with a third 18-gauge angiocath to the cephalic vein of arm. Thus, a constant corporeal-systemic circulation shunt was formed. Irrigation continued for 30 minutes but this operation was repeated for six hours in cases without detumescence. Total detumescence success ratios were 87% and the treatment phase lasted nearly 110 minutes (30-300 min) and two non-responding cases were successfully treated with Grayhack shunt. But erectile dysfunction was observed in 8 out of 13 patients successfully treated.²⁷

The result of the study by T. Lue et al is the use of T shunt in selective alpha 1 adrenergic receptor agonist injection resistant ischemic priapism treatment. This shunt is formed by passing over the penile glans through corpus cavernosum using No 10 bisturi under local anesthesia. Bisturi is located through the glans penis surface and turned 90 degrees to provide a large fistula before the discharge of venous blood in penis. If it is not possible to apply a low pressure to corpus cavernosum 10-15minutes after this procedure, the same process is repeated on the other side (TT-Shunt). If the hardness of corpus cavernosum continues after TT-Shunt, (priapism cases continuing for three days), Corporeal Tunnel is made using 20-24 fr urethral catheter or dilatator through a glanular cut and the proximal-distal circulation of the blood is returned inside ipsilateral corpus spongiosum (TTT-Shunt). TTT-Shunt is used when there is a tissue edema prohibiting the proximo-distal circulation is lengthened priapism cases. Perfect results were acquired in their study on priapism resolution and pain relief in 13 cases. The theoretic advantage of this approach is the expandibility of the shunt so that it may cover both distals and proximal of corpus cavernosum. Thus, the drainage of the whole cavernosal particle becomes easier.²¹

Proximal shunt

Some cases in ischemic priapism may have caused continuous hypoxia and acidosis and edema and necrosis in cavernosum especially if it lasts more than 72 hours. Proximal shunt operations should be considered when distal shunt operations fail in ischemic priapism treatment. Cavernoso-spongiosum shaft (Quackel and Sacher) and cavernoso-saphenous shunt (Grayhack) are the two most effective shunt types. In proximal shunt, an anastomosis was formed between corpus spongiosum each proximal cavernosum with perineal incision.²⁸ Today, Grayhack shunt applied rarely due to the easiness of shunt contains anastomosis between cavernosal object and saphenous vein.²⁹

Although proximal shunt is a reasonable activity for priapism solution, it increases significant surgical complication risk in addition to requiring more time and being more complicated. In the reports, it was observed to cause anastomosis urethral fistula and cavernositis between corpus spongiosum and cavernosum.³⁰ Again, it was also reported that cavernoses drained through saphenous veins causes pulmonary embolism.³¹

Penile prosthesis

Severe erectile dysfunction develops in 90 percent of the priapism cases lasting longer than 24 hours.² It is claimed that treatments started after 72 hours will be helpful in preventing the undesired erections and relieving the pain. But it has little influence on the preservation of erectile function.³² On the other hand, the failure in priapism treatment causes severe cavernosal fibrosis and makes the latter penile prosthesis implantation harder due to high undesired side effect ratios. As a result, early period penile prosthesis implantation was recommended in ischemic priapism treatment lately.³³ Penile prosthesis was implanted in 8 days in average to 27 ischemic priapism patients in the study by Kumar et al.³⁴ at the beginning Mentor malleable prosthesis was installed in 25 patients and then nine of these were changed with three-piece inflatable prosthesis. As the result of a nearly 17-month follow-up, all patients were reported to be satisfied and have a normal erectile function, only two undesired side effects (infection and curvature) were reported. In fact, this concept was used in recurrent priapism patients caused by sickle cell disease. Monga et al.³⁵ implanted malleable penile prosthesis in 6 recurrent (5.4 times in average) priapism patients. Authors reported that satisfying results occurred with this treatment and revision was required only in one patient.

Non-ischemic (high-flow) priapism treatment

A spontaneous recovery ratio of 62% was reported in untreated non-ischemic priapism cases in literature.^{2,4} Since there is no medical urgency, these patients can be followed conservatively, and the spontaneous healing of ruptures can be expected.³⁶ To reach detumescence, ice or pressure bags to cause vasospasm and laserized artery thrombosis in early period may be helpful in early period.³⁷ There are no urgent surgical indications for non-ischemic priapism. There is no limitation in blood flow in case of arterial flow entrance secondary erection condition and the hypoxia and acidosis observed in ischemic priapism are not observed. There is a low permanent damage risk in the patients. The observation causes spontaneous resolution in nearly 60% of the patients and thus the first management should be observation.³⁸ Spontaneous recovery generally occurs when there is no underlying cause such as an anatomical disorder or pseudoaneurism.

In non-ischemic priapism treatment, corporal aspiration has no role with or without sympathomimetic agents. This is because this condition occurs due to the irregular arterial flow to corpus cavernosum, not failure of detumescence mechanism. In nearly half of the cases, the certain treatment of the disease is selective angiographic embolisation of arterio-sinusoidal fistula. Autologous coagulum and absorbable materials (gelfoam) or non-absorbable materials (coils, ethanol, polyvinyl alcohol particles) are used for this aim. Although there is a recurrence risk, embolization made with absorbable tools

provides a short-term occlusion for one or two days and this preserves the erection capacities of the patients.³⁸ The resolution and erectile dysfunction (ED) ratios of non-ischemic priapism with absorbing and non-absorbing tools are reported as 78%, 39%, 74% and 5% in order.¹²

Recurrent (stuttering) priapism treatment

Priapism often starts when sleeping and detumescence doesn't occur right after waking up. This situation may also be related with the length of sexual activity. Stuttering priapism treatment is relatively difficult since both ischemic and non-ischemic priapism may develop in the same patient.^{2,12} Also these priapism episodes of these patients who have sickle cell disease have no relation with other veno-occlusive crises observed and may not always be prone to erectile dysfunction.³⁹

In the study Burnett et al. made on 'Phosphodiesterase 5 (PDE5) Inhibitor Use in Recurrent Priapism' on 7 people, PDE5 inhibitor treatment was successful in decreasing or eliminating priapism recurrences in two weeks starting from the beginning of the treatment in 6 out of 7 patients. Priapism attacks started to decrease in 3-8th months of the treatment in 3 of these patients with idiopathic etiology and then the patients didn't continue their treatments. A long-term treatment lasting 17-24 months was required in three patients with treatment responding sickle cell anemia and it was reported that these patients are still continuing their treatment. When erectile function was compared to pre-treatment term, there was no change in 6 patients in the final follow-up examination and recovery was observed in one patient. PDE5 inhibitor treatment was tolerated well by all patients and no side effects were observed.⁴⁰

In a current study, Matlaga et al applied oral digoxin treatment to 13 recurrent priapism patients. The authors reported that 69% of the patients didn't have priapism episodes any more.³⁸

Filho et al.⁴¹ detected that new priapism episode was taken under control with maximum 3 mg/d dose in 23 patient they provided finasteride treatment. But we should emphasize that hormonal treatment has side effects such as ED and loss of libido. Also, hormonal agents constitute contraindication for people whose growth and sexual maturation are not complete. Finally, gabapentin was successfully applied in three recurrent priapism patients.⁴² Although the effect mechanism is not completely known, it is assumed that this event occurs by preventing the calcium efflux from flat muscle cells.

When the patient doesn't want oral treatment or when it fails, etilefrin or phenylephrine intracavernosal injection can be used. It was proven that intracavernosal injection of α -agonists are effective in lowering priapism episodes up to 10 years.⁴³ But this method should not be preferred to systemic treatment because priapism is treated instead of prevention in such cases.¹²

CONCLUSION

Since priapism is a condition with long term complications such as penile fibrosis and erectile dysfunction, it is among urological urgencies requiring early diagnosis and treatment. Conservative treatment in line with a certain algorithm should be planned primarily and surgical treatment should be planned if this is unsuccessful but current treatments should always be considered. I hope that the studies to be done in the future would be helpful to reveal priapism molecular mechanisms and develop our ability of care for the patients in this condition.

ACKNOWLEDGEMENTS

Funding: No funding sources

Conflict of interest: None declared

Ethical approval: Not Required

REFERENCES

1. Papadopoulos I, Kelâmi A. Priapus and priapism. From mythology to medicine. *Urol.* 1988;32(4):385-6.
2. Pryor J, Akkus E, Alter G, Jordan G, Leuret T, Levine L et al. Priapism. *J Sex Med.* 2004 ;1(1):116-20.
3. Shigehara K, Namiki M. Clinical Management of Priapism: A Review. *World J Mens Health.* 2016;34(1):1-8.
4. Salonia A, Eardley I, Giuliano F, Hatzichristou D, Moncada I, Vardi Y, et al. European Association of Urology guidelines on priapism. *Eur Urol.* 2014;65:480-9.
5. Cherian J, Rao AR, Thwaini A, Kapasi F, Shergill IS, Samman R. Medical and surgical management of priapism. *Postgrad Med J.* 2006;82(964):89-94.
6. Song PH, Moon KH. Priapism: current updates in clinical management. *Korean J Urol.* 2013;54(12):816-23.
7. Broderick GA, Kadioglu A, Bivalacqua TJ, Ghanem H, Nehra A, Shamloul R. Priapism: pathogenesis, epidemiology, and management. *J Sex Med.* 2010;7(1 Pt 2):476-500
8. Kulmala RV, Lehtonen TA, Tammela TL. Priapism, its incidence and seasonal distribution in Finland. *Scand J Urol Nephrol.* 1995;29(1):93-6.
9. McMahon CG. High flow priapism due to an arterial-la-cunar fistula complicating initial veno-occlusive priapism. *Int J Impot Res.* 2002;14(3):195-6.
10. Witt MA, Goldstein I, Saenz deTejada I, Greenfield A, Krane R. Traumatic laceration of intracavernosal arteries: The pathophysiology of nonischemic, high flow, arterial priapism. *J Urol.* 1990;143(1):129-32.
11. Rogers ZR. Priapism in sickle cell disease. *Hematol Oncol Clin North Am.* 2005;19(5):917-28.
12. Montague DK, Jarow J, Broderick GA, Dmochowski RR, Heaton JP, Lue TF, et al. American Urological Association Guideline on the management of priapism. *J Urol.* 2003;170(4 Pt 1):1318-24.
13. Levey HR, Kutlu O, Bivalacqua TJ. Medical management of ischemic stuttering priapism: a

- contemporary review of the literature. *Asian J Androl.* 2012;14(1):156-63.
14. Powell BL, Craig JB, Muss HB. Secondary malignancies of the penis and epididymis: A case report and the review of the literature. *J Clin Oncol.* 1985;3(1):110-6.
 15. Gordon SA, Stage KH, Tansey KE, Lotan Y. Conservative management of priapism in acute spinal cord injury. *Urol.* 2005;65(6):1195-7.
 16. Baba H, Maezawa Y, Furusawa N, Furusawa N, Kawahara N, Tomita K. Lumbar spinal stenosis causing intermittent priapism. *Paraplegia.* 1995;33(6):338-45.
 17. Habous M, Elkhoully M, Abdelwahab O, Farag M, Madbouly K, Altuwajri T, et al. Noninvasive treatments for iatrogenic priapism: Do they really work? A prospective multicenter study. *Urol Ann.* 2016;8(2):193-6.
 18. Lowe FC, Jarow JP. Placebo controlled study of oral terbutaline and pseudoephedrine in management of prostaglandin E1 induced prolonged erections. *Urol.* 1993;42:51-3.
 19. Burnett AL, Bivalacqua TJ. Priapism: new concepts in medical and surgical management. *Urol Clin North Am.* 2011;38(2):185-94.
 20. Kulmala RV, Tamella TL. Effects of priapism lasting 24 hours or longer caused by intracavernosal injection of vasoactive drugs. *Int J Impot Res.* 1995;7(2):131-6.
 21. Huang YC, Harraz AM, Shindel AW, Lue TF. Evaluation and management of priapism: 2009 update. *Nat Rev Urol.* 2009;6(5):262-71.
 22. Rutchik S, Sorbera T, Rayford RW, Sullivan J. Successful treatment of recalcitrant priapism using intercorporeal injection of tissue plasminogen activator. *J Urol.* 2001;166(2):628.
 23. Ebbelhøj J. A new operation for priapism. *Scand J Plast Reconstr Surg.* 1974;8(3):241-2.
 24. Winter CC. Cure of idiopathic priapism: new procedure for creating fistula between glans penis and corpora cavernosa. *Urol.* 1976;8(4):389-91.
 25. Lian W, Lv J, Cui W. Al-Ghorab Shunt plus intracavernous tunneling for prolonged ischemic priapism. *J Androl.* 2010;31(5):466-71.
 26. Burnett AL, Pierorazio PM. Corporal "snake" maneuver: corporoglanular shunt surgical modification for ischemic priapism. *J Sex Med.* 2009;6(4):1171-6.
 27. Kilinc M. Temporary cavernosal-cephalic vein shunt in low-flow priapism treatment. *Eur Urol.* 2009;56(3):559-62.
 28. Quackels R. Treatment of a case of priapism by cavernospongious anastomosis [in French]. *Acta Urol Belg.* 1964;32(1):5-13.
 29. Grayhack JT, McCullough W, O'Coner VJ Jr, Trippel O. Venous bypass to control priapism. *Invest Urol.* 1964;1(1):509-13.
 30. De Stefani S, Savoca G, Ciampalini S, Stener S, Gattuccio I, Belgrano. E. Urethrocutaneous fistula as a severe complication of treatment for priapism. *BJU Int.* 2001;88(6):642-3.
 31. Kandel GL, Bender LI, Grove JS. Pulmonary embolism: a complication of corpus-saphenous shunt for priapism. *J Urol.* 1968;99(2):196-7.
 32. Berger R, Billups K, Brock G, Broderick GA, Dhabuwala CB, Goldstein I, et al. Report of the AFUD Thought Leader Panel for evaluation and treatment of priapism. *Int J Impot Res.* 2001;13(5):39-43.
 33. Rees RW, Kalsi J, Minhas S, Peters J, Kell P, Ralph DJ. The management of low-flow priapism with the immediate insertion of a penile prosthesis. *BJU Int.* 2002;90(9):893-7.
 34. Kumar P, Minhas S, Brown C, Muneer A, et al. Ischemic priapism: Acute implant insertion and long-term follow-up. AUA annual meeting, abstrn no: 2005.1271.
 35. Monga M, Broderick GA, Hellstrom WA. Priapism in sickle cell disease: The case for early implantation of the penile prosthesis. *Eur Urol.* 1996;30(1):54-9.
 36. Ilkay AK, Levine LA. Conservative management of high-flow priapism. *Urol.* 1995;46(3):419-24.
 37. Ficarra V, Beltrami P, Sarti A, Rubilotta E, Righetti R, Malossini G. High flow priapism due to a bilateral arteriosinusoidal fistula. *Scand J Urol Nephrol.* 2001;35(5):418-9.
 38. Kadioğlu A, Şanlı Ö, Ersay A, Çakan M, Taşkapu HH, Akman T. Practical Management of Patients with Priapism EAU-EBU update series 4. 2006;4(4):150-60.
 39. Fowler JE, Koshy M, Strub M, Chinn SK. Priapism associated with sickle cell hemoglobinopathies: Prevalence, natural history and sequelae. *J Urol.* 1991;145(1):65-8.
 40. Burnett AL, Bivalacqua TJ, Champion HC, Musicki BJ. Feasibility of the Use of Phosphodiesterase Type 5 Inhibitors in a Pharmacologic Prevention Program for Recurrent Priapism. *J Sex Med.* 2006;3(6):1077-84.
 41. Rachid-Filho D, Cavalcanti AG, Favorito LA, Costa WS, Sampaio FJ. Treatment of recurrent priapism in sickle cell anemia with finasteride: a new approach. *Urol.* 2009;74(5):1054-7.
 42. Perimenis P, Athanasopoulos A, Papanthanasopoulos P, Barbaliás G. Gabapentin in the management of the recurrent, refractory, idiopathic priapism. *Int J Impot Res.* 2004;16(1):84-5.
 43. Teloken C, Ribeiro EP, Chammás M, Teloken P, Souto CAV. Intracavernosal etilefrine self-injection therapy for recurrent priapism: one decade of follow-up. *Urol.* 2005;65(5):1002.

Cite this article as: Sönmez MG, Kandemir A, Balasar M. Priapism: what to do. *Int J Adv Med* 2017;4:1495-1501.