

## Case Report

# Unusual case of nail in lung

Ashok P. Arbat<sup>1</sup>, Sameer A. Arbat<sup>1</sup>, Meenakshi S. Ghadge<sup>1</sup>, Jayshree J. Upadhye<sup>2\*</sup>

<sup>1</sup>Department of Pulmonology, KRIMS hospitals, Nagpur, Maharashtra, India

<sup>2</sup>Department of Obstetrics and Gynaecology, UCH, Nagpur, Maharashtra, India

**Received:** 01 October 2017

**Accepted:** 31 October 2017

### \*Correspondence:

Dr. Jayshree J. Upadhye,

E-mail: [jayshreeupadhye@gmail.com](mailto:jayshreeupadhye@gmail.com)

**Copyright:** © the author(s), publisher and licensee Medip Academy. This is an open-access article distributed under the terms of the Creative Commons Attribution Non-Commercial License, which permits unrestricted non-commercial use, distribution, and reproduction in any medium, provided the original work is properly cited.

### ABSTRACT

Tracheobronchial foreign body aspiration is a health problem that can be seen in all age groups, and it requires urgent diagnosis and intervention. We report an unusual case of nail in lung. 45 years old male was referred to us with history of aspiration of nail 2 Days back and cough. X-ray Chest PA view showed radio-opaque foreign body in right lung-lower zone. Patient had undergone bronchoscopy 2 days ago with report stating, "Normal study; No foreign body Seen" Counselling of the patient and relatives was done. Informed consent was taken. Under general anaesthesia with intubation, fluoroscopy guided video bronchoscopy was performed with external diameter 5.6mm and working channel 2mm. Foreign body was localized and removed It's an innovative technique with multi-disciplinary approach. Counselling of the patient and relatives is important.

**Keywords:** Bronchoscopy, Foreign body, Right lung

## INTRODUCTION

Foreign bodies in the tracheobronchial tree are the ones that provide more risk, owing to higher incidence of complications, including death, especially in those cases in which intervention takes longer.<sup>1</sup> We are reporting an unusual case of nail in lung.

Aspiration of foreign bodies through tracheostomy orifices is an uncommon occurrence, and there are few references in the literature. There are more difficulties detected when it is impossible to pass the bronchoscope through glottic space and it may be necessary to resort to flexible bronchoscopy, rarely effective for removal of foreign bodies, leading eventually to surgical removal by thoracotomy.<sup>1</sup>

Foreign-body aspiration is often a serious medical condition demanding timely recognition and prompt action. Delayed diagnosis and subsequent delayed

treatment is associated with serious, and sometimes fatal complications.<sup>2</sup>

Unlike foreign-body aspiration in young children and in the elderly, this is uncommon in adults. In the adult population, such aspiration is most commonly secondary to unconscious accidental ingestion during general anesthesia, sedation, intoxication, seizures or neurologic disorders affecting the oropharynx.<sup>2</sup>

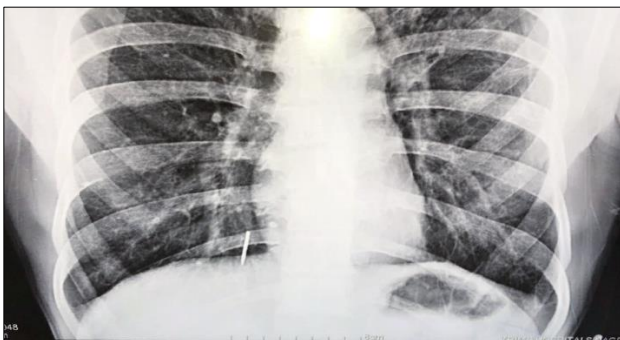The most common symptoms are choking followed by a protracted cough. Physical examination findings include fever, stridor, retractions, and decreased breath sounds. Radiographic imaging can be helpful if the object aspirated is radiopaque or if there are signs of hyperexpansion on expiration. Negative-imaging studies, however, do not exclude the presence of a foreign body in the airway. The longer a foreign body resides in the airway, the more likely it is to migrate distally. When this occurs, symptoms of chronic cough and wheezing may

mimic asthma like condition. Bronchoscopy is indicated in this situation to evaluate the airway thoroughly. If a foreign body is present, extraction can be performed with flexible or rigid bronchoscopy. If flexible bronchoscopy is attempted, it is imperative that the bronchoscopist is familiar with rigid bronchoscopy and has the equipment immediately available should danger to the airway occur. The procedure is generally safe and well tolerated. Many patients are managed under general anesthesia, but foreign bodies often can be removed with a flexible bronchoscope with the patient under local anesthesia. Surgery should be performed only as a last resort and rarely is necessary.<sup>3</sup>

Tracheobronchial foreign body (TFB) aspiration is rare in adults, although incidence rates increase with advancing age. Risk factors for TFB aspiration in adults are a depressed mental status or impairment in the swallowing reflex. Symptoms associated with TFB aspiration may range from acute asphyxiation with or without complete airway obstruction, to cough, dyspnea, choking, or fever. In adults, many other medical conditions mimic breathing abnormalities similar to those associated with TFB aspiration. If the history is not suggestive, then only a high index of suspicion can ensure proper diagnosis and timely removal of the foreign body. Initial treatment is airway support. Radiographic imaging may assist in localizing the foreign body. Bronchoscopic removal of the foreign body is necessary to avoid long-term sequelae. Flexible bronchoscopy is effective both in the diagnosis and removal of foreign bodies.<sup>4</sup>

The most common aspirated FBs by adults are organics, especially fragments of bones and seeds. Symptoms usually are cough, choking and dyspnea. Right localization, especially bronchus intermedius and right lower lobe, is more frequent. Chest radiography can be normal in up to 20% of the cases and FBs can be detected in 26% of the patients. FBs can be safely removed in the majority of patients under flexible bronchoscopy. Surgical treatment must be reserved for cases in which bronchoscope fails or there are irreversible bronchial or lung complications.<sup>5</sup>

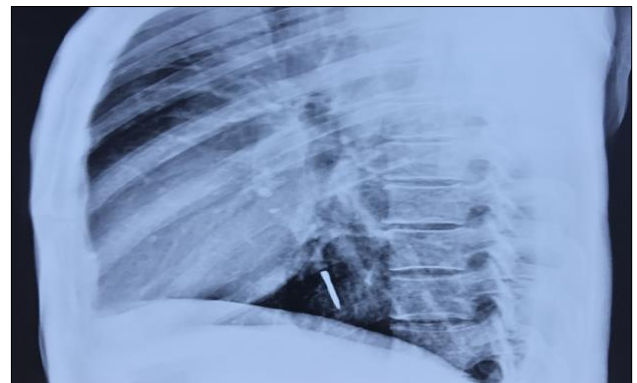### CASE REPORT



**Figure 1: X-ray chest PA view showing nail in right lung.**

45 years old male was referred to department of Pulmonology, KRIMS Hospitals, Nagpur, Maharashtra, India. He gave history of aspiration of nail 2 Days back. Since then he had cough. He was anxious regarding complications. There was no dyspnea or hemoptysis. There was no significant past history or co-morbidities.

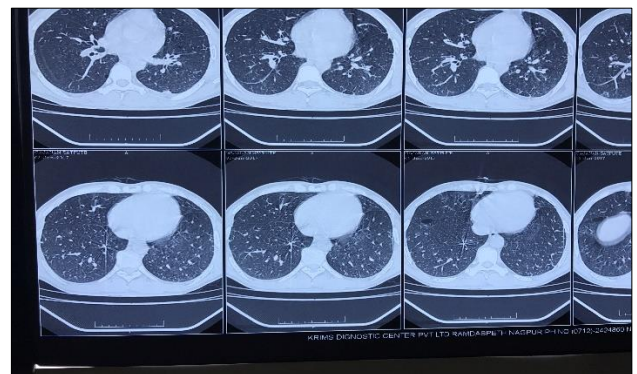
On Examination, there were no abnormal findings. X-ray Chest PA view showed radio-opaque foreign body in right lung-lower zone. It was medially placed with pointed end distally (Figure 1). X-ray Chest Lateral view showed radio-opaque foreign body in right lung in relation to right dome of diaphragm. (Figure 2) It is seen in medial segment of right lower lobe.



**Figure 2: X-ray chest lateral view showing nail in right lung.**

Patient had undergone bronchoscopy 2 days ago with report stating, “Normal study-No foreign body Seen” Bronchoscopy is technically difficult for this location. Also, as it was peripherally placed foreign body, there was risk of dislodgement.

Counselling of the patient and relatives was done. Informed consent for lobectomy or invasive surgery was taken. Risk of future complications including sepsis was explained. Cost was explained.



**Figure 3: CT scan showing nail.**

Under general anaesthesia with intubation, fluoroscopy guided video bronchoscopy was performed with external

diameter 5.6mm and working channel 2mm. Foreign body was localized through Fluoroscope. Toothed biopsy forceps were navigated under fluoroscopic guidance and foreign body was localized.

Bronchoscope could not be navigated beyond opening of right lower lobe bronchus. Approximate distance of foreign body from bronchoscope was 6 inches (Figure 3)

Forceps navigated till foreign body under fluoroscopy guidance with multiple attempts

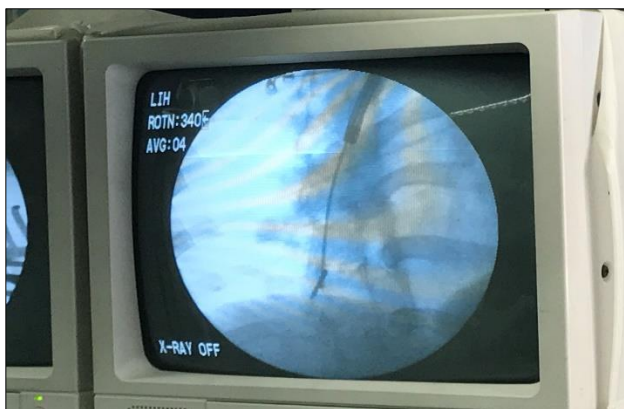
As bronchoscopy is a blind procedure, it was difficult to navigate and open forceps in small sub segments. Also, it was difficult to grip foreign body. There was risk of further injury to bronchial tree and risk of dislodgement.

As external diameter of forceps was equal to the external diameter of the foreign body i.e. 2mm, maximum range of opening for the forceps was achieved, nail was caught only under fluoroscopy guidance and the nail was removed.

It was flat nail with no cap of approximate length 2.5 cm and diameter of 2mm. It's pointed end was lodged distally and rusting/corrosion was seen.

Post procedure, extubation was done and patient was kept under observation. He was discharged next day on antibiotics.

It's an innovative technique with multi-disciplinary approach in a set up with back up and resourceful machinery. Counseling of the patient and relatives is of utmost importance.



**Figure 4: Fluoroscopy showing nail.**

## DISCUSSION

Foreign-body aspiration is often a serious medical condition demanding timely recognition and prompt action. In adults, however, foreign-body aspiration can be tolerated and remain undetected for a long time. Figueiredo RR reported that foreign bodies in the

tracheobronchial tree are rare occurrences, more common in pediatric emergency rooms.<sup>1</sup>

We describe a case in which there was delayed diagnosis inspite the patient giving history of aspiration of foreign body. He only had cough.

Figueiredo RR reported that clinical picture is normally characterized by cough, wheezing, snoring, dyspnea and tracheal symptoms, if the foreign body is located in the trachea. The patient may present with fever and mucopurulent expectoration in case of associated pneumonia and progressive dyspnea, which may get as bad as respiratory failure.<sup>1</sup>

Qureshi A et al reported a case in which there was hemoptysis after aspiration of a large foreign body.<sup>2</sup>

Moura e Sá J et al reported the most common clinical presentations as acute asphyxia in 28%, persistent cough 22%.<sup>6</sup>

Hasdiraz L found that the availability of both rigid and flexible bronchoscopy should be emphasized since larger aspirates may not be retrievable with a flexible bronchoscope. Surgery constitutes the final, definitive option and is generally well tolerated, particularly when the lung parenchyma is spared.<sup>7</sup>

Ramos MB et al found that acute or recurrent infection was the most frequent clinical presentation.<sup>8</sup>

Loh TL reported a case of fracture of tracheostomy tubes with subsequent aspiration of the fragment into the airway.<sup>9</sup>

Figueiredo RR reported that the most frequent aspirated objects are seeds, beans, rice and peanuts, and small metal and plastic objects, such as fragments or parts of toys.<sup>1</sup> Moura e Sá J et al reported the nature of FB as bone fragments 33%, vegetable matter 31%.<sup>6</sup>

Ramos MB et al found that the most common FB aspirated were inorganic (pins and plastic devices).<sup>8</sup>

Malhotra B et al also reported a case of an adult female in whom the broken tracheostomy tube entered the right main bronchus and was removed by fiberoptic bronchoscopy under topical anaesthesia.<sup>10</sup>

Blanco AM also reported a case in which there was hemoptysis after aspiration of a foreign body.<sup>11</sup> Our patient gave history of aspiration of a nail.

In our patient, X-ray Chest PA view showed radio-opaque foreign body in right lung-lower zone.

Figueiredo RR reported that the main complementary exam is simple chest x-ray in PA, in which the 3 main findings are:

- Image of foreign body, if radiopaque;
- Suggestive images of atelectasia, such as deviation of mediastinum and diaphragm;
- Images suggestive of emphysema by vascular mechanism, such as hyperinsufflation.<sup>1</sup>

Ramos MB et al found that chest radiographs provided data for diagnosis in 68% of the cases.<sup>8</sup> Moura e Sá J et al reported that the majority of FBs (61%) were lodged in the right bronchial tree; 26% were radiopaque.<sup>6</sup>

In our patient, computed tomography was done to see exact location of the nail. Moura e Sá J et al found that Computed tomography of the chest may be valuable in identifying small aspirated objects or when associated chest disease is suspected. Bronchoscopy is frequently both diagnostic and therapeutic.<sup>6</sup>

In our patient, under general anaesthesia with intubation, fluoroscopy guided video bronchoscopy was performed. Foreign body was localized through fluoroscope. Toothed biopsy forceps were navigated under fluoroscopic guidance and foreign body was removed.

Moura e Sá J et al reported that rigid bronchoscopy was performed in 75 cases and fiberoptic bronchoscopy in only two. Two patients needed two bronchoscopies for FB removal. There were no complications, need for surgery or relevant sequelae.<sup>6</sup>

Hasdiraz L found that the availability of both rigid and flexible bronchoscopy should be emphasized since larger aspirates may not be retrievable with a flexible bronchoscope. Surgery constitutes the final, definitive option and is generally well tolerated, particularly when the lung parenchyma is spared.<sup>7</sup> Our patient tolerated the procedure well. There were no complications.

## CONCLUSION

Appropriate and on time clinical intervention makes the diagnosis to be easier. Treatment timing and methods are important to prevent the complications. With multi-disciplinary approach in a set up with back up and resourceful machinery, our patient could be managed well without any complications. Counseling of the patient and relatives is important.

*Funding: No funding sources*

*Conflict of interest: None declared*

*Ethical approval: Not required*

## REFERENCES

1. Figueiredo RR, Machado WS. Foreign body aspiration through tracheotomy: a case report. *Rev. Bras. Otorrinolaringol.* 2005;71(2):234-6.
2. Qureshi A, Behzadi A. Foreign-body aspiration in an adult. *Canad J Surg.* 2008;51(3):E69-70.
3. Swanson KL, Edell ES. Tracheobronchial foreign bodies. *Chest Surg Clin N Am.* 2001;11(4):861-72.
4. Boyd M, Chatterjee A, Chiles C, Chin R. Tracheobronchial foreign body aspiration in adults. *South Med J.* 2009;102(2):171-4.
5. Blanco Ramos M, Botana-Rial M, García-Fontán E, Fernández-Villar A, Gallas Torreira M. Update in the extraction of airway foreign bodies in adults. *J Thorac Dis.* 2016;8(11):3452-6.
6. Moura e Sá J, Oliveira A, Caiado A. Tracheobronchial foreign bodies in adults — experience of the Bronchology Unit of Centro Hospitalar de Vila Nova de Gaia. *Rev Port Pneumol.* 2006;12:31-43.
7. Hasdiraz L, Bicer C, Bilgin M. Turban pin aspiration: non-asphyxiating tracheobronchial foreign body in young Islamic women. *Thorac Cardiovasc Surg.* 2006;54:273-5.
8. Ramos MB, Fernández-Villar A, Rivo JE, Leiro V, García-Fontán E, Botana MI, et al. Extraction of airway foreign bodies in adults: experience from 1987-2008. *Interact Cardiovasc Thorac Surg.* 2009;9(3):402-5.
9. Loh TL, Chin R, Flynn P, Jayachandra S. Fracture and aspiration of a tracheostomy tube. *BMJ Case Rep.* 2014;2014:bcr2013203232.
10. Malhotra B, Kallan BM. An unusual foreign body in tracheobronchial tree: removed by fiberoptic bronchoscope. *Ind J Chest Dis Allied Sci.* 1993;35(2):85-8.
11. Blanco Aparicio M, Vereá H, Martínez Lago V. Hemoptysis caused by endobronchial foreign body. *Arch Bronconeumol.* 1995;31(2):93-4.

**Cite this article as:** Arbat AP, Arbat SA, Ghadge MS, Upadhye JJ. Unusual case of nail in lung. *Int J Adv Med* 2017;4:1709-12.