

Original Research Article

Pneumothorax in the cases of silicosis in southern part of Rajasthan

Rishi K. Sharma, Atul Luhadia*, Shanti K. Luhadia, Yash Mathur, Harshil Pandya,
Prithviraj Methe

Department of Respiratory Medicine, Geetanjali Medical college and Hospital, Udaipur city, Rajasthan, India

Received: 10 October 2017

Accepted: 13 October 2017

*Correspondence:

Dr. Atul Luhadia,

E-mail: atulluhadia124@gmail.com

Copyright: © the author(s), publisher and licensee Medip Academy. This is an open-access article distributed under the terms of the Creative Commons Attribution Non-Commercial License, which permits unrestricted non-commercial use, distribution, and reproduction in any medium, provided the original work is properly cited.

ABSTRACT

Background: Silicosis is an occupational lung disease caused by inhalation of dust containing crystalline silica particles of size 0.5-5 microns in diameter. It commonly occurs in workers involved in quarrying, mining, sandblasting, tunneling, foundry work and ceramics. Pneumothorax is one of the complications of silicosis. The occurrence of pneumothorax in a patient with silicosis is a rare event, but it may be fatal. The incidence of secondary spontaneous pneumothorax (SSP) in silicosis as such is not known. This study aims to report the cases of secondary spontaneous pneumothorax in patients of silicosis in Southern part of Rajasthan.

Methods: 50 patients of silicosis established by historical, clinical evaluation and radiological evidence with increased dyspnoea were included in the study. In all patients Chest X ray was done immediately.

Results: Among 50 patients of silicosis with increased dyspnoea, Chest X ray showed pneumothorax in 20 patients of which 4 had bilateral pneumothorax, 7 had right pneumothorax and 9 had left pneumothorax. The mean duration of exposure to silica particles was 10 years (5 to 15 years). All the patients had various degrees of dyspnoea and chest pain. Tube thoracostomy was performed in 15 patients while 5 patients were managed conservatively with oxygen and bronchodilators.

Conclusions: Our study showed an increased incidence of secondary pneumothorax in silicosis patients. The occurrence of pneumothorax, though rare in silicosis is a potentially life-threatening complication and may cause serious morbidity and mortality. The patients of silicosis who develop sudden onset of dyspnoea should be promptly investigated for this complication.

Keywords: Dyspnoea, Secondary spontaneous pneumothorax, Silicosis, Silica particles

INTRODUCTION

Silicosis is an occupational lung disease caused by the inhalation and accumulation of crystalline silica particles in the lung.¹ It is the most prevalent type of pneumoconiosis.^{2,3} It is characterized by symptoms of shortness of breath, cough, chest pain. It commonly occurs in workers involved in quarrying, mining, sandblasting, tunneling, foundry work and ceramics. Exposure to large amounts of free silica can go unnoticed because silica is odorless, non-irritant and does not cause

any immediate health effects. As silicosis is incurable, clinical management includes removing the worker from the industry and giving symptomatic treatment. Public health goals are to detect early cases through monitoring of currently and formerly exposed workers, to establish surveillance programmes, to slow progression and to reduce disability.

Pleural involvement, including pleural effusion, pleural thickening, or pneumothorax, is rarely seen in silicosis. Pneumothorax is one of the most important complications

of silicosis associated with pleura. In silicosis, the pneumothorax is usually unilateral and may be fatal.^{4,6} This study aims to report secondary spontaneous pneumothorax (SSP) in silicosis patients.

METHODS

50 patients of silicosis who visited chest OPD at Geetanjali Hospital, Udaipur with increased symptoms of dyspnoea and chest pain were enrolled in the study. Such patients with history of working in stone mines and radiological evidence of silicosis were thoroughly interrogated regarding occupation, nature of work, duration of exposure to dust and silica particles before inclusion in the study. These patients were working in the mines near Udaipur region in Rajasthan. In all the cases, pneumothorax was diagnosed clinically by auscultation and then confirmed radiologically by recent Chest X-ray.

RESULTS

Among 50 patients of silicosis, 45 were males and 5 patients were females. 30 male patients had history of smoking. The mean duration of exposure to silica particles was 10 years (5 to 15 years). All the patients were diagnosed on basis of occupational, historical, clinical and radiological evaluation. All of the patients had varying degrees of dyspnoea and chest pain which were increased recently. Chest X rays of all patients revealed bilateral, widespread reticulonodular and nodular appearances. Bilateral hilar popcorn calcification was seen in 1 patient.

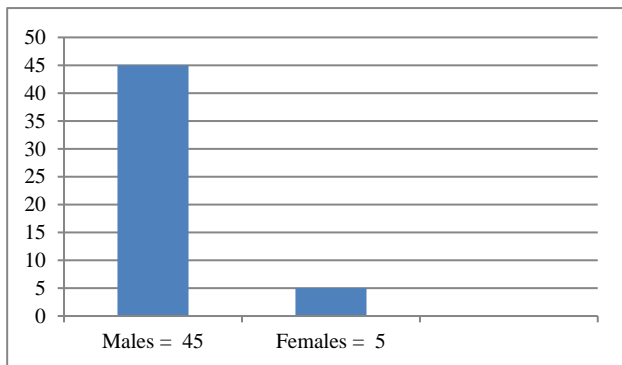


Figure 1: No. of male and female patients of silicosis.

Progressive massive fibrosis lesions were seen in 10 patients who had history of long and continuous exposure to silica particles. Pneumothorax was seen bilaterally in 4 cases, right side in 7 cases and left side in 9 cases. So, the overall incidence of pneumothorax among silicosis patients was 40% (20/50) which is higher as compared to the evidences till now. All the patients who developed pneumothorax were smokers. Tube thoracostomy was performed in 15 patients while 5 patients with minimal pneumothorax were managed conservatively with oxygen and bronchodilators.

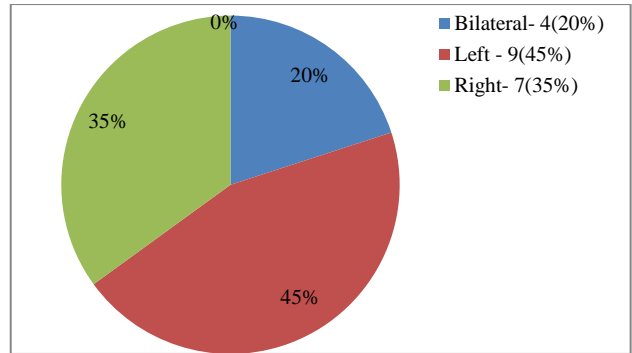


Figure 2: Pie diagram showing pneumothorax cases according to side.

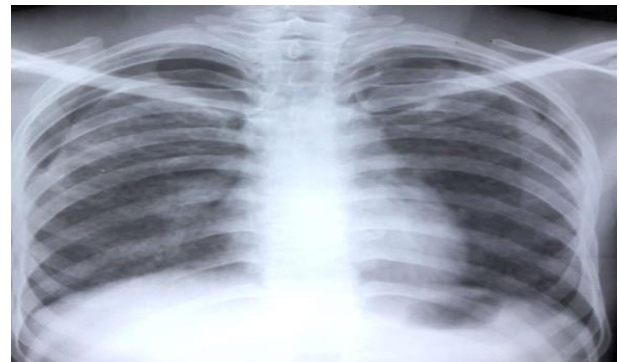

Figure 3: Cxray 1- Bilateral minimal pneumothorax.

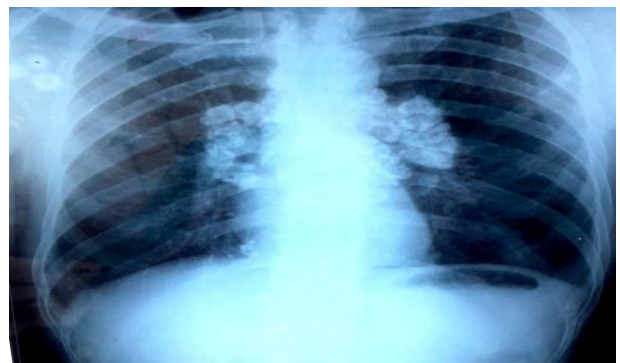

Figure 4: Cxray 2- Bilateral hilar popcorn calcification.

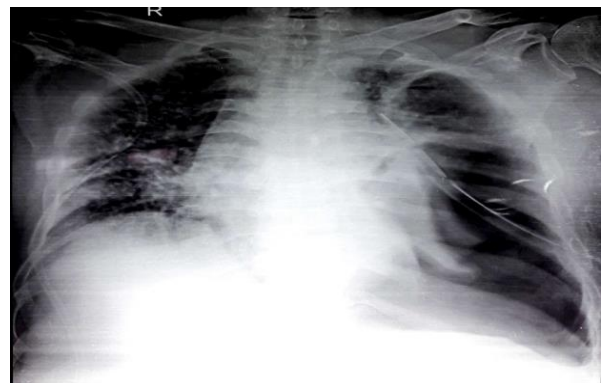

Figure 5: Cxray 3- Left pneumothorax with ICD

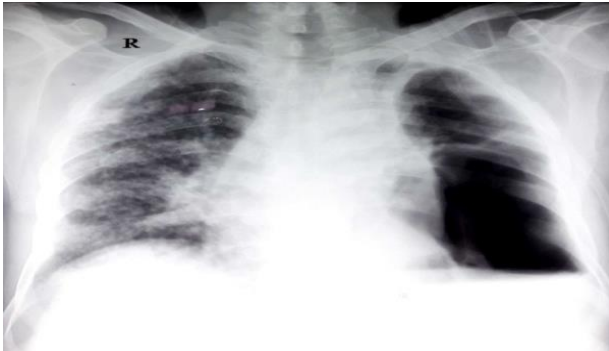

Figure 6: Cxray 4-Left pneumothorax.

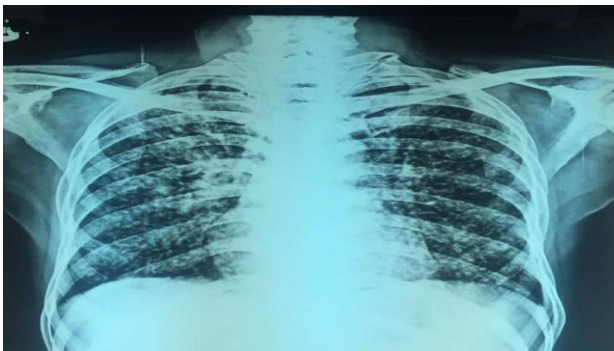


Figure 7: Cxray 5- B/L nodular opacities.

DISCUSSION

Silicosis commonly occurs in workers involved in quarrying, mining, sandblasting, tunneling, foundry work, and ceramics industry.⁷ Respirable crystalline silica is < 10 micron in diameter and it can reach to the basal segments of the lung. It accumulates and induces silicosis although the exposure is low.⁸ There are three types of clinical and pathological forms of silicosis, based on the intensity and duration of exposure- acute, accelerated and chronic form. The acute form is caused by substantial exposure to silica and usually manifests within 2 years after the initial exposure. The accelerated form develops between 2 to 10 years of exposure. In the chronic form, symptoms will appear after more than 10 years of exposure. Our cases fell in the category of accelerated and chronic forms of silicosis with mean exposure of around 10 years.

Silicosis is associated with pulmonary and systemic co-morbidities. Some co-morbidities that have been documented in silicosis are tuberculosis, chronic obstructive pulmonary disease (COPD), lung cancer etc.⁹ Pneumothorax is a rare complication of silicosis. Most cases are unilateral, which are related to chronic silicosis with progressive massive fibrosis. There are only a few cases of bilateral pneumothorax that have been reported.^{5,6,10} The incidence of SSP in silicosis as such is not known. In our study 4 patients had bilateral pneumothorax, 7 patients had right side pneumothorax and 9 patients had left side pneumothorax. So, the overall

prevalence of pneumothorax was 40% (20/50), which is higher as compared to the evidences till now. All the patients with pneumothorax in our study were known smokers. So, smoking could be one of the etiological factor for SSP in our study. Though it remains unclear whether smoking predisposes exposed miners to silicosis or nonspecific radiographic changes from smoking are misinterpreted as silicosis.¹¹ Mohebbi et al reported that in acute and accelerated silicosis, there is a significant association between the presence of bulla and secondary spontaneous pneumothorax.¹²

As in other cases of SSP, pneumothorax in silicosis patients requires an aggressive approach to treatment. However, there is no accepted consensus for the treatment. In our study, Tube thoracostomy was performed in 15 patients while 5 patients with minimal pneumothorax were managed conservatively with oxygen and bronchodilators.

CONCLUSION

Our study showed an increased prevalence of secondary pneumothorax in silicosis patients. Smoking may be a risk factor for development of pneumothorax. Pneumothorax in silicosis patients can cause serious morbidity and mortality. Although the occurrence of SSP is rare in silicosis, but whenever chest pain and dyspnoea occur suddenly or has increased recently in a silicosis patient, the patient should be promptly investigated and pneumothorax should be kept in mind.

ACKNOWLEDGEMENTS

Authors would like to thank Radiology department and X-ray technician for their help in providing x-ray films on urgent basis.

Funding: No funding sources

Conflict of interest: None declared

Ethical approval: Not required

REFERENCES

1. American Thoracic Society. Adverse effects of crystalline silica exposure. *Am J Respir Crit Care Med.* 1997;155:761-8.
2. Cullinan P, Reid P. Pneumoconiosis. *Prim Care Respir J.* 2013;22(2):249-52.
3. Gupta A. Silicosis-an uncommonly diagnosed common occupational disease. *Icmr bull.* 1999; 29(9):1-7.
4. Kaynar H, Ayidin Y, Akgun M, Turkyimaz A, Eroglu A. Pneumothorax in the cases with silicosis due to denim sandblasting. *Turk Gogus Kalp Dama.* 2012;20(2):291-4.
5. Gupta KB, Manchanda M, Kaur P. Bilateral spontaneous pneumothorax in silicosis. *Indian J Chest Dis Allied Sci.* 2006;48(3):201-3.

6. Rao S, Rau PV. Bilateral spontaneous pneumothorax in silicosis. *Indian J Chest Dis Allied Sci.* 1993;35:47-9.
7. Castranova V, Vallyathan V. Silicosis and Coal worker's Pneumoconiosis. *Environ Health Perspect.* 2000;108:675-84.
8. Si S, Carey RN, Reid A, Driscoll T, Glass DC, Peters S, et al. The Australian Work Exposures Study: Prevalence of occupational exposure to respirable crystalline silica. *Ann Occup Hyg.* 2016;60(5):631-7.
9. Barboza CE, Winter DH, Seiscento M, Santos UP, Terra FM. Tuberculosis and silicosis: epidemiology, diagnosis and chemoprophylaxis. *J Bras Pneumol.* 2008;34(11):959-66.
10. Mishra P, Jacob SE, Basu D, Panigrahi MK, Govindaraj V. Bilateral spontaneous pneumothorax in chronic silicosis: a case report. *Case Rep Pathol.* 2014;561861.
11. Hessel PA, Gamble JF, Nicolich M. Relationship between silicosis and smoking. *Scand J Work Environ Health.* 2003;29(5):329-36.
12. Mohebbi I, Hassani E, Salarilak S, Bahrami AR. Do bullae and emphysema increase risk of pneumothorax in silicosis? *Indian J Occup Environ Med.* 2007;11(3):108-12.

Cite this article as: Sharma RK, Luhadia A, Luhadia SK, Mathur Y, Pandya H, Methe P. Pneumothorax in the cases of silicosis in southern part of Rajasthan. *Int J Adv Med* 2017;4:1547-50.