

Original Research Article

Study of neurological manifestations in patients of falciparum malaria

Malati Murmu, Ayaskanta Kar*, Karun Mahesh KP, Manoranjan Naik, Rajesh Kumar Meher

Department of Medicine, VSS Institute of Medical Sciences and Research, Burla (Sambalpur), Odisha, India

Received: 05 January 2018

Accepted: 15 January 2018

***Correspondence:**

Dr. Ayaskanta Kar,

E-mail: drayaskanta@gmail.com

Copyright: © the author(s), publisher and licensee Medip Academy. This is an open-access article distributed under the terms of the Creative Commons Attribution Non-Commercial License, which permits unrestricted non-commercial use, distribution, and reproduction in any medium, provided the original work is properly cited.

ABSTRACT

Background: Several types of neurological manifestations are associated with falciparum malaria. Cerebral malaria is one of the most dreaded complications. A significant number of survivors are left with disabling neurological sequelae, most of which are self-limiting. Neurological involvement is more frequent with falciparum malaria because of its unique characteristics leading to micro-vascular involvement.

Methods: Present study was conducted at department of General Medicine, VIMSAR, Burla (Odisha). This observational study included in total 110 patients, who were confirmed cases of falciparum malaria. Clinical profile including detailed neurological examination with relevant investigations was done. Spectrum of neuropsychiatric manifestations were observed.

Results: Out of 110 patients male and female ratio was 1:1 (M 55 and F 55). The mean age of presentation in male was 36.09 + 14.85 yrs. and in female was 31.85 + 14.00 yrs. The major presenting symptoms were fever, headache, vomiting, altered sensorium, altered behaviour and convulsions in their decreasing order of frequency. On neurological evaluation, diminished level of consciousness was found in 56.4% cases. 14% cases had GCS score \leq 7 and 63% had GCS score \geq 11. Convulsion was found in 31% cases, cranial neuropathy in 10.9%, cerebellar dysfunction in 12.7%, neck rigidity in 22.7%, speech abnormality in 3.6%, peripheral neuropathy in 8.2%, fundoscopic changes suggestive of retinal involvement in 44.5% cases. Atypical manifestation like; Intracerebral haemorrhage, subarachnoid haemorrhage, cortical venous sinus thrombosis were also found in few cases. 32.72% patients had Neuropsychiatric manifestations at discharge in the form of focal neurological deficits, psychosis, depression, speech disorder, memory loss, cerebellar abnormality & peripheral neuropathy.

Conclusions: Neurological manifestations in falciparum malaria patients are common and encompass a wide spectrum of clinical presentation. In an endemic area, falciparum malaria should be kept as a differential diagnosis in patients presenting with atypical neurological manifestations.

Keywords: Falciparum malaria, Neuropathy, Sensorium

INTRODUCTION

Malaria, a disease of antiquity, has proved to be a formidable deterrent to the cultural and socioeconomic progress of man in tropical, subtropical and monsoon prone zones of the world. In India, there were about 1.2 million malaria cases (0.71 million due to *P. falciparum*) and 331 malaria deaths in 2016.¹ Odisha is a stronghold

of malaria in India. The official reports for 2016 states 40% cases and 23% deaths caused by Malaria in the country are from Odisha.¹

Plasmodium falciparum is most commonly associated with neurological complications. Several neurological complications are associated with complicated and severe falciparum malaria, of which cerebral malaria has been well described; however, the other neurological

complications of falciparum malaria have received relatively little attention. Isolated case reports like peripheral neuropathies, various movement disorders, cerebellitis and stroke have been described.²⁻⁵

VSS Institute of Medical Sciences and Research (VIMSAR) is a tertiary care referral hospital in Burla, Odisha where patients come from highly endemic region of falciparum malaria of Western Odisha and adjoining Chhattisgarh. The current study is aimed to observe the various typical and atypical neurological manifestations and neurological sequelae / outcome in falciparum malaria patients.

METHODS

Study area

This study was conducted in department of Medicine, VIMSAR, BURLA, a tertiary care hospital in western Odisha situated in outskirts of Sambalpur city.

Study design

This was a hospital based observational study. The duration of this from October 2015 to October 2017. All patients were informed about the study and informed consent was obtained. Approval of institutional ethical committee was taken.

Study population

Study included total of 110 confirmed cases of falciparum malaria admitted in hospital.

Inclusion criteria

Patients tested positive for falciparum malaria (either by peripheral smear or rapid diagnostic test) and treated in the dept. of medicine in the age group of 14 years and above having neurological manifestations were included.

Exclusion criteria

Patients with pre-existing neurological disease, those infected with mixed species of plasmodia, those with Dengue serum NS1 antigen &/or IgM antibody positive and malaria during pregnancy were excluded from the study.

Data collection: The study subjects were screened using a structured questionnaire regarding symptom onset and progression. Collection of data was done in a friendly atmosphere after obtaining informed consent from patient or attendant.

Vital parameters were assessed, level of consciousness was noted and GCS score was calculated. Other investigations like complete blood count, blood urea,

serum creatinine, serum electrolytes, random blood sugar and viral markers for HIV, HBV and HCV were done.

Detailed neurological examination was done including fundoscopic examination in all study patients. Investigations for neurological diagnosis like CT scan and MRI of brain, Electroencephalogram, Nerve conduction study, CSF study were done in selected patients.

A case sheet proforma was prepared and data (demographic profile, clinical features, investigations, treatment and complication) from all study patients were filled and analysed. Severe falciparum malaria was diagnosed as per guidelines of WHO. Correlation between degree of parasitemia and presence of neurological manifestation at the time of discharge was done.

RESULTS

110 confirmed cases of falciparum malaria mono-infections were included in this study, in which 63 patients were complicated & 47 patients were uncomplicated falciparum malaria. Out of 110 cases, 55 were male and 55 were female with male to female ratio was 1:1.

The bulk of cases were from the age range 15-35 years contributing for 66 (60%) cases. Our study showed maximum incidence of falciparum malaria in both male and female belonging to age group of 15-25 years (Male: 16, Female: 25). The mean age of presentation in male was 36.09 ± 14.85 years and that of female was 31.85 ± 14.00years.

Fever in association with chills and rigors was observed in all 110 (100%) patients. Headache was another most important symptom in our study which is seen in 80% of patients. Vomiting was seen in 75.5% cases.

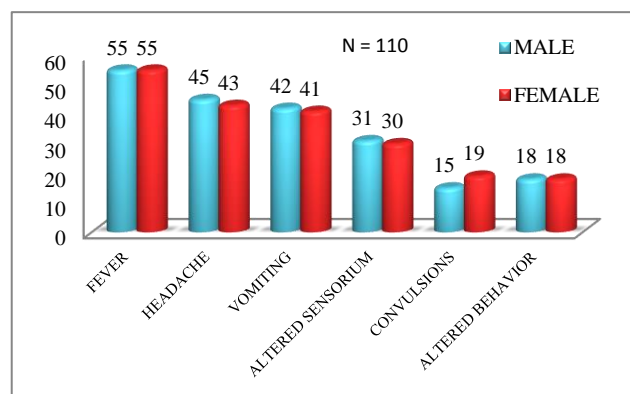


Figure 1: Sex wise distribution of study subjects based on presenting symptoms.

Pallor was noted on general physical examination in 35.5% cases. Icterus was noted in 25.5% of our cases.

Hypotension (systolic BP <80mmHg with capillary refill >2 secs) was found in 13.7% cases. An impaired level of consciousness was seen in 56.4% of cases. This group includes drowsy, stuporous and comatose in 20%, 21.8% and 14.6% of cases respectively.

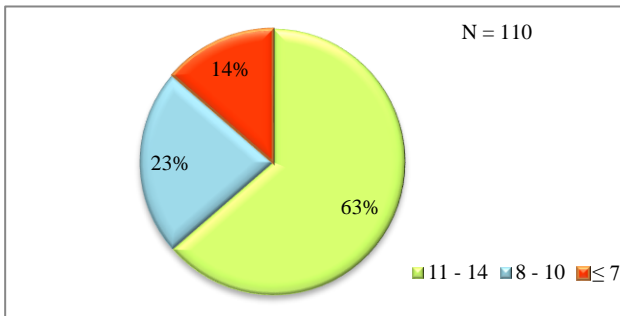
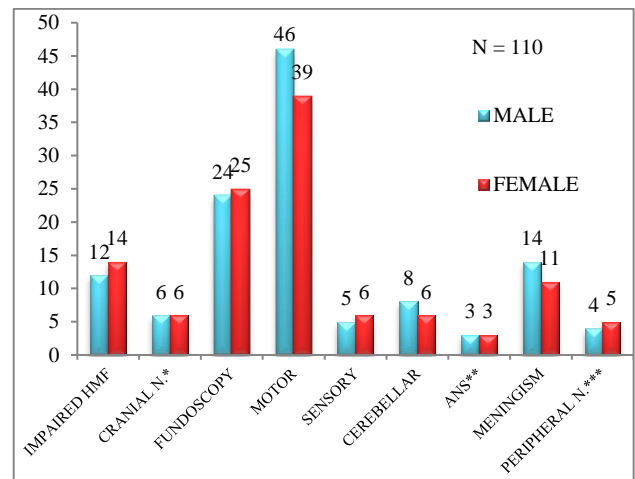


Figure 2: Distribution of study subjects based on Glasgow Coma Scale (GCS) score.

As per WHO definition, the incidence of cerebral malaria in our study was 16 (14.2%) cases. All 16 patients were unconscious at the time of admission, level of coma as assessed by GCS (Glasgow Coma Scale) was less than 7 (Figure 2). There were totally 38(34.5%) cases who were clinically diagnosed as cerebral malaria. Out of all 110 cases GCS score ≥ 11 was found in 63% cases and ≤ 7 in 14% cases and 8 – 10 in 23% cases. Our study observed convulsion in cerebral malaria in 34 (31%) cases. We found 26 (23.63%) cases with impaired higher mental function & abnormal behaviour in the form of depression, confusion, paranoid and manic syndrome & delirium. Cranial neuropathies were noticed among 12 cases (10.9%). Oculomotor nerve palsy was seen in 4 cases. Bilateral abducent nerve palsy seen in 4 cases. Glossopharyngeal & Vagus nerve abnormality in the form of impaired GAG reflex was seen in 4 cases. 2 cases had upper motor neuron (UMN) type of Trigeminal nerve palsy with exaggerated jaw jerk. All of these cases were a part of cerebral malarial encephalopathy. 1 female patient had diminution of vision in one eye attributed for retrobulbar neuritis. Malaria retinopathy: The retina of the eye is considered as part of the nervous system, and it is the only part that can be seen with the naked eye without opening the body. Fundoscopy was done in all 110 patients. A Fundoscopy change in retina was noticed in 49 patients (44.5%). Direct ophthalmoscope was used; as it was done bedside, doubtful cases were taken for indirect ophthalmoscope. 4 different patterns of retinal changes were noticed. Retinal whitening (RW), Retinal haemorrhage (H), papilloedema (P) & Vessel whitening (VW). Conjugated deviation of eyes was seen in 3 (2.7%) patients. Roving eye movements are usually an indication of light coma and are a poor localizing sign. This sign was positive in 23 (20.9%) patients. Motor system involvement was seen in 85 patients, decreased power was seen in 64 cases. Out of 34 patients with hypertonia, 5 (4.5%) had extrapyramidal rigidity & 3(2.7%) had decorticate rigidity. Hypotonia was seen in 20 patients.

Exaggerated & diminished reflexes were seen in 39 & 13 cases respectively.

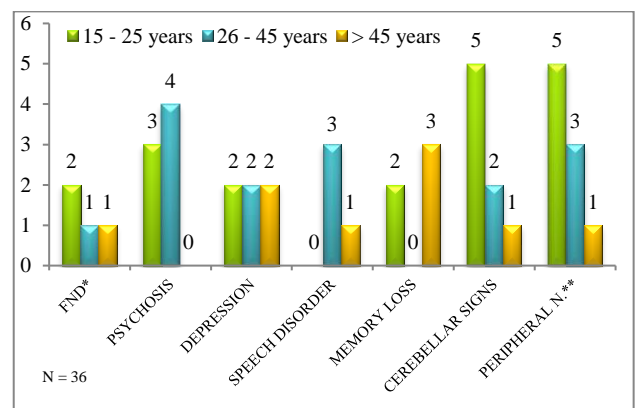
Extensor plantar response was noted in 46 patients. Cerebellar dysfunction was found in 12.7% at the time of presentation. Neck rigidity (meningism) was observed in 25 (22.7%) patients (Figure 3) We found diffuse subarachnoid haemorrhage and intracerebral haemorrhage in 2 patients. We found 1 patient with cerebral venous thrombosis.



*Cranial Neuropathies, **Autonomic Nervous System, ***Peripheral Neuropathy

Figure 3: Sex wise distribution of study subjects based on neurological findings at the time of admission.

At the time of discharge, Focal neurological deficits (3.6%) were seen in the form of hemiparesis in 1 patient and quadriplegia in 3 patients. Psychosis after treatment, at the time of discharge was seen in 7 patients (6.3%). Depression was seen in 5.5% of patients. We found speech disorder in 3.6% patients. Memory loss was observed in 4.5% patients. Cerebellar signs were noted among 7.4% of patients. Peripheral neuropathy of axonal type was noted in 8.2% patients (Figure 4 and Table 1).



*Focal Neurological Deficit, **Peripheral Neuropathy

Figure 4: Age wise distribution of study subjects based on neurological manifestations at the time of discharge.

Table 1: Age and Sex wise distribution of study subjects based on neuropsychiatric manifestations at the time of discharge (n=36).

Neuropsychiatric manifestations at discharge	15 – 25 years		26 – 45 years		> 45 years		Total
	Male	Female	Male	Female	Male	Female	
FND*	1	1	0	1	1	0	4 (3.6%)
Psychosis	2	1	2	2	0	0	7 (6.3%)
Depression	1	1	0	2	2	0	6 (5.5%)
Speech disorder	0	0	2	1	0	1	4 (3.6%)
Memory loss	0	2	0	0	3	0	5 (4.5%)
Cerebellar signs	1	4	1	1	1	0	8 (7.4%)
Peripheral N.**	2	3	1	2	1	0	9 (8.2%)

*FND: Focal Neurological Deficit, ** Peripheral Neuropathy

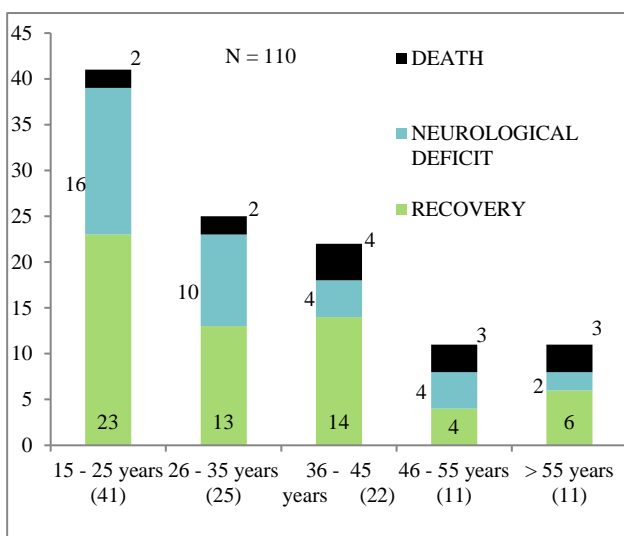


Figure 5: Age wise distribution of study subjects based on outcome at the time of discharge.

DISCUSSION

Out of 110 patients studied, 55 were male and 55 were female with male to female ratio 1:1. But this variation is not true reflection of the incidence of the disease, as the study material is highly selective and hospital based and also included small number of cases. A study in Myanmar reports that men and women are at equal risk of contracting malaria through exposure to mosquitoes.⁶

The patients belong to all age group, the bulk of cases were from the age range 15 – 35 years contributing for 66 (60%) cases. Our study showed maximum incidence of falciparum malaria in male and female belonging to age group 15-25 years (Male: 16, Female: 25). According to data from Malawi, adolescent girls had significantly higher parasite rates than women over 19 years of age.⁷ The mean age of presentation in male was 36.09 ± 14.85 years & that of female was 31.85 ± 14.00 years. Our study reported lowest incidence in the age group > 45 years (20%), SS Dash et al., also reported 12.5% in his study.⁸

Table 2: Comparison between current study and other studies in terms of presenting symptoms.

Presenting symptoms	Present study %	SS Dash et al ⁸ %	VC Patil ⁹ %	Preetam NW et al ¹⁰ %	VB Singh et al ¹¹ %	Mishra SK et al ¹² %	Bajiya HN et al ¹³ %
Fever	100	100	100	100	--	97.7	--
Headache	80	37.5	14.89	6.25	15.32	30.8	--
Vomiting	75.5	72.5	19.14	12.5	--	54.6	--
Altered sensorium	56.4	27.5	8.5	17.5	18.01	--	--
Convulsions	31	17.5	8.5	1.25	4.55	17.1	21.62

Fever was the most common clinical presentation found in our study. 110 (100%) cases presented with fever in association with chills and rigors which is very much similar to study by SS Dash et al (100%), VC Patil (100%) Preetam NW et al (100%) and Mishra SK et al¹²(97.7%).⁸⁻¹⁰ Headache was second most important symptom in our study (80%). In contrary SS Dash et al,

Preetam NW et al, VC Patil, Mishra SK et al, VB Singh et al observed 37.5%, 6.25%, 14.89%, 30.8%, 15.32% respectively.⁸⁻¹² Vomiting was seen in 75.5%, very much similar to SS Dash et al (72.5%), Mishra SK et al (54.6%), VC Patil (19.14%) and Preetam NW et al (12.5%).^{8,12,9,10}

In our study, diminished levels of consciousness in the form of drowsy, stupor & comatose were present in 56.4% cases, GCS score ≤ 7 is seen in 13.6% cases having equal proportions in males and females (Figure 2). SS Dash et al, Preetam NW et al, VC Patil and VB Singh et al noticed 27.5%, 17.5%, 8.5% and 18.01% respectively.⁸⁻¹¹ Convulsions were noted in 31% cases in our study. Bajiya et al, SS Dash et al, Preetam NW et al, VB Singh et al, VC Patil and Mishra SK noticed convulsion in 21.62%, 17.5%, 1.25%, 4.55%, 8.5% and 17.1% respectively (Table 2).⁸⁻¹³

The incidence of cerebral malaria in our study was 14.2% as per WHO definition. All these patients were unconscious at the time of admission, level of coma as assessed by GCS scale was less than 7. There were totally 38(34.5%) cases who were clinically diagnosed as cerebral malaria. SS Dash study had 32.5%.⁸ Incidence of cerebral malaria in a study conducted by VB Singh et al was 9.57%, study from New Guinea had 17% presented with cerebral malaria.^{11,14} This difference may be attributed to selection of cases. Our study consists of confirmed falciparum malaria cases only, whereas VB Singh et al study consists of falciparum, vivax and mixed falciparum and vivax malaria cases.¹¹

Our study observed convulsion in cerebral malaria in 34 (31%) cases. In Kochar et al study, they observed convulsion in 21.31% patients.² The incidence of convulsion in adults with cerebral malaria varies in early 1980 studies conducted in Thailand and Vietnam, 50% of adults with cerebral malaria had generalized seizure¹⁵ whereas in these countries in the 1990 the incidence was less than 10%. The reason for this difference is not clear. Possible explanation includes differences in parasite virulence characteristic or possibly the decrease in the use of chloroquine. Status epilepticus are unusual in adult, although more than one seizure is common.¹⁵ In our study all the cases had generalised convulsions but status epilepticus was not observed. Kochar et al² reported that convulsions are usually generalized but persistent focal seizure and status epilepticus are also observed.

On neurological examination, we found 26 (23.63%) cases with abnormal behavior in the form of depression, confusion, paranoid and manic syndrome and delirium (Figure 3). VB Singh et al¹¹ found psychosis in 20 (12%) cases of falciparum malaria. Kocher et al² observed psychosis (5.21%) in form of confusion, delirium, hallucination, depression, paranoid and manic syndrome. Varney et al (1977) also reported psychosis in Vietnam veteran showed depression, personality changes and irritability, virulence and partial seizure like syndrome.¹⁶

Cranial neuropathies were noticed in 12 cases (10.9%). Oculomotor nerve palsy was seen in 4 cases. Bilateral abducent nerve palsy seen in 4 cases. Glossopharyngeal and Vagus nerve abnormality in the form of impaired GAG reflex was seen in 4 cases. 2 cases had UMN type of Trigeminal nerve palsy with exaggerated jaw jerk. All

of these cases were a part of cerebral malarial encephalopathy. 1 female patient had unilateral diminution of vision attributed for retrobulbar neuritis. Similar finding was reported by PC Manyike et al.¹⁷ Occasional involvement of cranial nerves mostly bilateral 6th cranial nerve, was observed by White NJ et al.¹⁸

Conjugated deviation of eyes was seen in 3 (2.7%) cases. Kochar et al observed conjugated deviation of eyes in (2.26%) patients.² VB Singh et al observed in 1(0.90%) case, similar results were observed in study by Bajiya et al.^{11,13} Roving eye movements are usually an indication of light coma and are a poor localizing sign.¹⁹ This sign was positive in 23 (20.9%) cases in our study.

Out of 34 cases with hypertonia, 5 (4.5%) cases had extrapyramidal rigidity. Kochar et al also observed extra pyramidal rigidity (2.25%).² VB Singh et al observed similar result with extra pyramidal rigidity in 2 (1.80%) patients.¹¹ 3 (2.7%) cases had decorticate rigidity. Bajiya et al observed decorticate rigidity in 1.13%.¹³ Similar study by VB Singh et al observed decorticate rigidity in 1(0.90%) case.¹¹

We found cerebellar dysfunction in 12.7% at the time of admission to the hospital. Bajiya et al¹³ observed cerebellar dysfunction in 3.24% patients, Kochar et al in 4.72%.² Similar observation was also seen in (2.70%) VB Singh et al study.¹¹

Neck rigidity was observed in 25 (22.7%) cases in our study. Kochar DK et al noticed neck rigidity in 19% cases and VB Singh et al reported in 5 (4.5%) cases.^{2,11} Nguyen et al proposed that neck rigidity is not a feature but mild stiffness of neck is not uncommon, and hyperextension of the neck may occur severely in adults but there is no photophobia.²⁰ In cerebral malaria, meningeal irritation can occur with headache, vomiting, neck stiffness and positive kerning sign.²¹ Bajiya et al observed neck rigidity in (19%) of cerebral malaria. Preetam NW et al and Sarvepalli AK reported signs of meningeal irritation in 1.25% & 11.5% respectively.^{13,10,22} The difference in percentages is attributed to the selection of cases, as our study selected falciparum malaria mono-infection cases only.

We found diffuse subarachnoid haemorrhage and intracerebral haemorrhage in 1 case. MP(QBC) for falciparum malaria was positive and PfHRP-2 based assay was strongly positive. CT scan brain revealed diffuse subarachnoid haemorrhage and intracerebral haemorrhage with intraventricular extension. Fibrin degradation product was positive. The patient had a stormy clinical course and ultimately died 2 days later in spite of aggressive treatment with intravenous artesunate and supporting ventilator measures. We also noticed 1 more case having intracerebral haemorrhage with intraventricular extension; patient succumbed within 24 hours of admission in the intensive care unit. VB Singh et al found 1 case, Mathur et al reported a case of

subarachnoid haemorrhage due to disseminated intravascular coagulation (DIC).^{11,23} K Murugawel et al, DK Sharaswal, C Gall et al also reported similar results.²⁴⁻²⁶ A number of coagulation related molecular and cellular events underlie microvascular changes and are apparent even in patients with less severe disease. Given the importance of coagulation factors as regulators of inflammation these events are likely to play an important role in pathogenesis.²⁷

We found a case of cerebral venous thrombosis in a 22 year-old female presenting with fever and seizures. She was diagnosed as and treated for severe falciparum malaria. After gaining consciousness she developed focal neurological signs and evidence of increased intracranial pressure. Magnetic resonance imaging (MRI) of the brain and MR Venography brain revealed a superior sagittal sinus, right transverse and sigmoid sinus thrombosis with haemorrhages in left parieto-occipital brain parenchyma with edema around. Investigations for other infections and thrombophilia were negative. The clinical status

improved gradually. Cerebral venous sinus thrombosis has been reported to be associated with various systemic illnesses and infections, including severe malaria. Luvira V et al also reported a case of cerebral venous thrombosis in a Thai patient.²⁸ Krishnan et al reported a similar case.²⁹ A hypercoagulable state resulting from severe malaria may be responsible for this rare and fatal complication. Cerebral venous thrombosis may worsen malaria and adversely affect outcome.²⁹

Malaria retinopathy: Fundoscopy was done in all 110 patients. A Fundoscopy change in retina was noticed in 49 patients. 4 different patterns of retinal changes were noticed. Retinal whitening (19.1%), Retinal haemorrhage (20%), Papilloedema (17.3%) and Vessel whitening (4.5%). A Study by Kochar DK et al showed retinal haemorrhages in 9.43% and papilloedema in 7.94% in 1998.³⁰ Another study by Looareesuwan S et al showed haemorrhage in 14.5% in 1983.³¹ Kochar et al observed papilloedema in 5.5% cases.²

Table 3: Comparison between present study and various other studies in terms of neuropsychiatric manifestations at the time of discharge.

Neuropsychiatric manifestations at discharge	Present study (%)	Bajiya HN et al (%)	SS Dash et al (%)
FND*	3.6	1.62	2.5
Psychosis	6.3	4	5
Depression	5.5	--	12.5
Speech disorder	3.6	1.6	5
Memory loss	4.5	--	5
Cerebellar signs	7.3	3.2	2.5
Peripheral N.**	8.2	--	--
Total	32.7	10.5	32

* Focal Neurological Deficit, **Peripheral Neuropathy

At the time of discharge, Focal neurological deficit (FND) was seen in 3.6% in the form of hemiparesis in 1 case and quadriplegia in 3 cases. Bajiya et al also observed FND in 1.62% and SS Dash et al in 2.5%.^{13,8} Psychosis after treatment, at the time of discharge was seen in 7 cases (6.3%) in our study. SS Dash et al observed in 5% and Bajiya et al in 4% cases.^{8,13} Depression was seen in 5.5% of our cases, whereas 12.5% was observed in SS Dash et al study.⁸ We found speech abnormality in 3.6%. Bajiya et al observed it in 1.6% cases and SS Dash et al noted in 5% cases.^{13,8} Memory loss was observed in 4.5% cases in our study, similar results (5%) was noted in SS Dash et al study.⁸ Cerebellar signs were noted among 7.3% of cases in our study. Bajiya et al reported 2.5% and SS Dash et al observed in 3.2% cases at the time of discharge (Table 3).^{13,8}

Peripheral neuropathy of axonal type was noted in 8.2% cases. Reason being unclear, role of nutritional deficiency or primary pathology involving nerve fibers is postulated for the pathogenesis of neuropathy.

Total 46 cranial CTs and 28 MRI of Brain were done. 39 cranial CTs were normal. In the rest haemorrhage, infarction and cerebral edema were seen in 2 cranial CTs each. 1 cranial CT showed cerebral edema with lacunar infarction. 18 MRI of brain were normal. Rest of the 10 MRI of brain showed ischemic changes. In addition to ischemic changes on MRI brain, 6 MRIs showed infarction, 2 MRIs showed cerebral edema, 1 case of cerebral venous thrombosis and 1 case of diffuse cerebral edema with infarction.

EEG findings were noted in 5 (4.5%) cases. A variety of non-specific EEG abnormalities have been described in both uncomplicated and cerebral malaria.³² Background activity consisting of theta and delta waves and continuous multifocal ictal discharges suggestive of generalized seizure disorder were seen in our cases.

CSF analysis was helpful in differentiating non-malarial coma from the malarial coma. CSF analysis was done in 12 cases. 8 cases had non-specific reports. 4 cases had low CSF/Serum ADA ratio, decreased CSF glucose levels and a normal cell count which is described as best

discriminators of cerebral malaria from presumed viral encephalitis and bacterial meningitis.^{33,34} Nerve conduction study was done in cases having generalised weakness for more than 4 days. Peripheral nerve involvement not amounting for Acute Inflammatory Demyelinating Polyneuropathy was noted in 8.2% cases.

Predominantly axonal type involving upper and lower limbs was noted in complicated falciparum malaria cases only. The possibilities include parasitic emboli obstructing the vasa nervosum, liberation of neurotoxin from the parasite and / or metabolic or nutritional disturbances.³⁵

Table 4: Correlation of neuropsychiatric manifestations present at discharge with degree of parasitemia.

Neuropsychiatric manifestations at discharge	Degree of parasitemia on quantitative buffy coat examination					
	+ / ++			+++ / ++++		
	Male	Female	Total	Male	Female	Total
FND*	2	1	3	0	1	1
Psychosis	2	2	4	2	1	3
Depression	1	3	4	2	0	2
Speech disorder	2	1	3	0	1	1
Memory loss	2	2	4	1	0	1
Cerebellar signs	2	5	7	1	0	1
Peripheral n.**	2	4	6	2	1	3

*Focal Neurological Deficit, **Peripheral Neuropathy

After regaining consciousness, most common neurological manifestation noticed was peripheral neuropathy, followed by cerebellar dysfunction. Psychosis and depression were also seen. Focal neurological deficits like hemiplegia and speech abnormality like aphasia were also seen. Atypical presentations like subarachnoid haemorrhage, cerebral venous thrombosis, cerebral infarction, retrobulbar neuritis were noticed in our study.

CONCLUSION

The neurological complications of falciparum malaria are common and encompass a wide spectrum of clinical presentation in complicated as well as uncomplicated malaria. Atypical presentations noted in literatures are not so infrequently seen in endemic areas like Western Odisha. Both central and peripheral nervous system is likely to be affected.

Fundoscopy examination of retina has importance in diagnosis of the patients. Algorithms to diagnose cerebral malaria in a parasitemic comatose patient need to be adapted for better management in endemic areas, where asymptomatic parasitemia is more common.

Knowledge about the possible atypical manifestations and their self-limiting course prevents invasive and unnecessary investigations. There by reducing the social as well as economic burden on patients.

ACKNOWLEDGEMENTS

Authors would like to thank all the Faculty members and PG students of Department of Medicine VIMSAR, Burla for their support while conducting the study.

Funding: No funding sources

Conflict of interest: None declared

Ethical approval: The study was approved by the institutional ethics committee

REFERENCES

1. National Vector Borne Disease Control Programme, Directorate General of Health Services, Ministry of Health and Family Welfare, Malaria Situation in India (State-wise) from 2010-2017. <http://nvbdcp.gov.in/malaria3.html>. [Accessed 17Nov 2017].
2. Kochar DK, Kumawat BL, Kochar SK, Halwai M, Makkar RK, et al. Cerebral malaria in Indian adults. *J Assoc Physicians India*. 2002;50:234-41.
3. Idro R, Kakooza-Mwesige A, Balyejussa S, Mirembe G, Mugasha C, Tugumisirize J, et al. Severe neurological sequelae and behaviour problems after cerebral malaria in Ugandan children. *BMC research notes*. 2010;3(1):104.
4. Senanayake N, deSilva HJ. Delayed cerebellar ataxia complicating falciparum malaria: a clinical study of 74 cases. *J Neurol*. 1994;241:456-45.
5. Leopoldino JF, Fukujima M, Gabbai AA. Malaria and stroke: case report. *Arquivos de neuro-psiquiatria*. 1999;57(4):1024-6.
6. Tin-Oo P. Gender, mosquitoes and malaria: implications for community development programmes in Laputta, Myanmar. *Southeast Asian Journal of Tropical Medicine and Public Health*, Sept 2001;32(3):588-94.
7. Brabin L, Brabin BJ. HIV, malaria and beyond: reducing the disease burden of female adolescents. *Malaria Journal*. 2005;4(1):2.
8. Dash SS, Mohapatra MK. Neuro-psychiatric manifestations in patients of falciparum

- malaria.(Degree of Medicine dissertation, Sambalpur University); 2006
9. Patil VC. Complicated falciparum Malaria in western Maharashtra Trop Parasitol. 2012 Jan-Jun; 2(1): 49-54
 10. Wasnik PN, Manohar TP, Humaney NR, Salkar HR. Study of clinical profile of falciparum malaria in a tertiary referral centre in Central India. *J Assoc Physicians India.* 2012;60:33-6.
 11. Singh VB, Kumar H, Meena BL, Chandra S. Neuropsychiatric Profile in Malaria: An Overview. *Journal of clinical and diagnostic research: JCDR.* 2016;10(7):OC24.
 12. Mishra SK, Mohanty S, Satpathy SK, Mohapatra DN. Cerebral malaria in adults-a description of 526 cases admitted to Ispat General Hospital in Rourkela, India. *Ann Trop Med Parasitol.* 2007;101:187-93.
 13. Bajiia HN, Kochar DK. Incidence of outcome of neurological sequel in survivors of cerebral malaria. *J Assoc Physicians India.* 1996;44(10):679-81.
 14. Laloo DG, Trevett AJ, Paul M, Korinhona A. Severe and complicated falciparum malaria in Melanesian adult in Papua New Guinea. *American J Trop Med Hyg.* 1996;55:119-24.
 15. White NJ, Loaresuwan S, Philips RE. Single dose phenobarbitone prevents convulsion in cerebral malaria. *Lancet.* 1988;11:64-66.
 16. Varney NR, Roberts RJ, Springor JA, Connel SK. Neuropsychiatric sequel of cerebral malaria in Vietnam. *J Nerv Ment Dis.* 1997;185(11):695-705.
 17. Manyike PC, Okike C, Onyire NB, Chinawa JM, and Austin-Abu JU. Cerebral Malaria Complicated by Blindness, Deafness and Extrapyramidal Tract Manifestation. *Ann Med Health Sci Res.* 2015;5(4): 321-2.
 18. White NJ, Loaresuwan S. Cerebral malaria in Kennedy PGE, Johnson RI, Eds of nervous system. London: Butter Worths; 1987;118-43.
 19. MC Walker, MD O'Brien Neurological examination of the unconscious patients. *J R Soc Med.* 1999;92:353-5.
 20. Nguyen Thi HM, Nicholas PJ, Day Ly, Van Choung. Post malarial neurological syndrome. *Lancet.* 1996;348:917-21.
 21. Russell PF, West LS, Manwell RD, Macdonald G. Practical malariology. *Practical Malariology.* (Ed 2); 1963
 22. Sarvepalli AK, Dharana PK. Clinical profile, laboratory profile of malaria cases attending a tertiary care hospital in South India: two-year study. *Int J Adv Med.* 2017;4:540-5.
 23. Mathur SL, Hakim A, Ladha R. Subarachnoid haemorrhage in falciparum malaria. An unreported presentation. *J Assoc Physicians India.* 1992;40:348.
 24. Murugavel K, Saravanapavanathan S, Anpalahan A. Subarachnoid haemorrhage in Plasmodium falciparum malaria *Postgrad Med J.* 1989;65:236-7.
 25. Sharaswal DK. A case of cerebral malaria presenting as subarachnoid haemorrhage. *J Assoc Physicians India.* 1994;42:756.
 26. Gall C, Spuler A, Fraunberger P. Subarachnoid hemorrhage in a patient with cerebral malaria. *N Engl J Med.* 341;1999:611-3.
 27. Moxon CA, Heyderman RS, Wassmer SC. Dysregulation of coagulation in cerebral malaria. *Molecular and biochemical parasitol.* 2009;166(2):99-108.
 28. Luvira V, Chamnanchanunt S, Thanachartwet V, Phumratanapapin W, Viriyavejakul A. Cerebral venous sinus thrombosis in severe malaria. *Southeast Asian J Trop Med Public Health.* 2009;40(5):893-7.
 29. Krishnan A, Karnad DR, Limaye U, Siddharth W. Cerebral venous and dural sinus thrombosis in severe falciparum malaria. *J Infect.* 2004;48:86-90.
 30. Kochar DK, Kumawat BL. Ophthalmoscopic abnormalities in adults with falciparum malaria. *QJ Med.* 1998;91(12):845-52.
 31. Looareesuwan S, Warrell DA, White NJ, Chanthavanich P. Retinal hemorrhage, a common sign of prognostic significance in cerebral malaria. *Am J Trop Med Hyg.* 1983;32(5):911-5.
 32. Thumasupapong S, Tin T, Sukontason K, Sawaddichi C. electroencephalography in cerebral malaria. *Southeast asian J Trop Med public health* 1995;26(1):34-7.
 33. Jakka SR, Veena S, Atmakuri RM, Eisenhut M. Characteristic abnormalities in cerebrospinal fluid biochemistry in children with cerebral malaria compared to viral encephalitis. *Cerebrospinal Fluid Res.* 2006;3:8
 34. Berkley JA, Mwangi I, Mellington F, Mwarumba S, Marsh K. Cerebral malaria versus bacterial meningitis in children with impaired consciousness. *Qjm.* 1999;92(3):151-7.
 35. Drago SD, Sa ND, Golapalli U. Guillian Barre Syndrome in a case of falciparum malaria. *J Assoc Physicians India.* 1997;45:161.

Cite this article as: Murmu M, Kar A, Mahesh KKP, Naik M, Meher RK. Study of neurological manifestations in patients of falciparum malaria. *Int J Adv Med* 2018;5:107-14.