

## Case Report

# A case of pheochromocytoma presenting as syncope due to long QT syndrome

Mohammad Hayat Bhat<sup>1</sup>, Henna Naqash<sup>2\*</sup>, Parvaiz Ahmad Zargar<sup>3</sup>,  
Sajad Ahmad Sumji<sup>4</sup>, Parvaiz Ahmad Shah<sup>4</sup>

<sup>1</sup>Department of Endocrinology, <sup>2</sup>Department of Medicine, <sup>3</sup>Department of Cardiology, Government Medical College, Srinagar, Jammu and Kashmir, India

<sup>4</sup>Department of Medicine, Government Medical College, Srinagar, Jammu and Kashmir, India

**Received:** 06 January 2018

**Accepted:** 03 February 2018

### \*Correspondence:

Dr. Henna Naqash

E-mail: [hennanaqash@yahoo.in](mailto:hennanaqash@yahoo.in)

**Copyright:** © the author(s), publisher and licensee Medip Academy. This is an open-access article distributed under the terms of the Creative Commons Attribution Non-Commercial License, which permits unrestricted non-commercial use, distribution, and reproduction in any medium, provided the original work is properly cited.

## ABSTRACT

Pheochromocytoma, a catecholamine secreting tumour, is rare and we are presenting such a case who presented with syncopal episodes due to arrhythmias associated with the tumour. The patient was managed with pharmacologic and surgical treatment.

**Keywords:** Arrhythmia, Catecholamines, Syncope, Tumour

## INTRODUCTION

Catecholamine-secreting tumors that arise from chromaffin cells of adrenal medulla and those of sympathetic ganglia are referred to as pheochromocytomas and paragangliomas, respectively.<sup>1</sup> These tumours are treated with similar approaches as their clinical presentation is same and many clinicians use the term pheochromocytoma to refer to both adrenal pheochromocytomas and extra-adrenal catecholamine-secreting paragangliomas. Such tumors are rare, with an annual incidence of 2 to 8 cases per 1 million people.<sup>2</sup> Typical clinical presentation includes the triad of headache, palpitations and diaphoresis.

The main presenting symptoms include hypertension, headache, pallor, palpitations, epigastric and chest pain, anxiety and fear of impending death, diaphoresis, dyspnea, nausea and vomiting. Tremors are caused by the pharmacologic effects of excess of circulating catecholamines.<sup>3</sup> The hypertension associated with

pheochromocytoma may be sustained or paroxysmal, and patients diagnosed with the tumour in the presymptomatic stage may have normal blood pressure. The lability of blood pressure can be due to the episodic release of catecholamines, chronic volume depletion, and impaired sympathetic reflexes. In addition, altered sympathetic vascular regulation may have a role in orthostasis, that is frequently observed in these patients.<sup>4</sup> Symptoms of orthostatic hypotension in the form of lightheadedness, presyncope or syncope may dominate the presentation, especially in patients with epinephrine- or dopamine-predominant tumors.<sup>5,6</sup>

In pheochromocytoma, sinus tachycardia is the most prevalent cardiac rhythm abnormality, but it can induce more serious arrhythmias or conduction disturbances, like prolongation of the QTc interval and ventricular tachycardia followed by cardiac arrest.<sup>7</sup> Long QT syndrome is defined as the prolongation of the QT interval corrected for heart rate, to >440 ms in men or >460 ms in women.

QT prolongation is described in 16 to 35% of patients.<sup>8,9</sup> Repolarization abnormalities associated with hyperadrenergic states can cause QT prolongation and lethal arrhythmia, including Torsades de pointes.<sup>10</sup> The reported cardiac complications of this tumour include hypertrophic cardiomyopathy, dilated cardiomyopathy, arrhythmias, myocardial ischemia, and SCD.<sup>11,12</sup> About 50-70% of all pheochromocytoma patients complain about palpitations, but only few develop ventricular tachycardia, and only a very few of these cases are reported to be due to QT interval prolongation and Torsades de Pointes.<sup>13-16</sup> Stenström and Swedberg have described a significant decrease in QTc interval in their retrospective study of patients after surgical removal of pheochromocytoma.<sup>17</sup>

**CASE REPORT**

We report a case of 45-year-old female who was referred from peripheral health centre to our hospital with history of multiple syncopal episodes. The patient had started with sudden onset vomiting, non bilious type, projectile, containing yellowish fluid and ingested food particles. The vomiting settled without any medication. But after half an hour while patient was sitting calmly in a room she had an episode loss of consciousness which was sudden in onset, remained for about 90 seconds and lead the patient to fall down on the floor.

The episode was associated with incontinence of urine and jerky movements of upper limbs. The patient regained consciousness fully and the recovery was prompt and spontaneous without any intervention. The patient was unaware of the episode and the episode was followed by palpitations. She was taken to nearby hospital where she had another episode of loss of consciousness which remained for about 2 to 3 minutes and she was found to be pulseless with no cardiac activity and totally unresponsive to any stimuli. CPR was done there and once again patient regained consciousness fully.

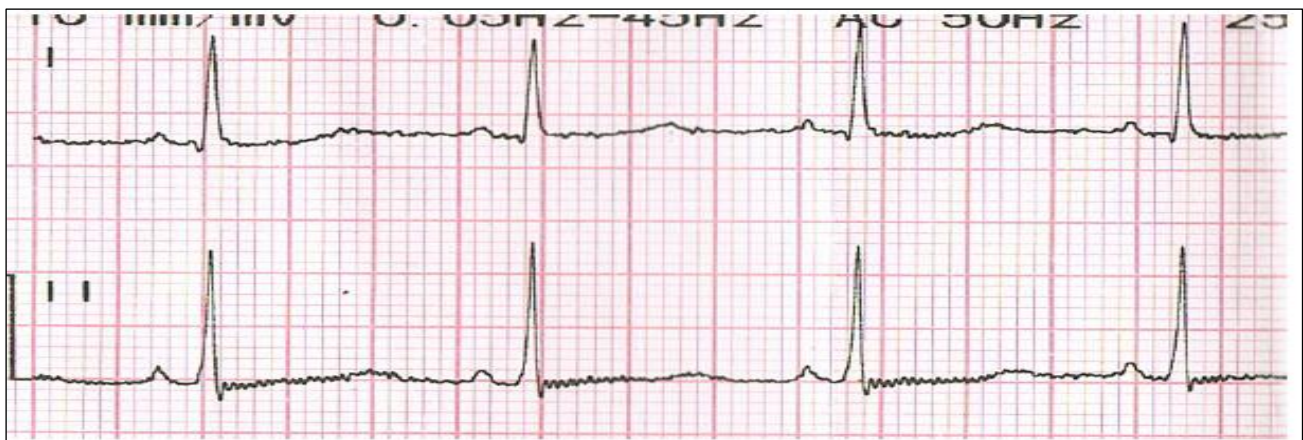ECG was done which was reported as normal. With this history patient was referred to our hospital for further management with an impression of unexplained cardiac arrest. There was no previous history suggestive of coronary artery disease, seizure, diabetes mellitus, stroke or substance abuse.

In the past history she was hypertensive for the last 3 years on treatment but historically, her blood pressure (BP) was poorly controlled. BP recorded by a private practitioner about 2 weeks back was 210/100 mmHg. She had hypertensive retinopathy grade 3 in the right eye and grade 4 in the left eye with papilledema. She gave history of episodic palpitations, dizziness and blackouts for last 2 years. She was taking Losartan 50 mg, Chlorthalidone 12.5 mg and Amlodipine 5 mg daily besides calcium supplements.

On examination there was nothing significant other than hypertension with, BP supine 170/100 mmHg in both arms, BP standing 145/90 mmHg. Pulse was 82/min regular, synchronous to other pulses, good volume. In hospital, she again had one episode of loss of consciousness associated with abnormal jerky movements of body and remained unresponsive for about 2 minutes followed by drowsiness for about 15 minutes. We made a provisional diagnosis of resistant secondary hypertension with convulsive syncope likely due to cardiac or neurologic cause. We did NCCT (non contrast computed tomography) brain and EEG (electroencephalography) to rule out any neurological cause, however both the investigations were normal.

**Table 1: BP recording of the patient in Hospital.**

BP	10 AM	02 PM	06 PM	10 PM
Day 1	130/80	150/100	190/100	120/80
Day 2	150/100	120/80	200/106	140/80
Day 3	170/100	120/90	130/100	160/80



**Figure 1: ECG tracings of patient.**

USG abdomen was revealing left suprarenal hypoechoic area measuring 5.5x3.5 cm suggestive of adrenal mass (? Pheochromocytoma). Echocardiography showed mild concentric LVH, Grade 1 LV diastolic dysfunction. Normal left ventricular systolic functions, no regional wall motion abnormality and ejection fraction 68%. 24-hour Holter ECG showed sinus rhythm throughout with occasional ectopics, there was no evidence of any significant dysrhythmia during the period of study.

#### Biochemical tests

- Serum K<sup>+</sup>: 2.6
- Serum Ca: 8.9
- Aldosterone serum: 571.79pg/ml (normal 25.00-315.00)
- Plasma renin activity: 27.74 ng/ml/hr upright (normal 1.9-6.0) supine (normal 0.5-1.9)
- Ratio of PA/PRA: 20.61
- VMA 24-hour urine: 4.24 mg/g creatinine (normal 1.60-4.20)
- Overnight dexamethasone suppression test: Cortisol Serum 0.66ug/dl (normal 4.30-22.40)
- CECT Abdomen: Homogenous enhancing mass measuring 5.5x3.8cm is seen in relation to upper pole of left kidney. Right kidney showed small cyst.

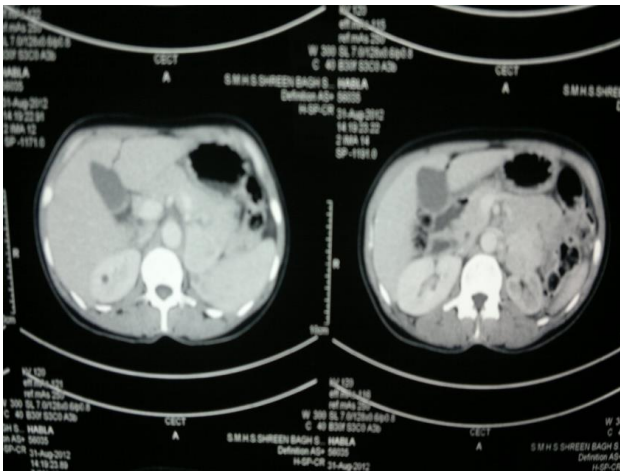


Figure 2. CECT abdomen.

In view of the history, clinical features, radiology and biochemical parameters a final diagnosis of pheochromocytoma presenting as long qt syndrome and syncope was made. Patient was managed conservatively, till surgery was planned.

Hypokalemia corrected by KCl infusion followed by oral potassium. She also received oral calcium and magnesium. She was subjected to laparoscopic adrenalectomy. Preoperatively she received Prazosin 2.5mg TID, then Atenolol 25 mg od was added followed by Amlodipine 5mg and Losartan 25mg. Before commencing surgery, patient was prepared well with alpha and beta-adrenergic blockade.

Pre-Operative vitals: heart rate 76/min, BP (intraarterial) 120/80 mmHg. Intra-Arterial B.P Monitoring was done through right radial artery cannulation. Elective laparoscopic 4 port left adrenalectomy was done. A big mass approximately 6x6 cms spherical in shape arising from left suprarenal gland superomedially was removed. Mass was heterogenous, hypervascular completely fixed to surrounding structures. During intraoperative period, the patient developed hypertensive spikes which fluctuated upto 190 mm hg of systolic pressure, these episodes were managed with intravenous sodium nitroprusside. Post-operative vitals were Pulse 93/min, BP 110/70 mmHg, Sodium 143 mmol/L, Potassium 4.1 mmol/L, Sugar (random)123 mg/dl.

On discharge, patient was given Labetalol 100 mg bid. Histopathology report of excised mass revealed pheochromocytoma. On follow up in endocrine OPD, patient was doing well with a BP of 110/80 mmHg, no tachycardia and no postural drop. Antihypertensives were stopped and she was advised urinary VMA and check ultrasonography after 6 weeks.

#### DISCUSSION

Pheochromocytoma is a rare catecholamine producing tumor that has manifestations varying from no significant symptoms to sudden cardiac death.<sup>18</sup> This 45-year-old female patient was admitted with us as a case of recurrent episodes of syncope associated with abnormal body movements. On evaluating the patient, she was found to be having episodic hypertension and the ECG showed long QT interval. We evaluated further, with an intention to see whether patient may be having pheochromocytoma causing QT prolongation and syncope, which actually the case turned out to be. Pheochromocytoma patients can present with syncope and pre-syncope due to orthostatic hypotension, however, arrhythmias particularly QT prolongation with torsades de pointes could also be the cause of these symptoms. John Roshan et al from Christian Medical College, Vellore reported a case of a middle-aged lady with dilated cardiomyopathy, presenting with recurrent syncope due to torsades de pointes with underlying pheochromocytoma.<sup>19</sup> Due to increased catecholamines, sinoatrial node pacemaker activity becomes abnormal, and the arrhythmogenic role of catecholamines is shown by the suppression of pheochromocytoma arrhythmias with alpha and beta blockers.<sup>20,21</sup> We managed our patient with prazosin and phenoxybenzamine, besides correcting the hypokalemia and hypocalcemia. Patient was planned for laparoscopic adrenalectomy and was managed well preoperatively with both  $\alpha$  and  $\beta$  blockade. After surgery patient improved, her BP stabilised, syncope subsided with normalisation of the QT interval, during one week stay in the hospital in the post operative period. Similar observations were reported by Chakraborty P et al in a case study of a middle-aged lady presenting with recurrent pre-syncope due to polymorphic ventricular tachycardia who was basically harbouring a

pheochromocytoma. After they surgically removed the tumor of their patient, her symptoms subsided with normalization of the QT interval.<sup>22</sup> Kihara H et al have also reported a case of Pheochromocytoma of the left retroperitoneal paraganglion associated with torsade de pointe.<sup>13</sup> Pheochromocytoma may induce monomorphic VT and QT prolongation. The interaction of different catecholamines may have a compounding effect on cardiac repolarization.<sup>23</sup> Several cases in literature have reported the relation of QT interval prolongation with pheochromocytoma.<sup>24-26</sup>

Electrocardiographic abnormalities including rhythm, conduction and repolarization can occur in patients with pheochromocytoma.<sup>27,28</sup> They include marked prolongation of the Q-T interval and deep and wide symmetrically inverted T waves that are observed in 15% patients.<sup>29,30</sup> The mechanism of QT prolongation in these tumours is not fully clear; however alpha-adrenergic stimulation can prolong the QT interval by prolonging the action potential duration.<sup>31</sup> Polymorphic VT occurring in pheochromocytoma due to adrenergic excess is different as it is completely reversible following removal of the tumour. However, long QT interval may persist for as long as six years after surgery.<sup>32</sup>

Martin et al have detected a persistent increase in QTc-interval upon intravenous sotalol challenge despite a decrease in the extent of left ventricular hypertrophy 6 months after resection of the extra adrenal pheochromocytoma in their patient. They concluded that pharmacological tests for repolarization abnormalities might be useful tools to identify patients with pheochromocytoma at risk for ventricular arrhythmias.<sup>33</sup>

*Funding: No funding sources*

*Conflict of interest: None declared*

*Ethical approval: Not required*

## REFERENCES

- Lloyd RV, Tischer AS, Kimura N, et al. Adrenal tumors: introduction. In: DeLellis RA, Lloyd RV, Heitz PU, et al. eds. World Health Organization classification of tumours: pathology and genetics of tumours of endocrine organs. 4<sup>th</sup>ed. Lyon, France: IARC Press; 2004:136-8.
- Stenström G, Svårdsudd K. Pheochromocytoma in Sweden 1958-1981. *J Intern Med.* 1986;220(3):225-32.
- Young Jr WF. Pheochromocytoma: 1926-1993. *Trends Endocrinol Metab.* 1993;4(4):122-7.
- Munakata M, Aihara A, Imai Y, Noshiro T, Ito S, Yoshinaga K. Altered sympathetic and vagal modulations of the cardiovascular system in patients with pheochromocytoma: their relations to orthostatic hypotension. *Am J Hypertens.* 1999;12(6):572-80.
- Dubois LA, Gray DK. Dopamine-secreting pheochromocytomas: in search of a syndrome. *World J Surg.* 2005;29(7):909-13.
- Eisenhofer G, Goldstein DS, Sullivan P, Csako G, Brouwers FM, Lai EW et al. Biochemical and clinical manifestations of dopamine-producing paragangliomas: utility of plasma methoxytyramine. *J Clin Endocrinol.* 2005;90(4):2068-75.
- Leite LR, Macedo PG, Santos SN, Quaglia L, Mesas CE, De Paola A. Life-threatening cardiac manifestations of pheochromocytoma. *Case reports Medicine.* 2010;2010.
- Liao WB, Liu CF, Chiang CW, Kung CT, Lee CW. Cardiovascular manifestations of pheochromocytoma. *Am J Emerg Med.* 2000;18(5):622-5.
- Stenström G, Swedberg K. Qrs amplitudes, QTc intervals and ECG abnormalities in pheochromocytoma patients before, during and after treatment. *J Internal Med.* 1988;224(3):231-5.
- Madias C, Fitzgibbons TP, Alsheikh-Ali AA, Bouchard JL, Kalsmith B, Garlitski AC, et al. Acquired long QT syndrome from stress cardiomyopathy is associated with ventricular arrhythmias and torsades de pointes. *Heart Rhythm.* 2011;8(4):555-61.
- Eisenhofer G, Rivers G, Rosas AL, Quezado Z, Manger WM, Pacak K. Adverse drug reactions in patients with pheochromocytoma. *Drug Saf.* 2007 Nov;30(11):1031-62.
- Bybee KA, Prasad A. Stress-related cardiomyopathy syndromes. *Circulation.* 2008;118(4):397-409.
- Kihara H, Terai H, Kihara Y, Kihara T, Takahashi H, Kosuda A et al. Pheochromocytoma of the left retroperitoneal paraganglion associated with torsade de pointes: a case report. *Am J Cardiol.* 1997;30(1):37-44.
- Shimizu K, Miura Y, Meguro Y, et al: QT prolongation with torsade de pointes in pheochromocytoma. *Am Heart J.* 1992;124:235-9.
- Sani IM, Solomon DS, Imhogene OA, Ahmad AM, Bala GS: QT dispersion in adult hypertensives. *J Natl Med Assoc.* 2006;98:631-6.
- Roshan J, George OK, Vineet S, George PV, Jose VJ. Torsade de pointes in a case of pheochromocytoma: an unusual presentation of an uncommon disease. *Indian Heart J.* 2004;56:248-9.
- Stenström G, Swedberg K. QRS amplitudes, QTc intervals and ECG abnormalities in pheochromocytoma patients before, during and after treatment. *Acta Med Scand.* 1988;224:231-5.
- Gifford Jr RW, Bravo EL, Manger W. Diagnosis and management of pheochromocytoma. *Cardiology.* 1985;72:126-30.
- John Roshan, Oommen K George et al., Torsade de Pointes in a case of pheochromocytoma: an unusual presentation of an uncommon disease. *Indian Heart J.* 2004;56:248-9.
- Michaels RD, Hays JH, O'Brian JT, Shakir KM. Pheochromocytoma associated ventricular

- tachycardia blocked with atenolol. *J Endocrinol Invest.* 1990 Dec;13(11):943-7.
21. Dabrowska B, Pruszczyk P, Dabrowski A, Feltynowski T, Wocial B, Januszewicz W. Influence of alpha-adrenergic blockade on ventricular arrhythmias, QTc interval and heart rate variability in pheochromocytoma. *J Hum Hypertens.* 1995;9(11):925-9.
  22. Chakraborty P, Bhattacharjee HK, Anandaraja S. Palpitation, presyncope and abdominal mass. *Indian Heart Journal.* 2010;62(5):447-8
  23. Paulin FL, Klein GJ, Gula LJ, Skanes AC, Yee R, Krahn AD. QT prolongation and monomorphic VT caused by pheochromocytoma. *J Cardiovasc Electrophysiol.* 2009;20(8):931-4.
  24. Sacha J, Wester A, Hordynski G, Pluta W. QT interval prolongation during ECG evolution in takotsubo cardiomyopathy poses a threat of torsades de pointes to predisposed patients: case report of a female patient with congenital AV block. *Herz.* 2013;38:790-5.
  25. vander Heide K, de Haes A, Wietasch GJ, Wiesfeld AC, Hendriks HG. Torsades de pointes during laparoscopic adrenalectomy of a pheochromocytoma: a case report. *J Med Case Rep.* 2011;5:368.
  26. Chakraborty P, Bhattacharjee HK, Anandaraja S. Palpitation, presyncope and abdominal mass. *Indian Heart J.* 2010;62:447-8.
  27. Goldbaum TS, Henochowicz S, Mustafa M, Blunda M, Lindsay J., Jr Pheochromocytoma presenting with Prinzmetal's angina. *Am J Med.* 1986;81:921-2.
  28. Cheng TO, Bashour TT. Striking electrocardiographic changes associated with pheochromocytoma. Masquerading as ischemic heart disease. *Chest.* 1976;70:397-9.
  29. Schurmeyer TH, Engeroff B, Dralle H. Cardiologic effects of catecholamine-secreting tumours. *Eur J Clin Invest.* 1997;27:189-95.
  30. Liao WB, Liu CF, Chiang CW, Kung CT, Lee CW. Cardiovascular manifestations of pheochromocytoma. *Am J Emerg Med.* 2000;18(5):622-5.
  31. Viskin S, Fish R, Roth A, Schwartz PJ, Belhassen B. Clinical problem solving. QT or not QT. *N Engl J Med.* 2000;343:352-6.
  32. Stenstrom G, Swedberg K. QRS amplitudes, QTc intervals and ECG abnormalities in pheochromocytoma patients before, during and after treatment. *Acta Med Scand.* 1988;224:231-5.
  33. Methe H, Hinterseer M, Wilbert-Lampen U, Beckmann BM, Steinbeck G, Käab S. Torsades de Pointes: a rare complication of an extra-adrenal pheochromocytoma. *Hypertens Res.* 2007;30(12):1263.

**Cite this article as:** Bhat MH, Naqash H, Zargar PA, Sumki SA, Shah PA. A case of pheochromocytoma presenting as syncope due to long QT syndrome. *Int J Adv Med* 2018;5:464-8.